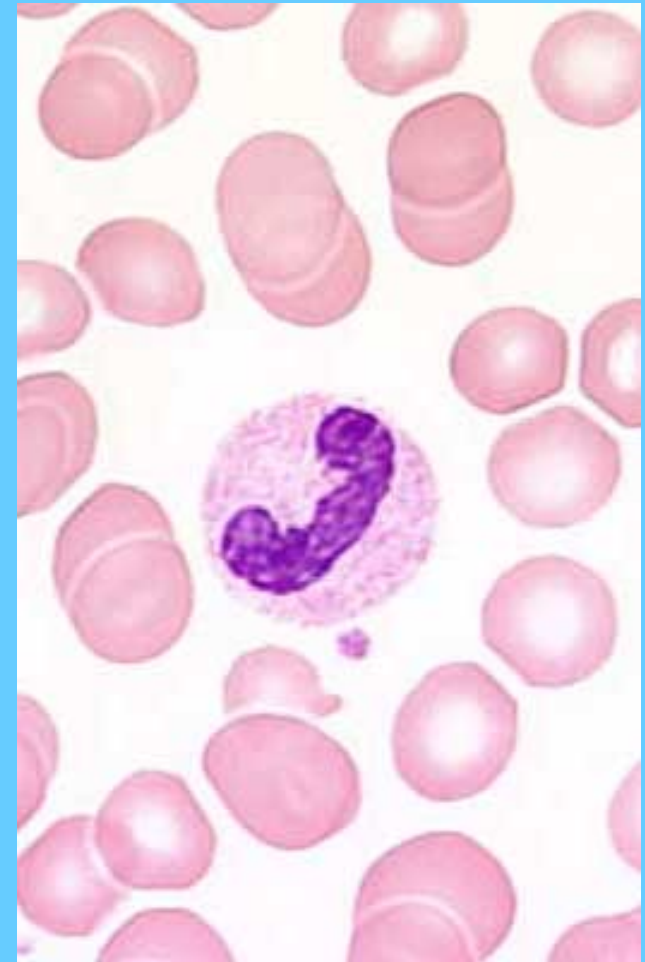
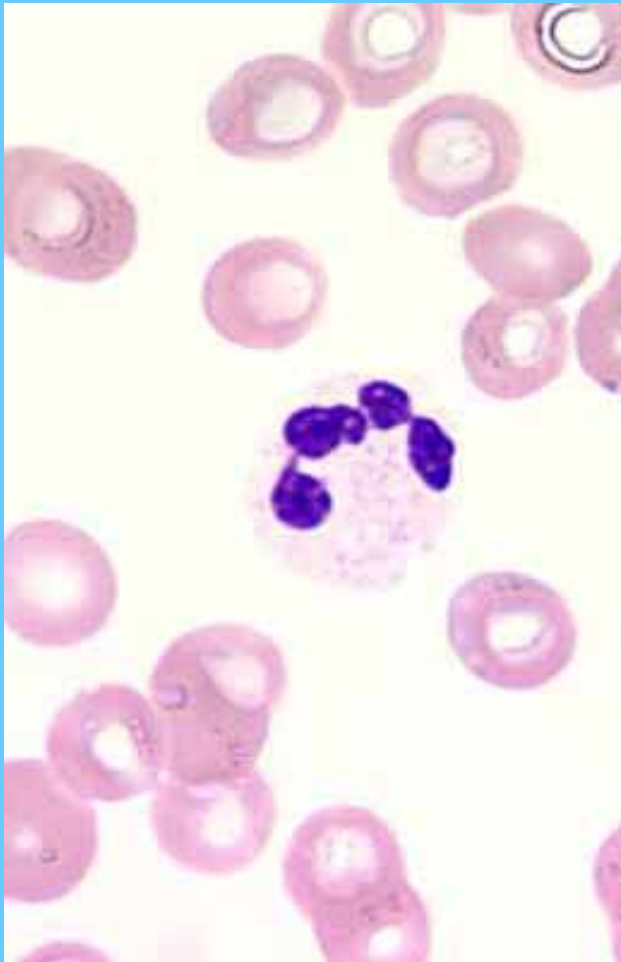
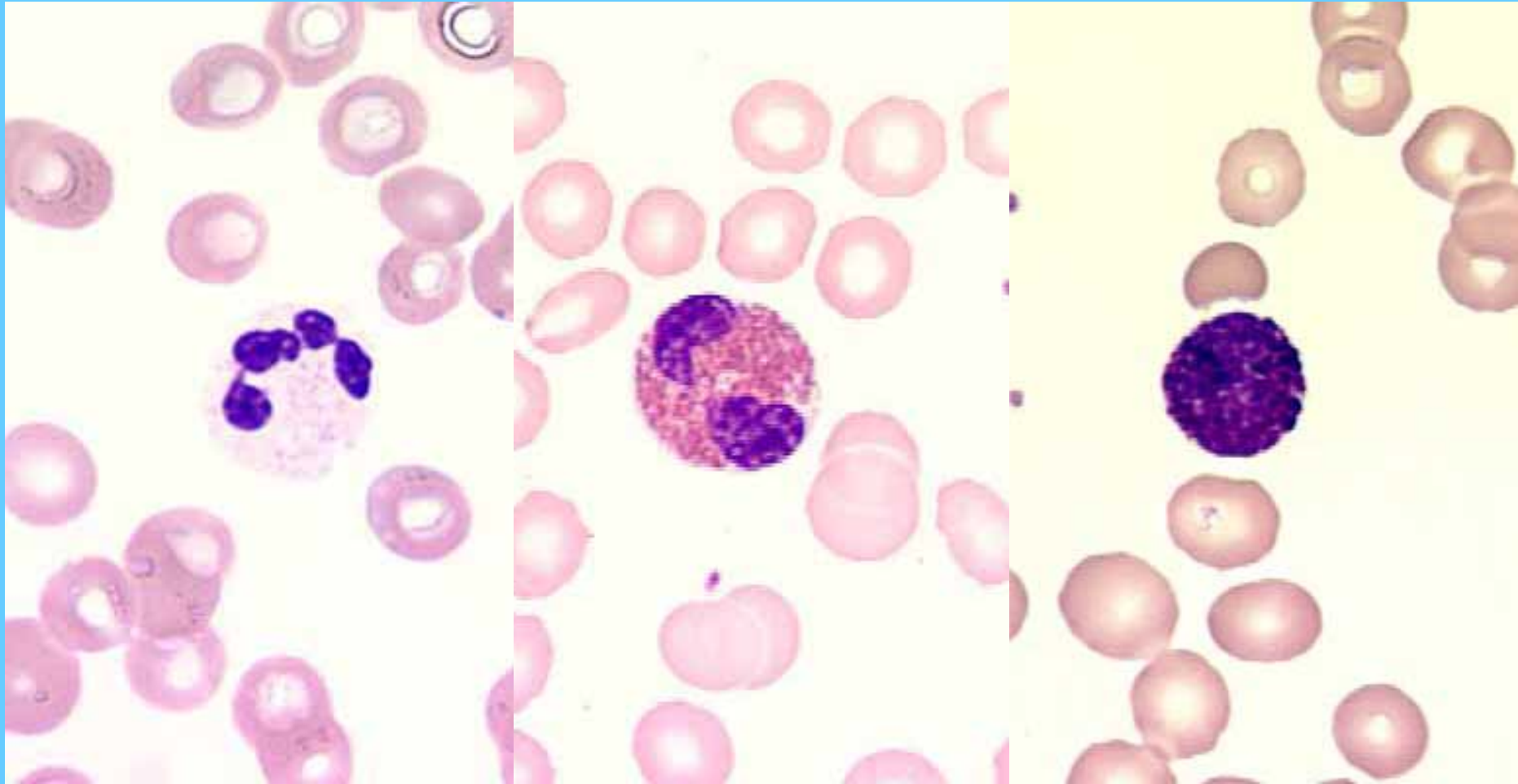


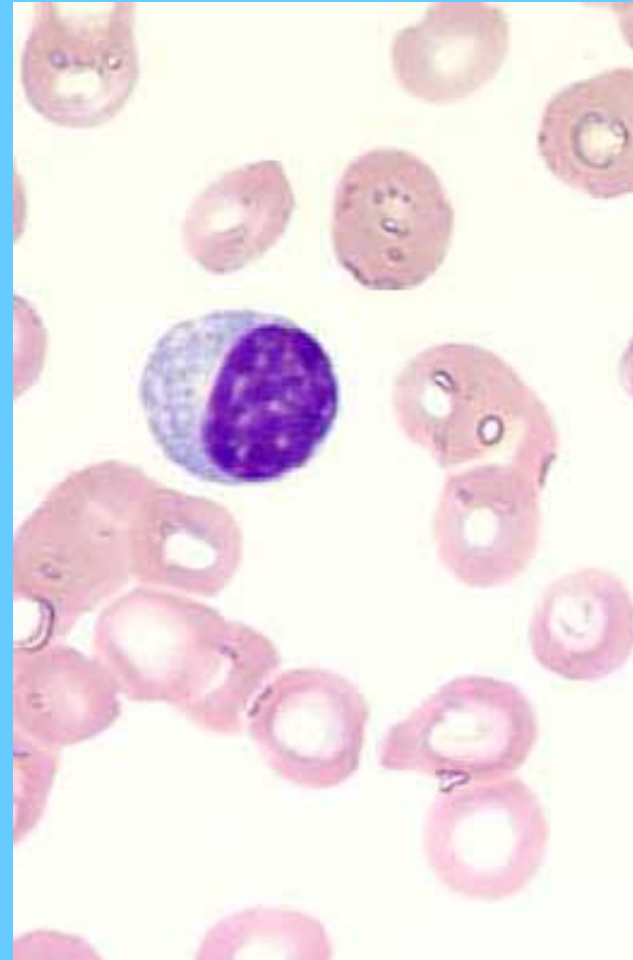
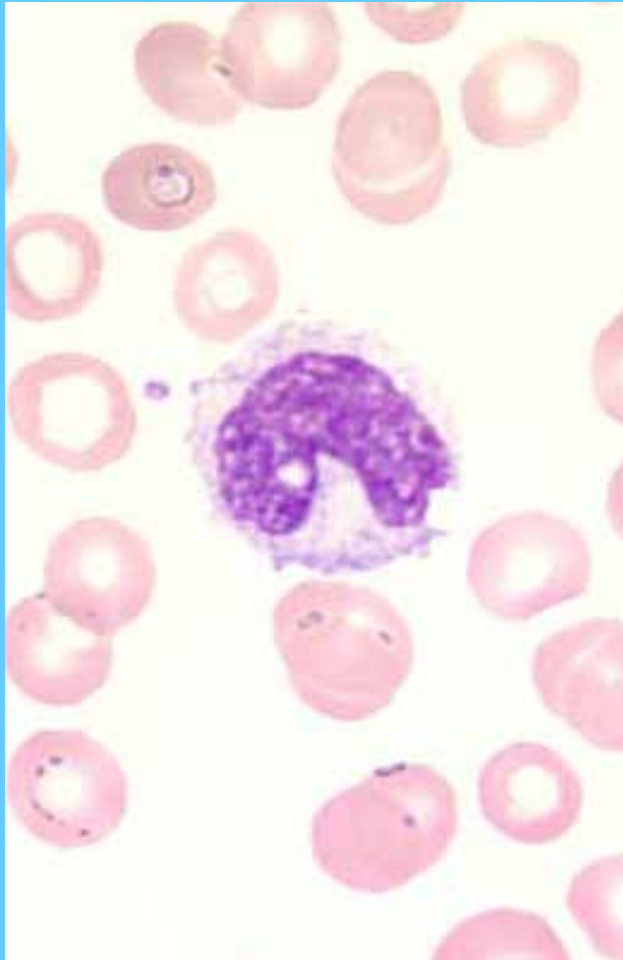
Neutrófilo segmentado (I) banda (D)



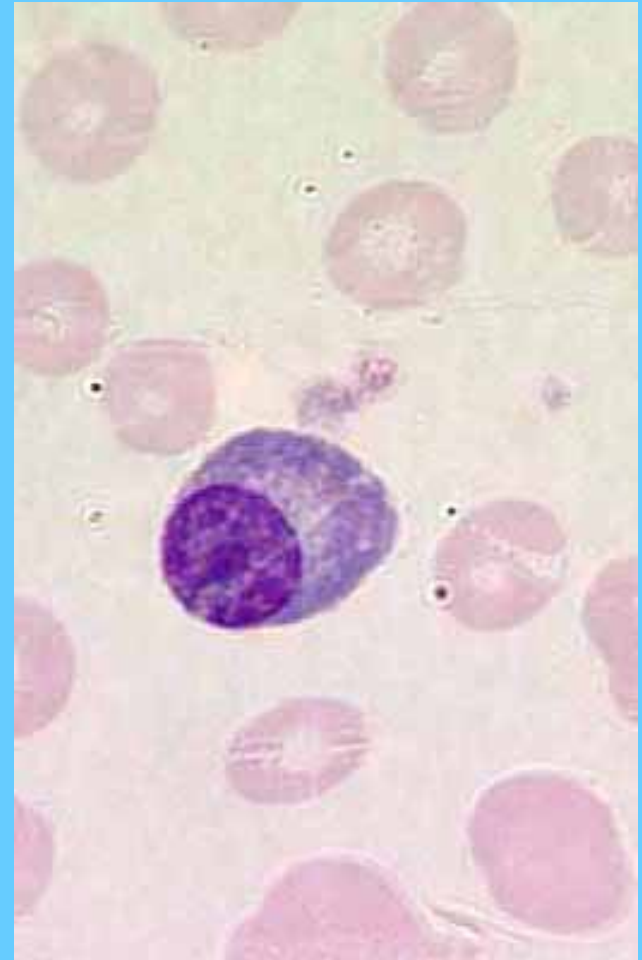
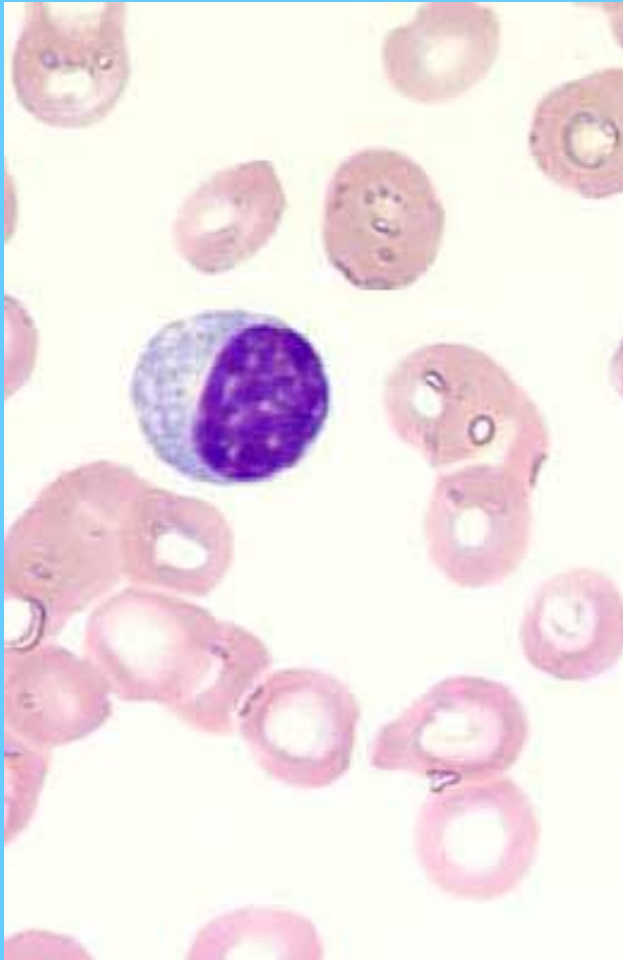
Meutrófilo segmentado (I), eosinófilo (C) y basófilo (D)



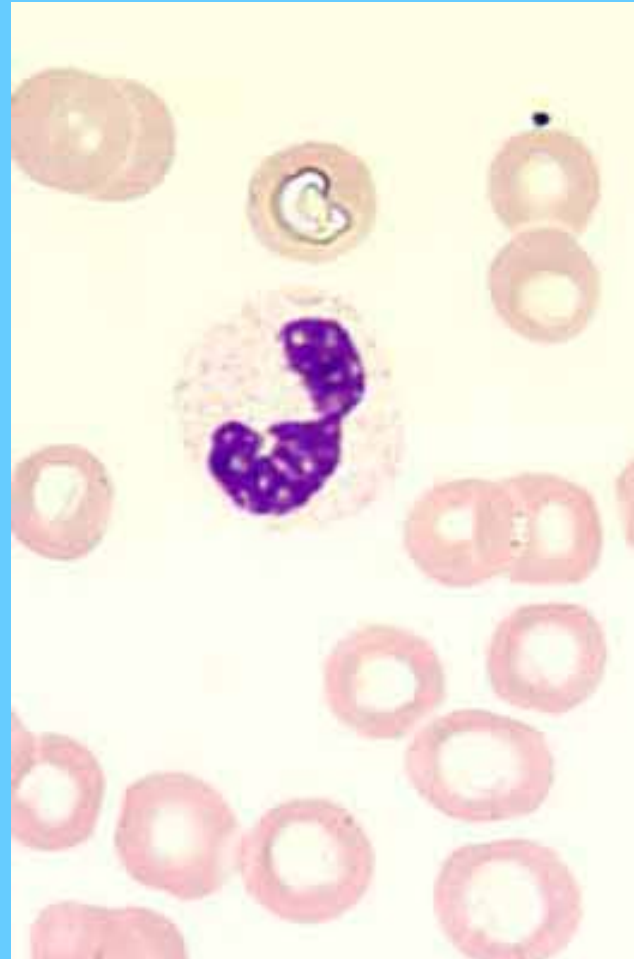
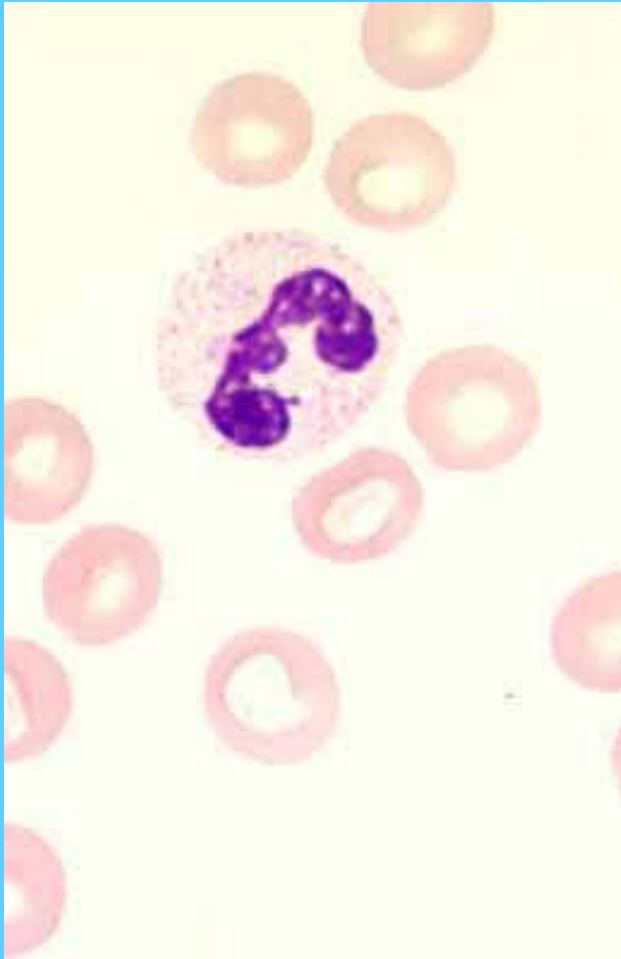
Monocito (I) linfocito (D)



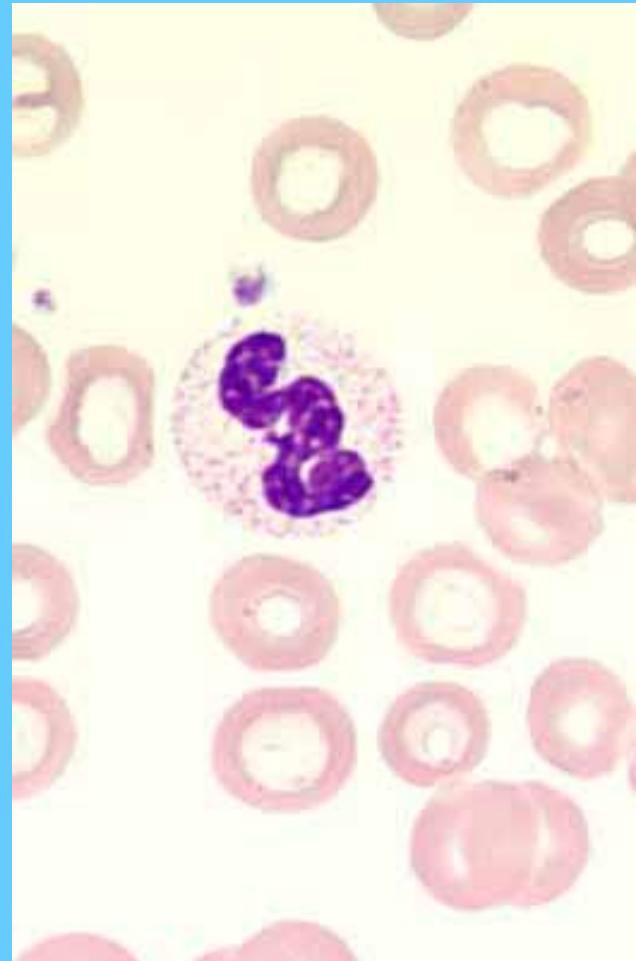
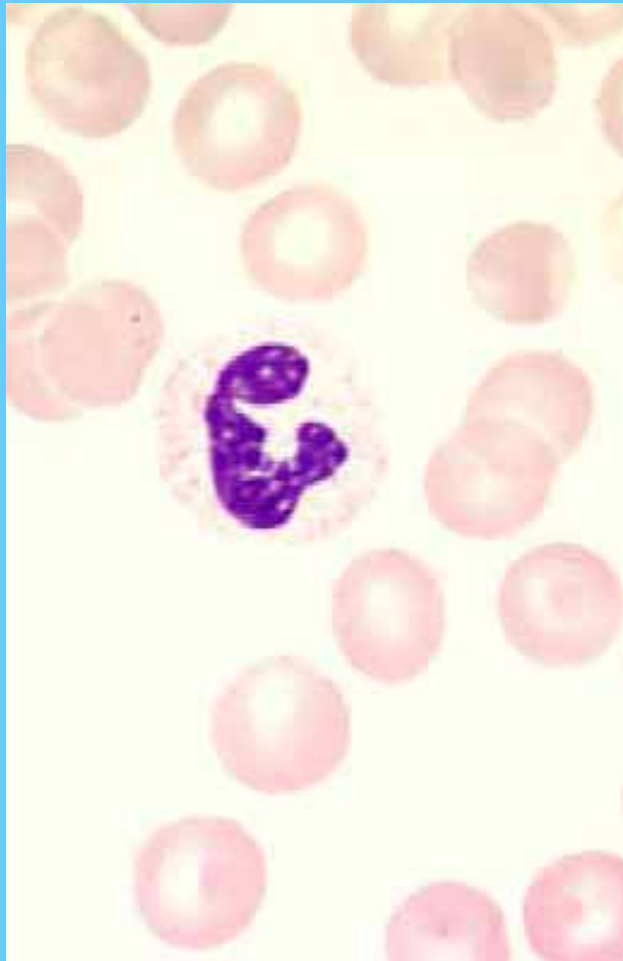Células plasmáticas



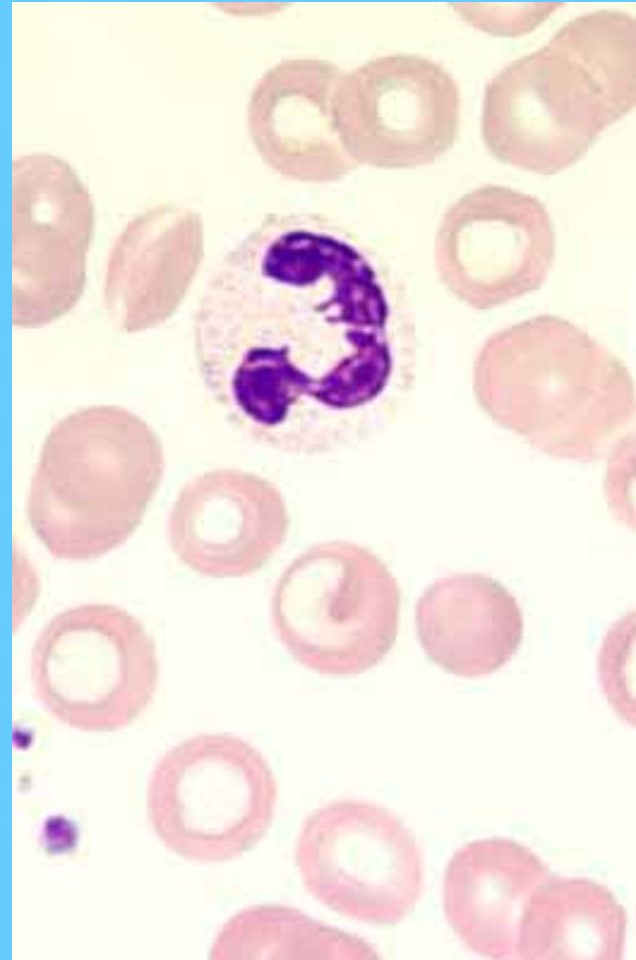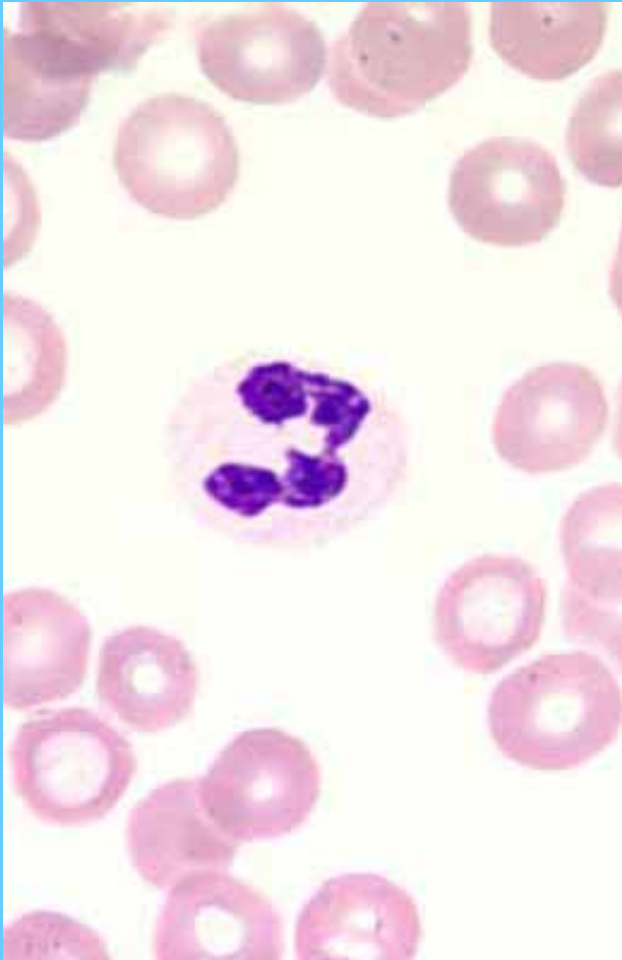Neutrófilos segmentados



Neutrófilo segmentado (I) banda (D)

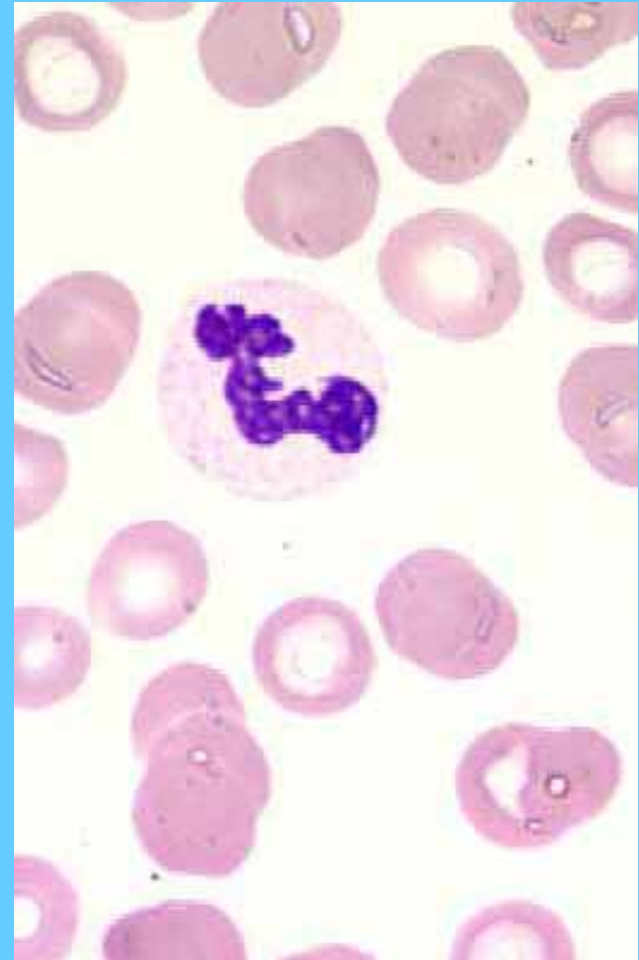
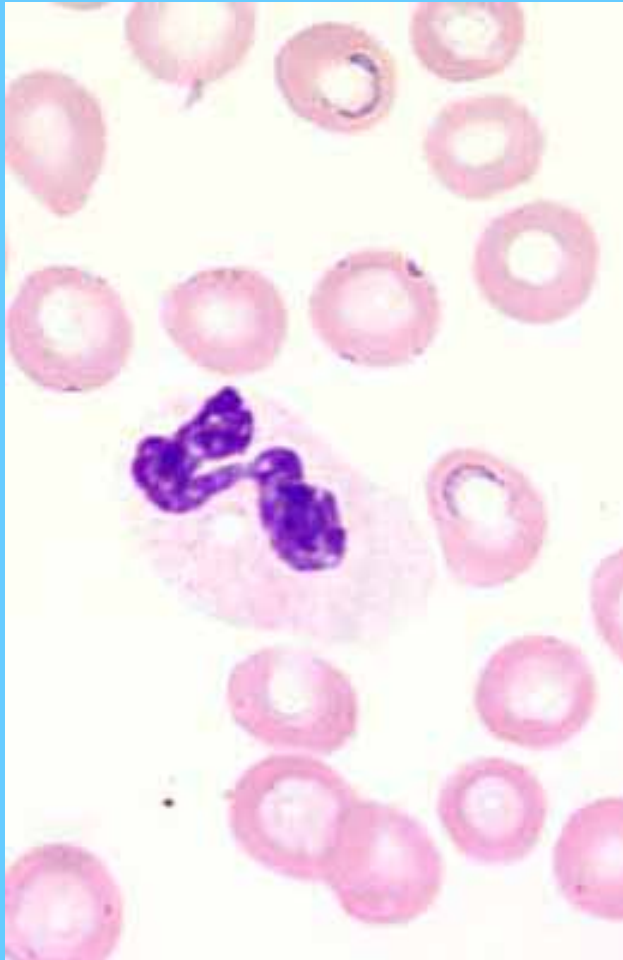


Neutrófilos segmentados

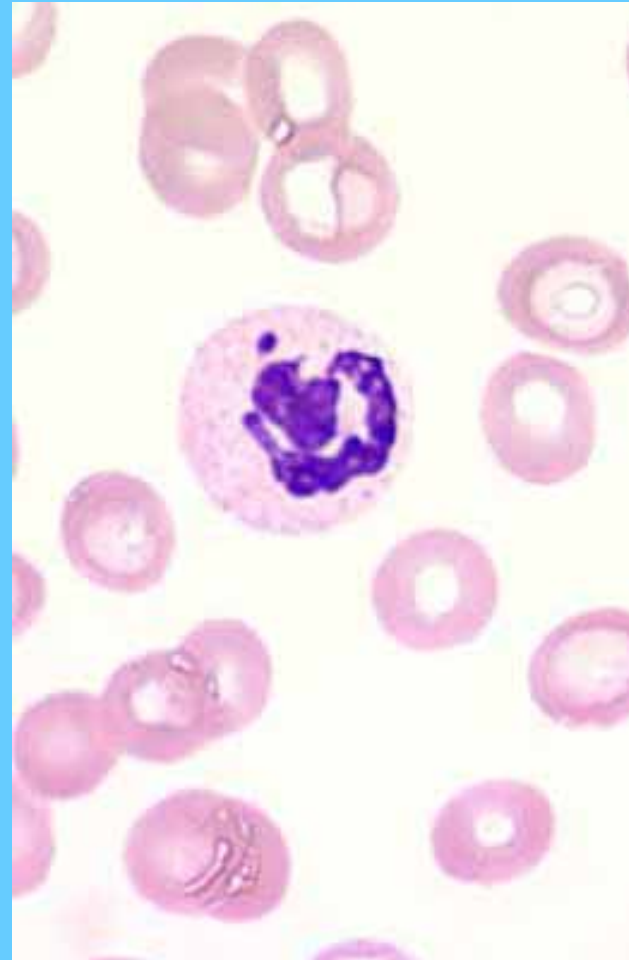
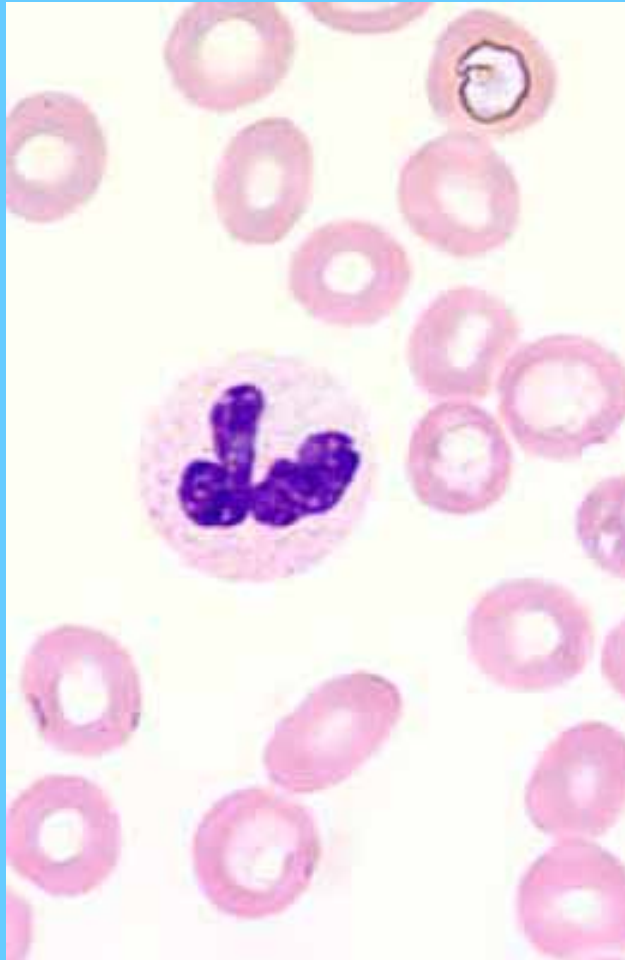

Neutrófilos segmentados (I)

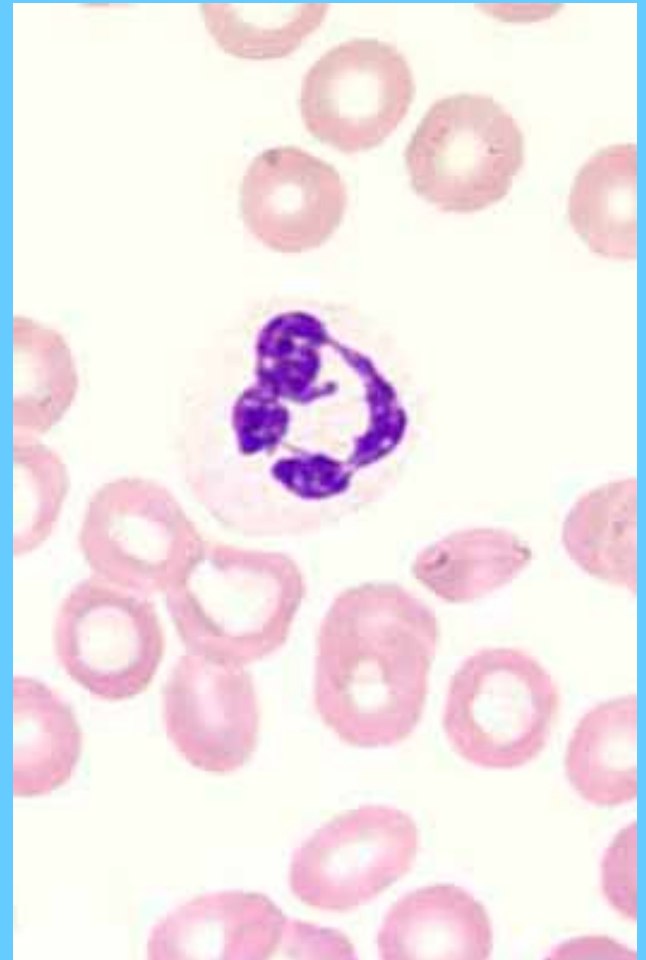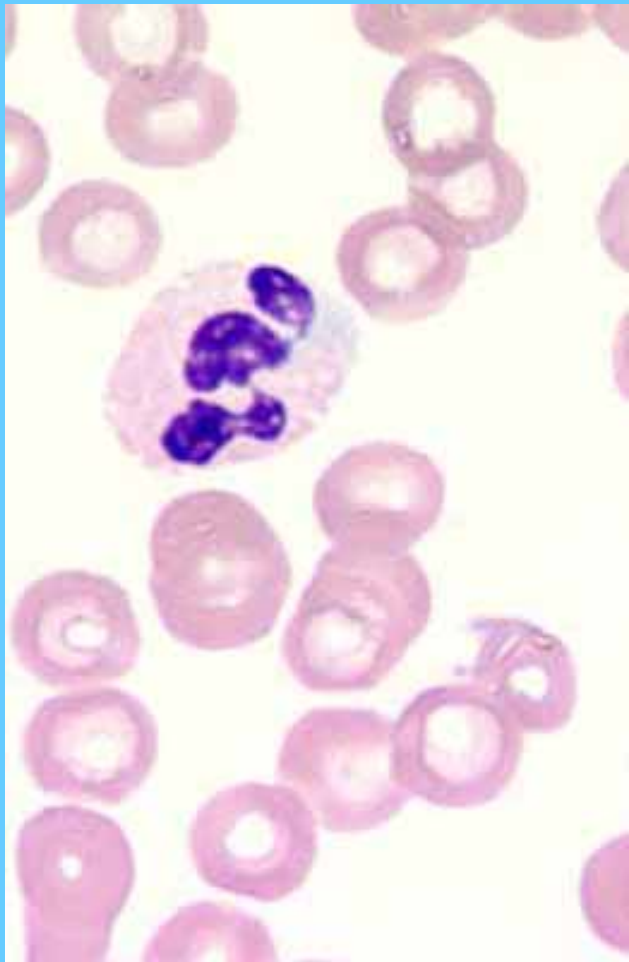
banda (D)



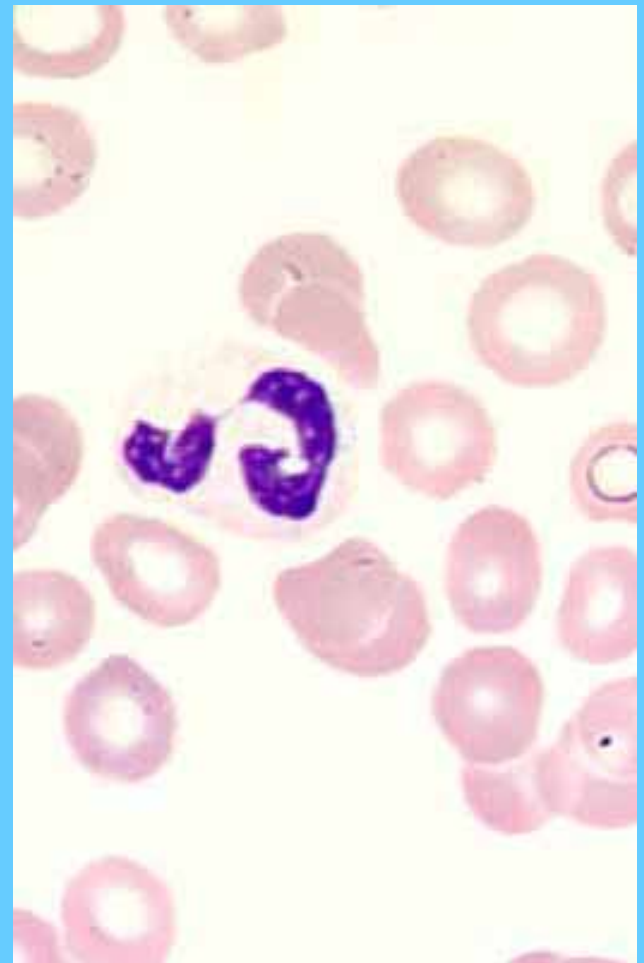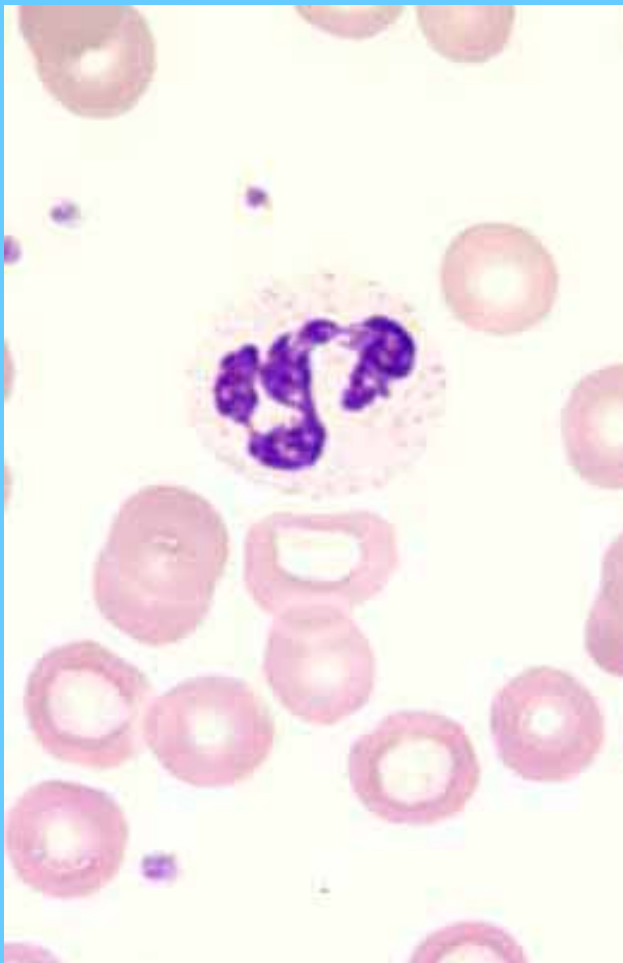
Banda (I) N. segmentado (D)



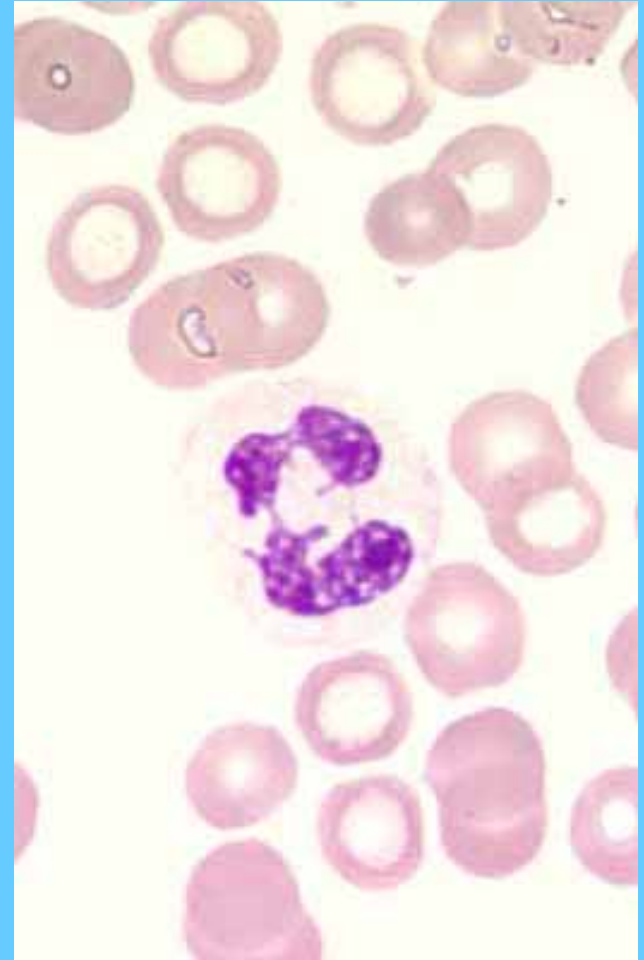
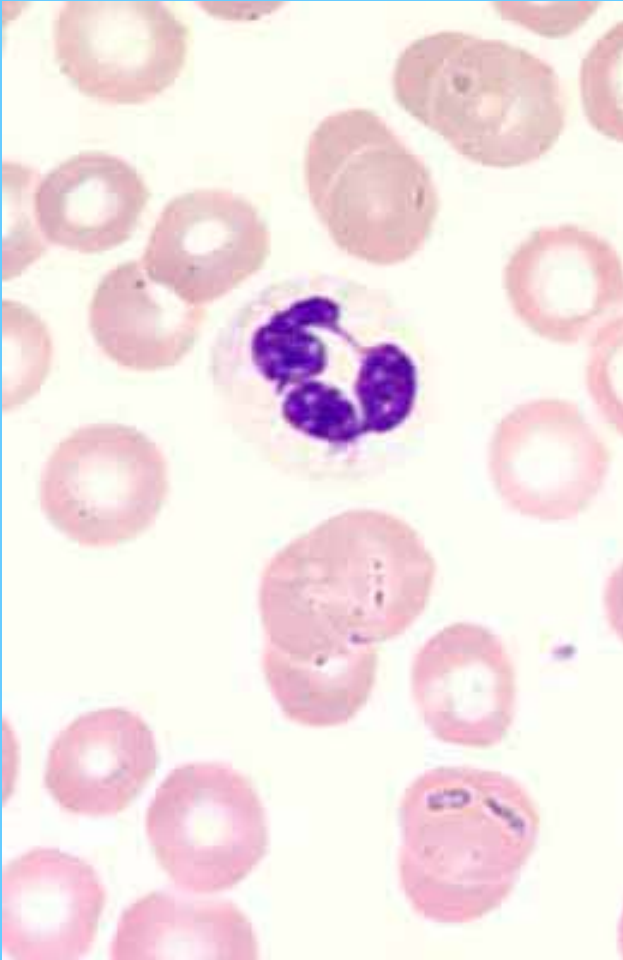
Neutrófilos segmentados



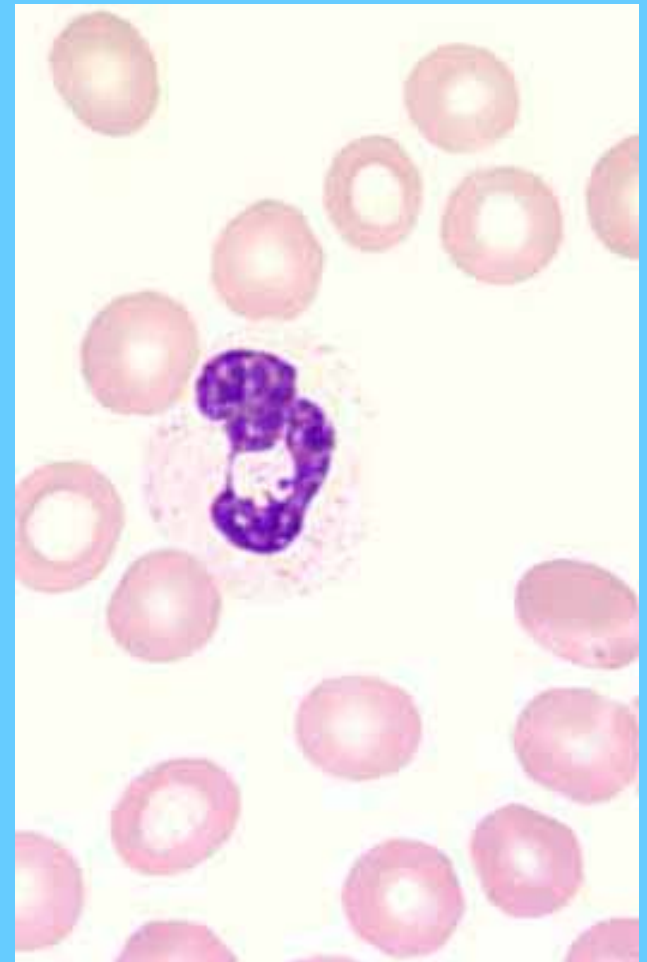
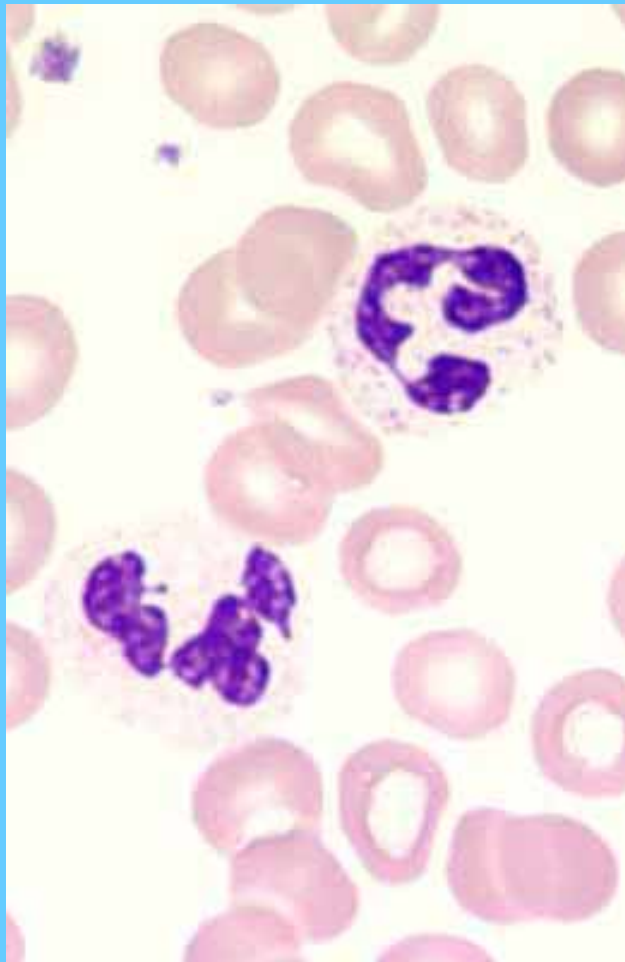
Neutrófilos segmentados



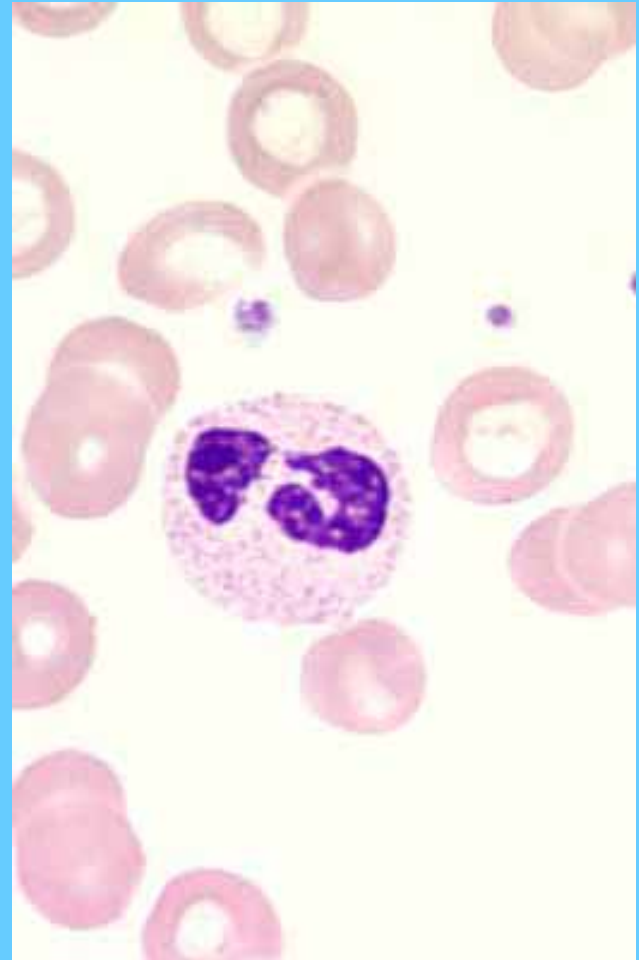
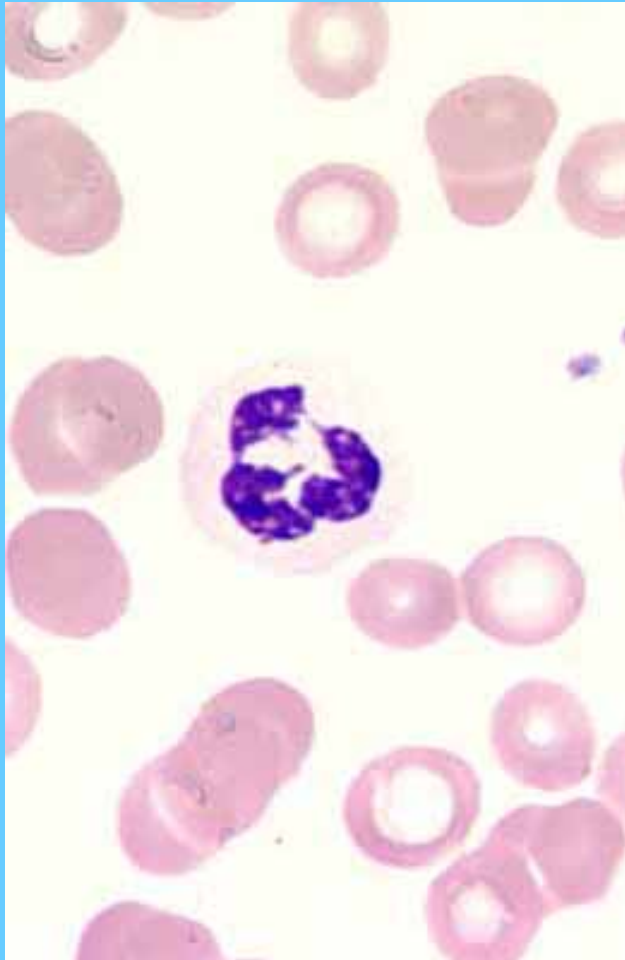
Neutrófilos segmentados



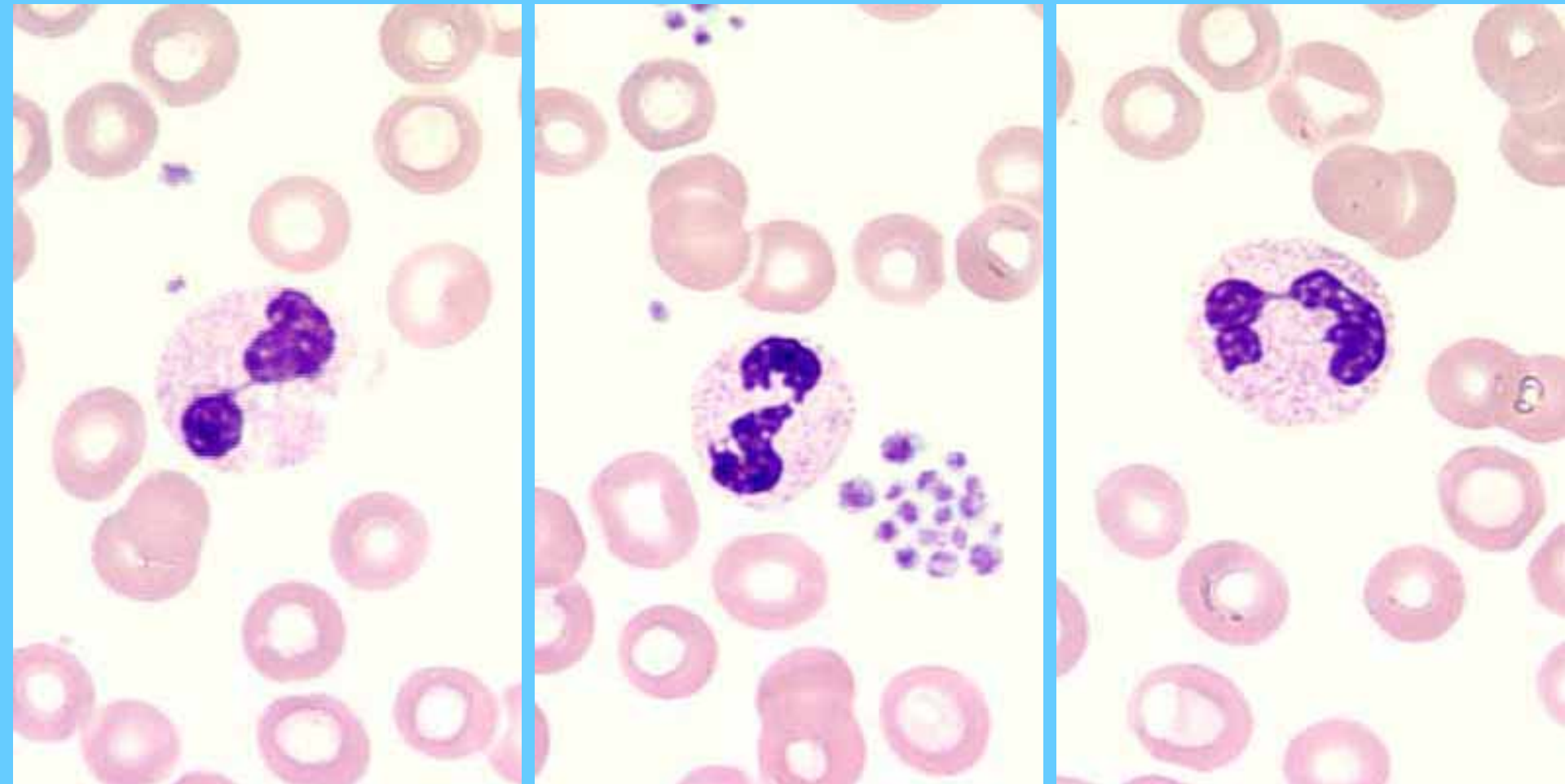
Neutrófilos segmentados



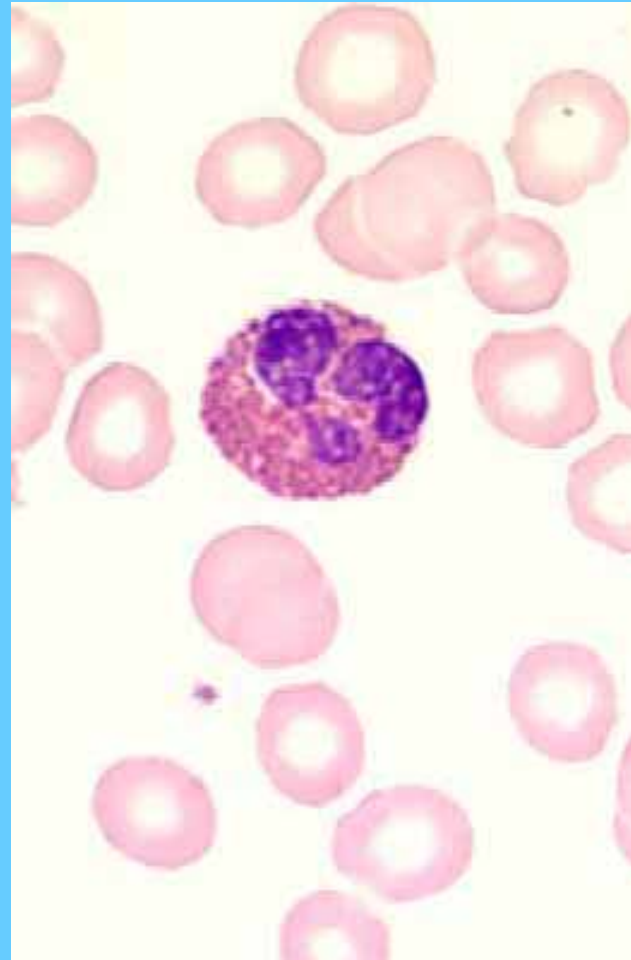
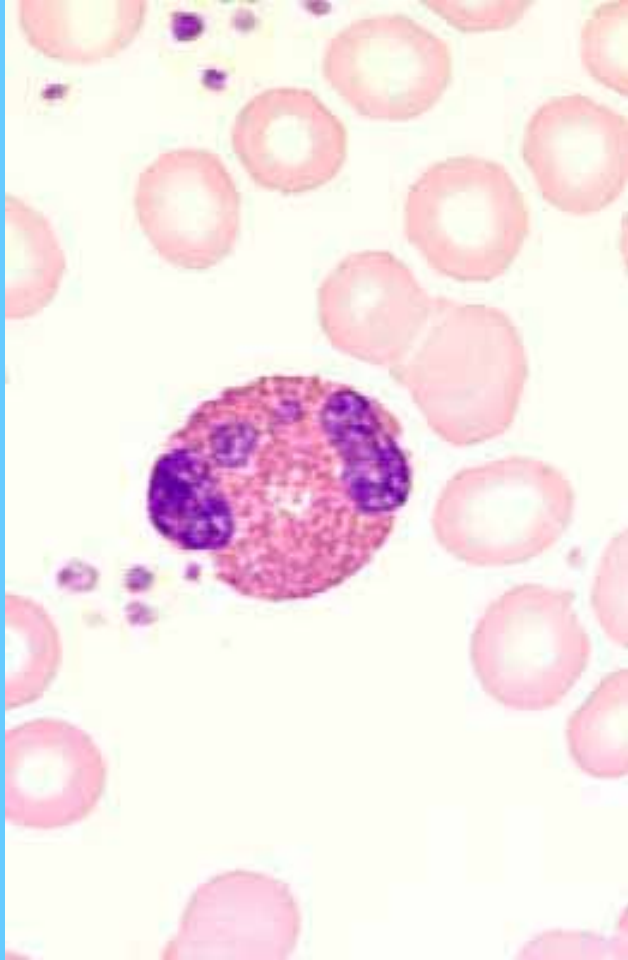
Neutrófilos segmentados



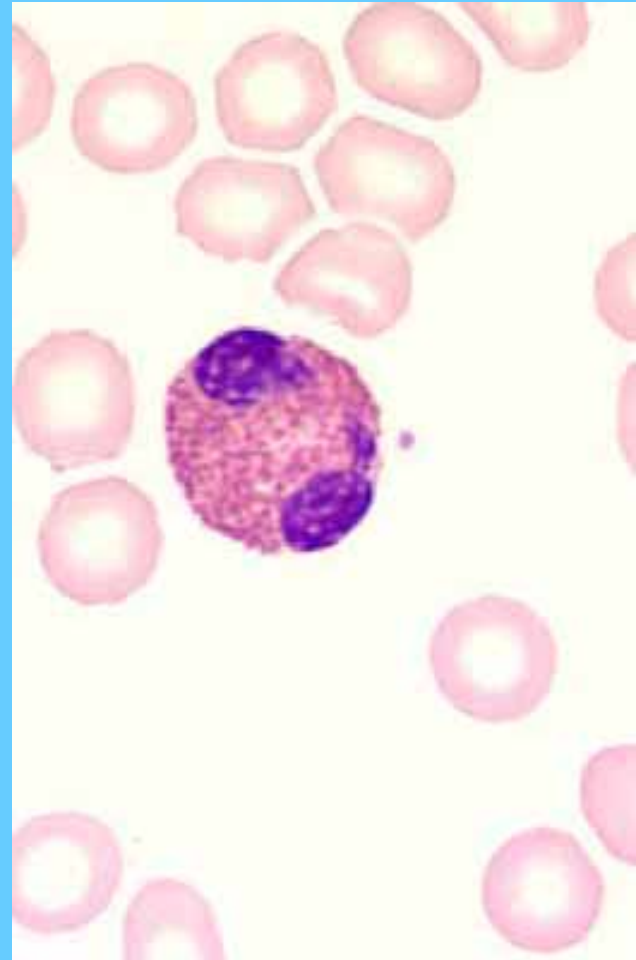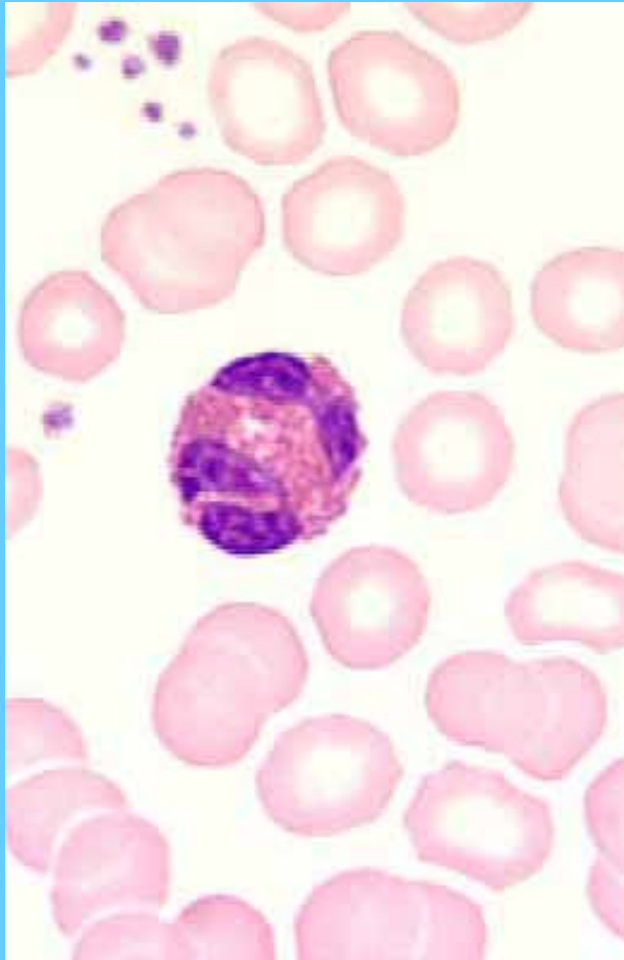
Neutrófilos segmentados



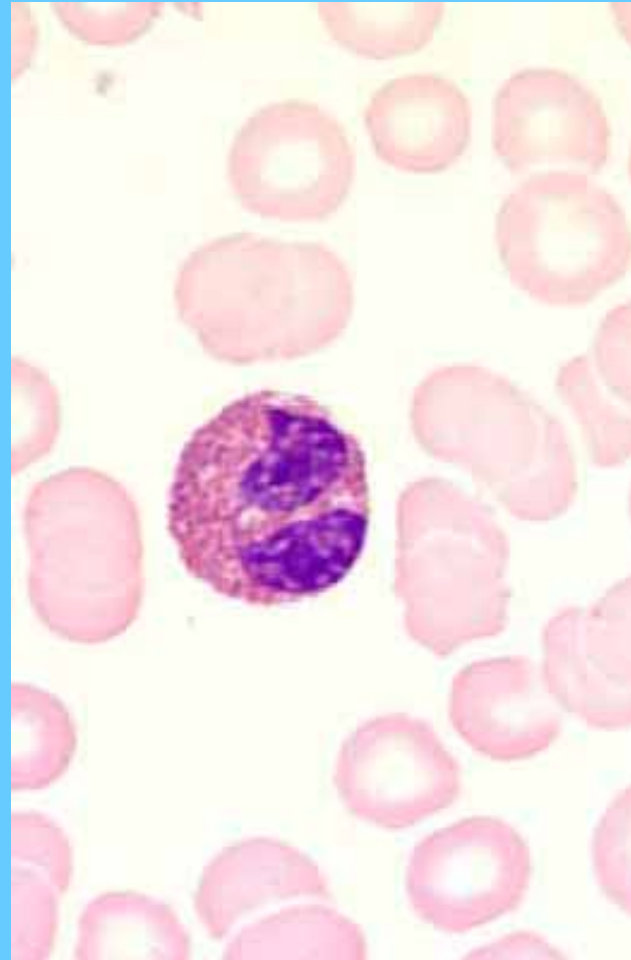
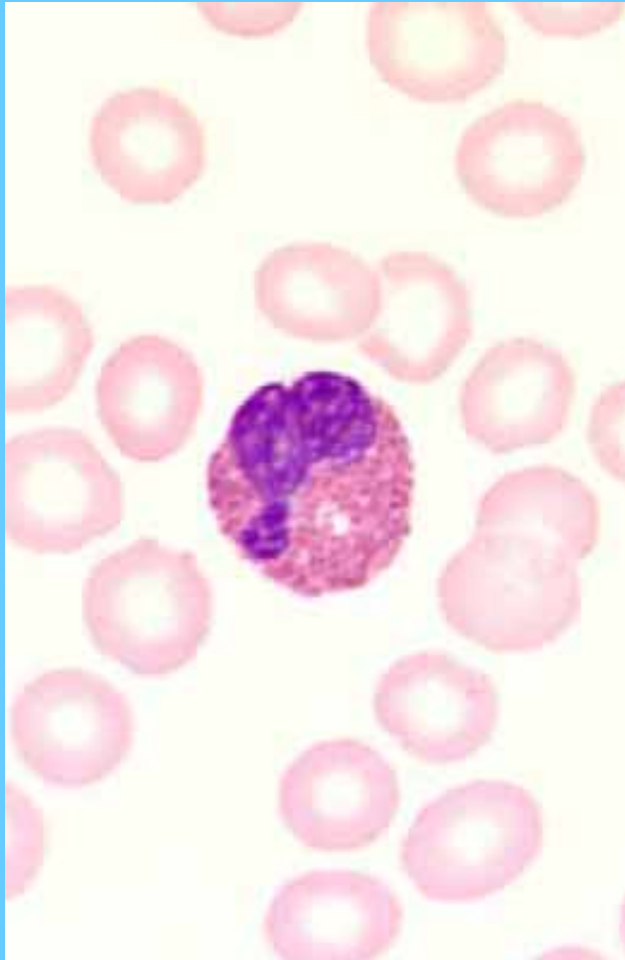
Eosinófilos



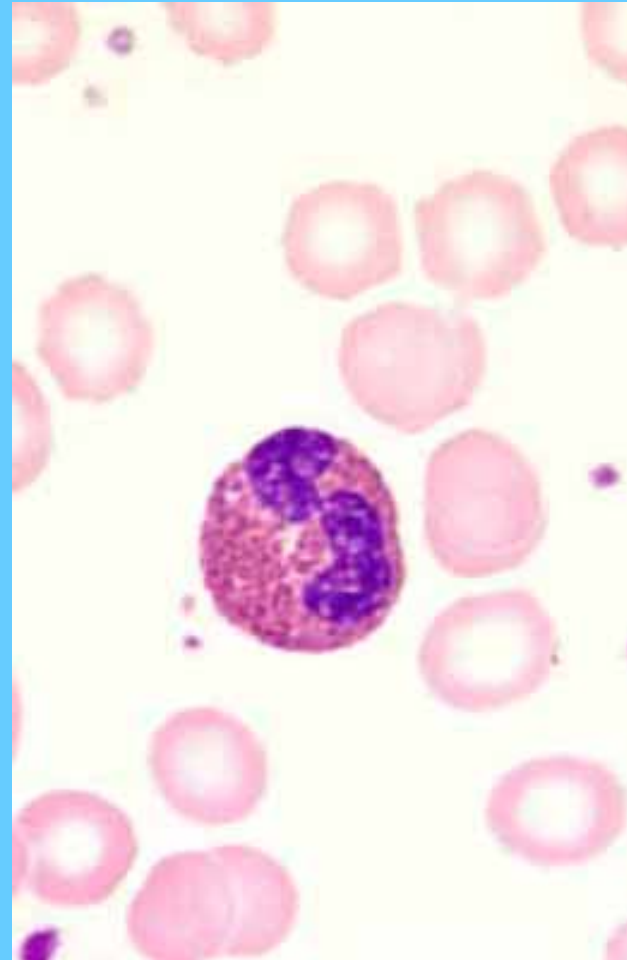
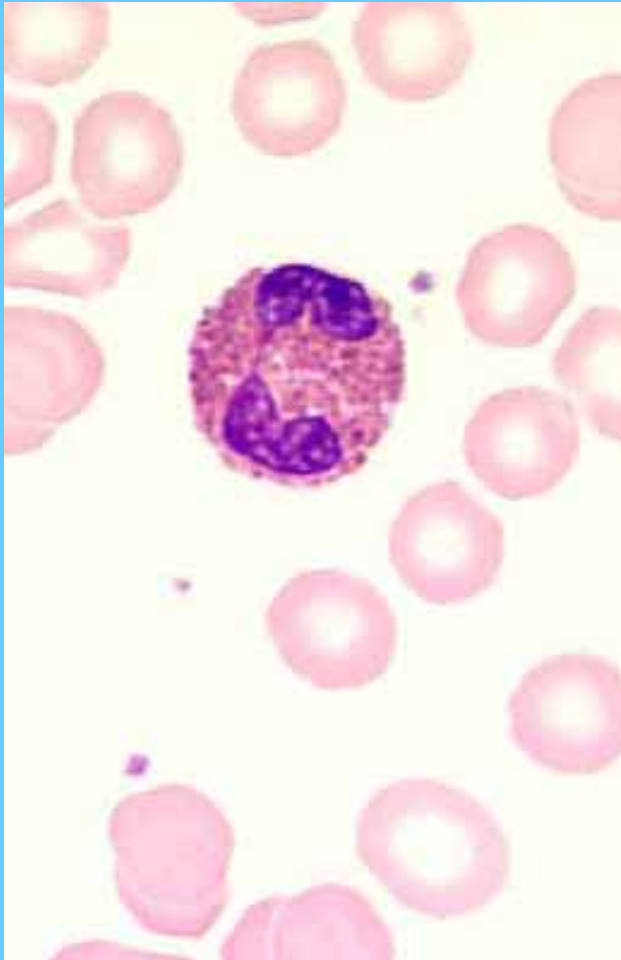
Eosinófilos



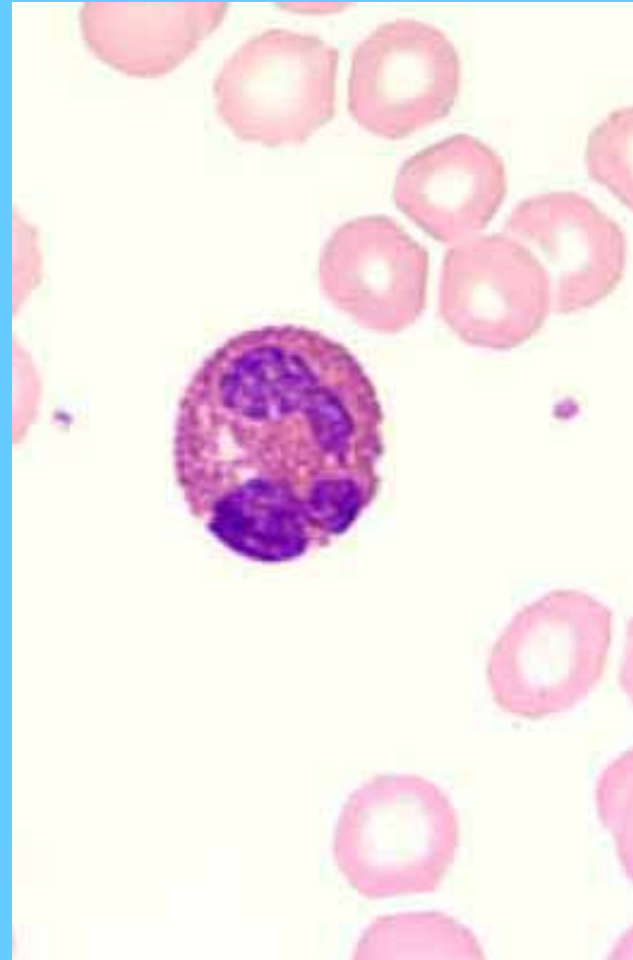
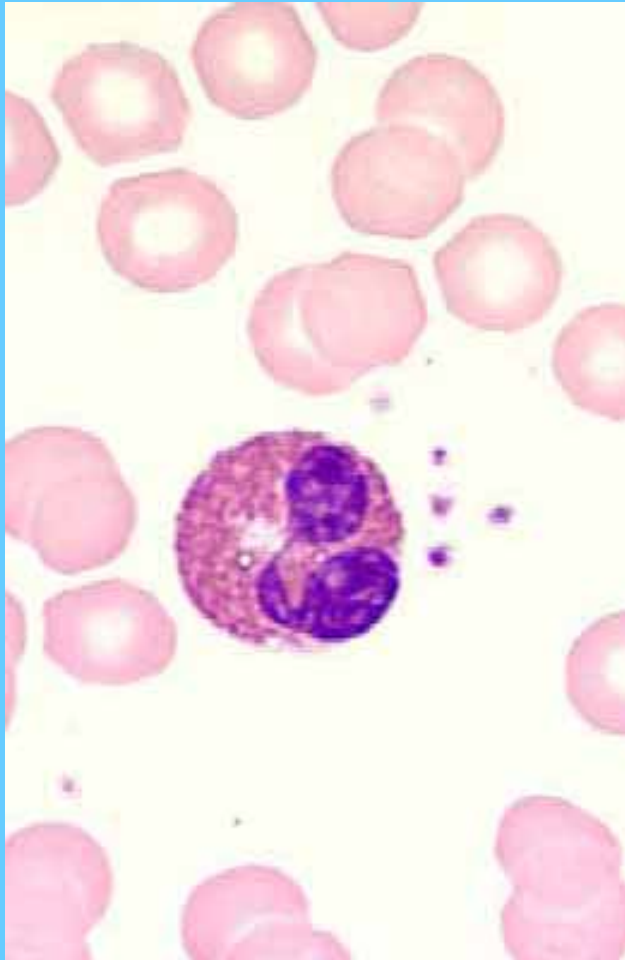
Eosinófilos



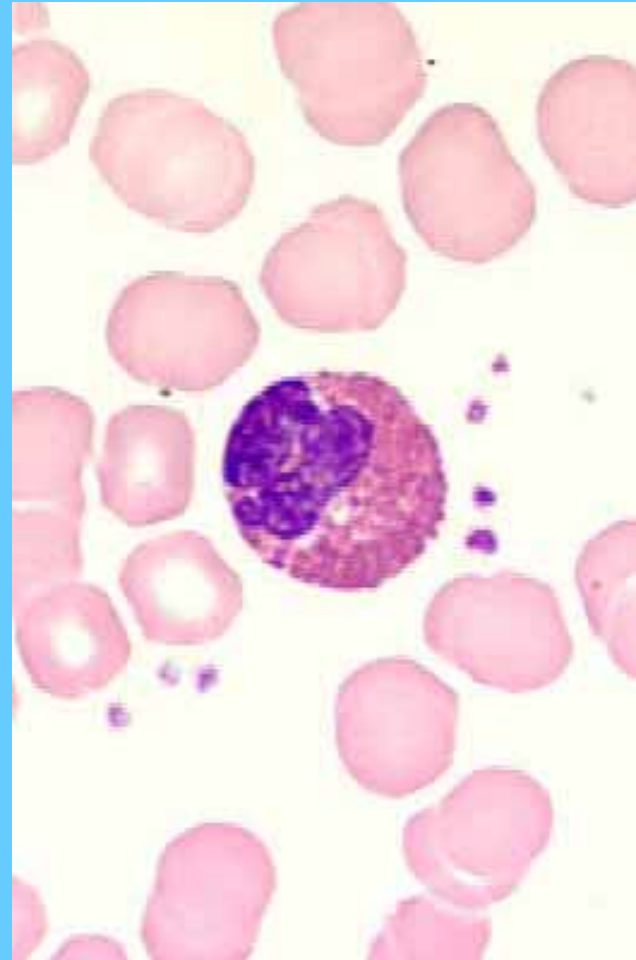
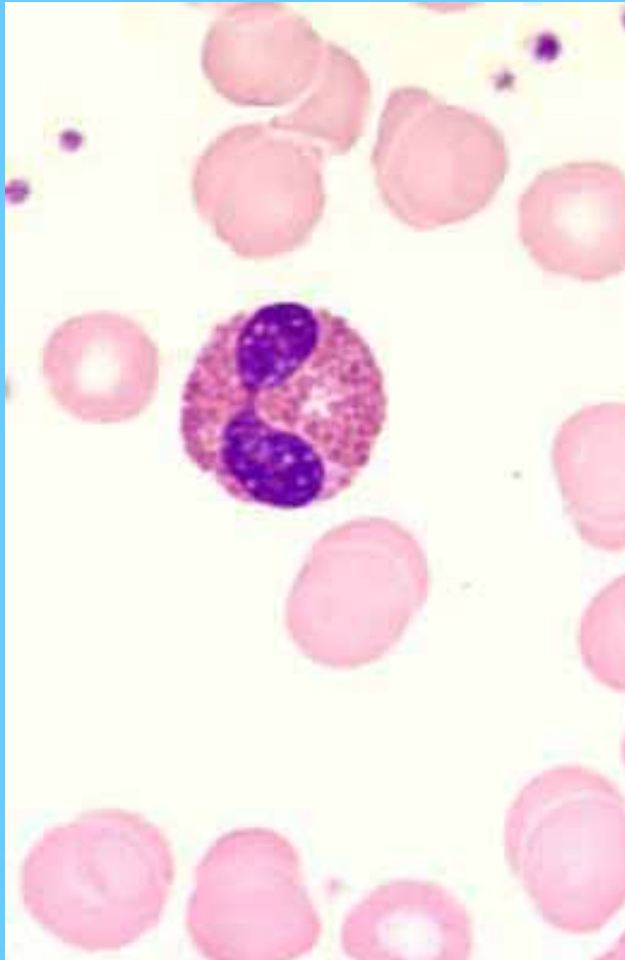
Eosinófilos



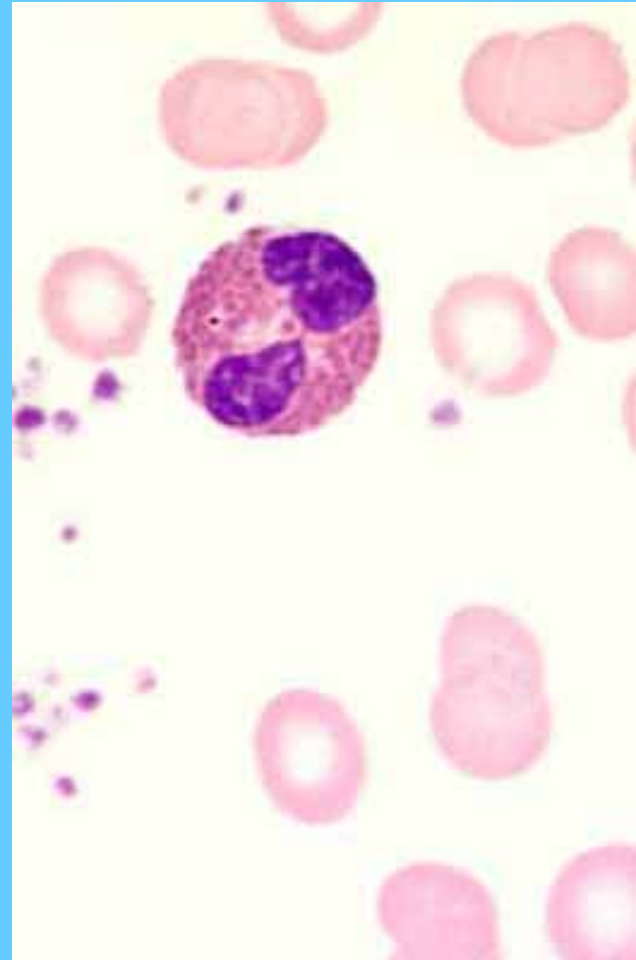
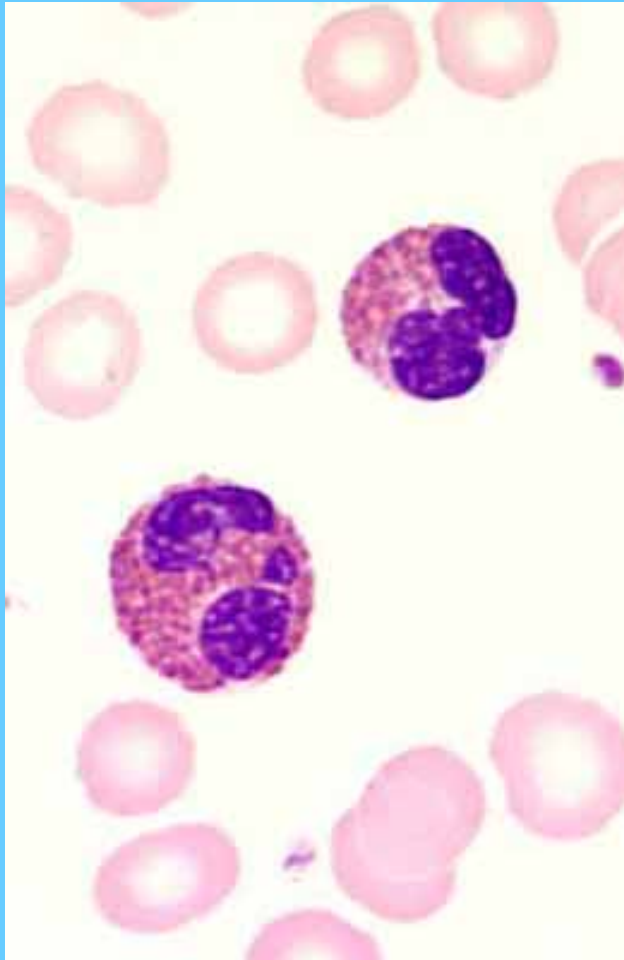
Eosinófilos



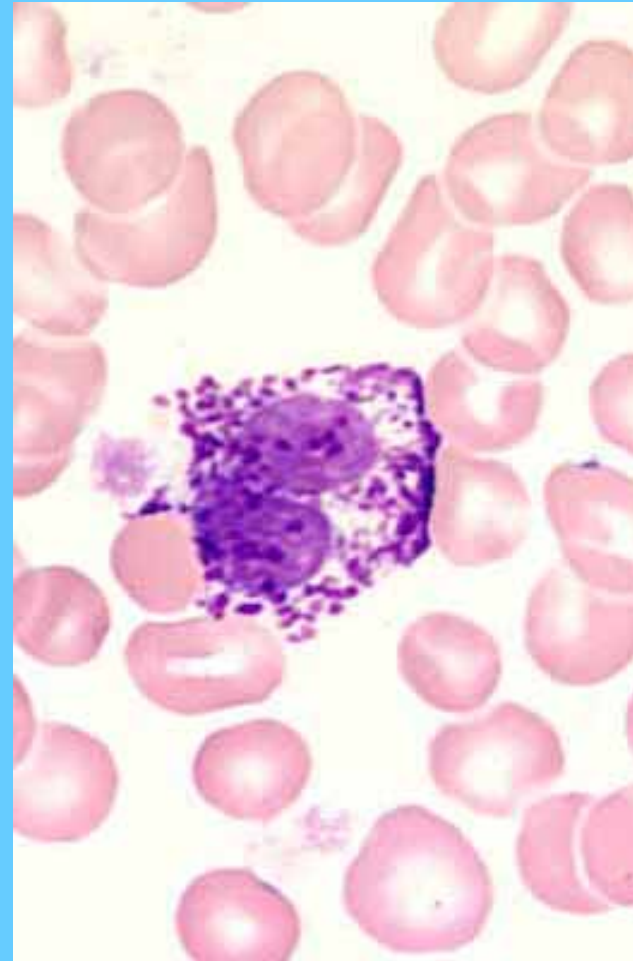
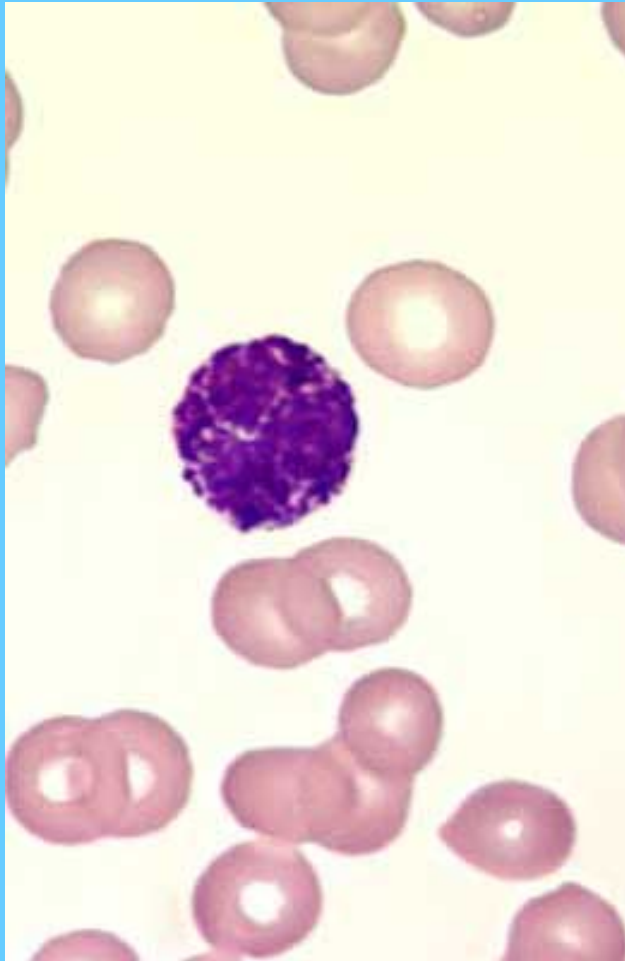Eosinófilos



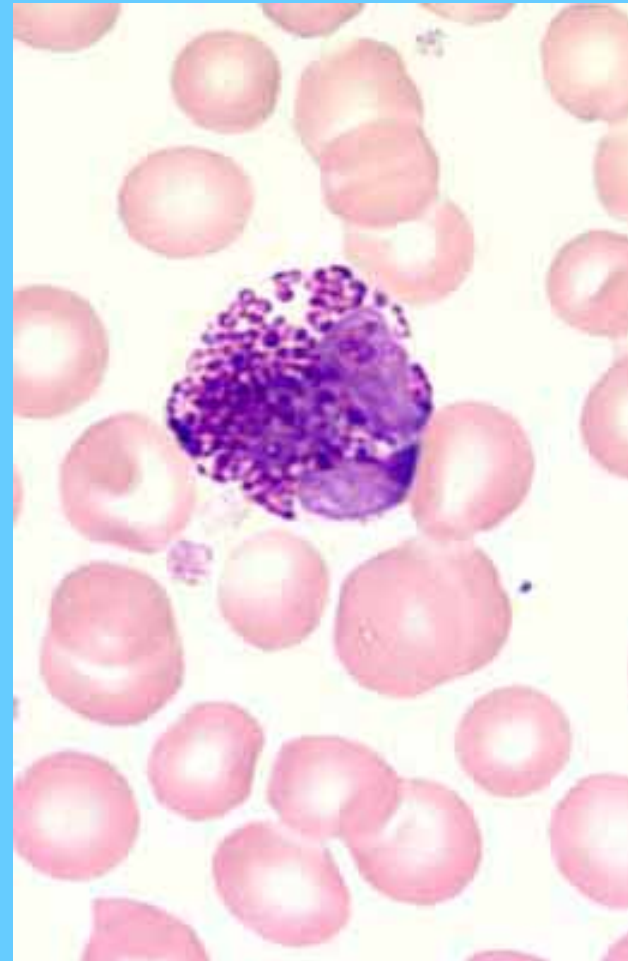
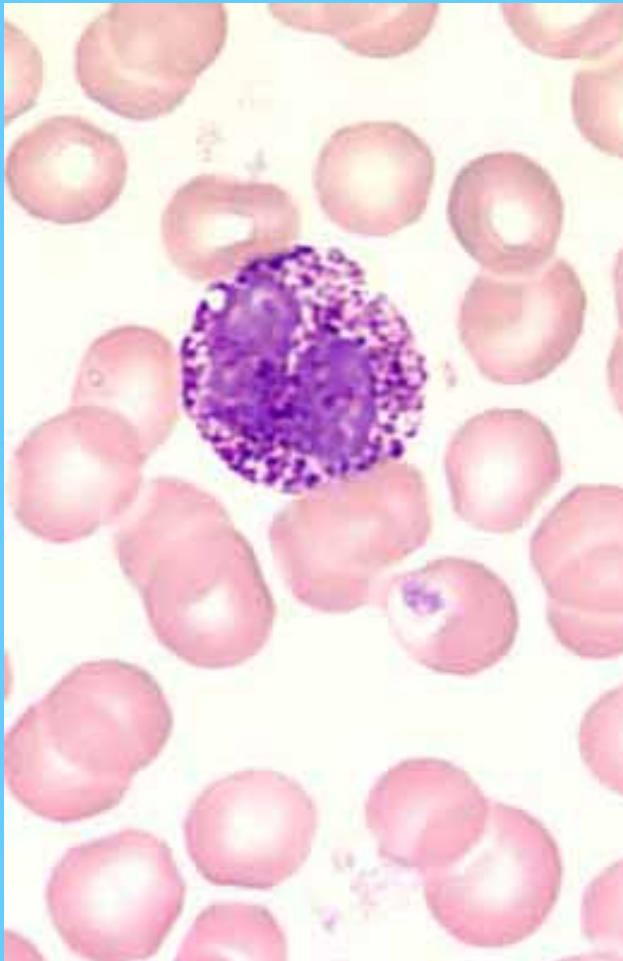
Eosinófilos



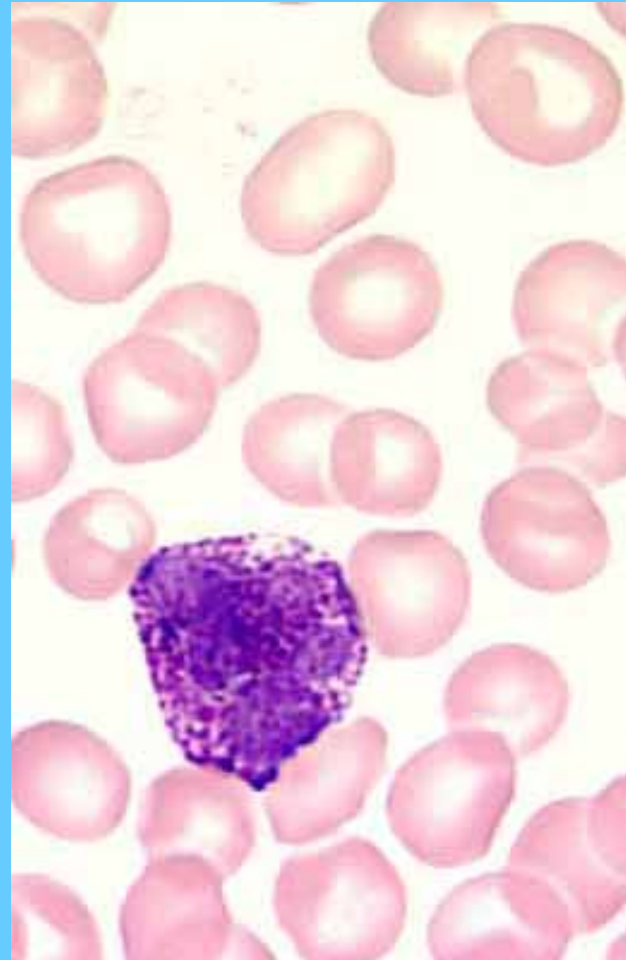
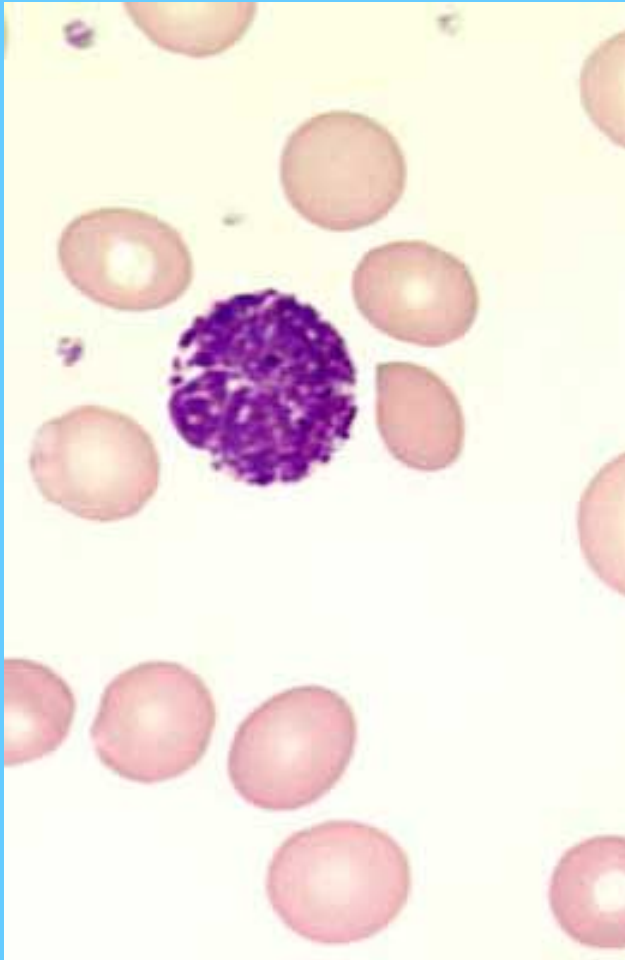
Basófilos



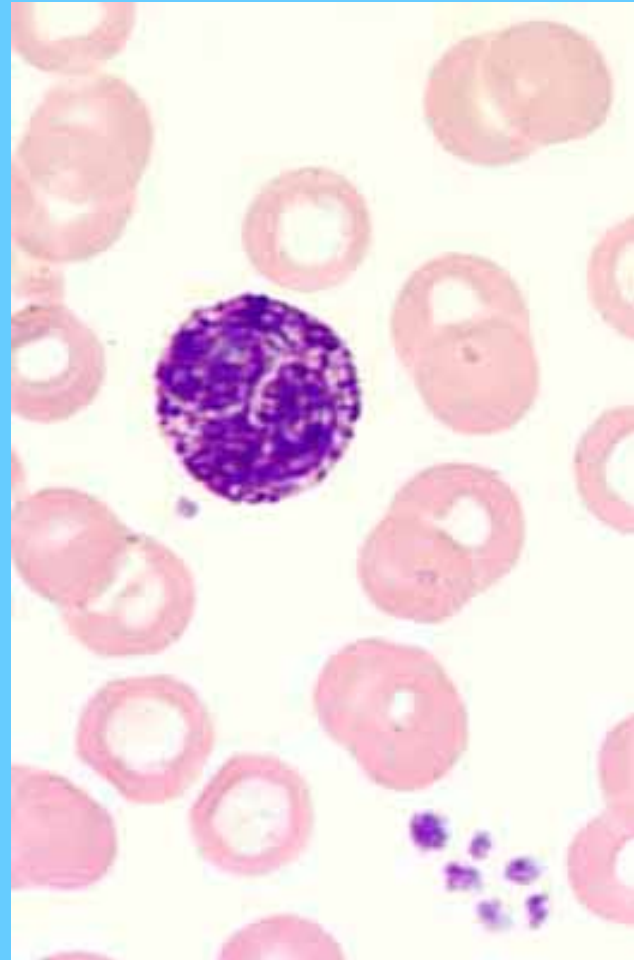
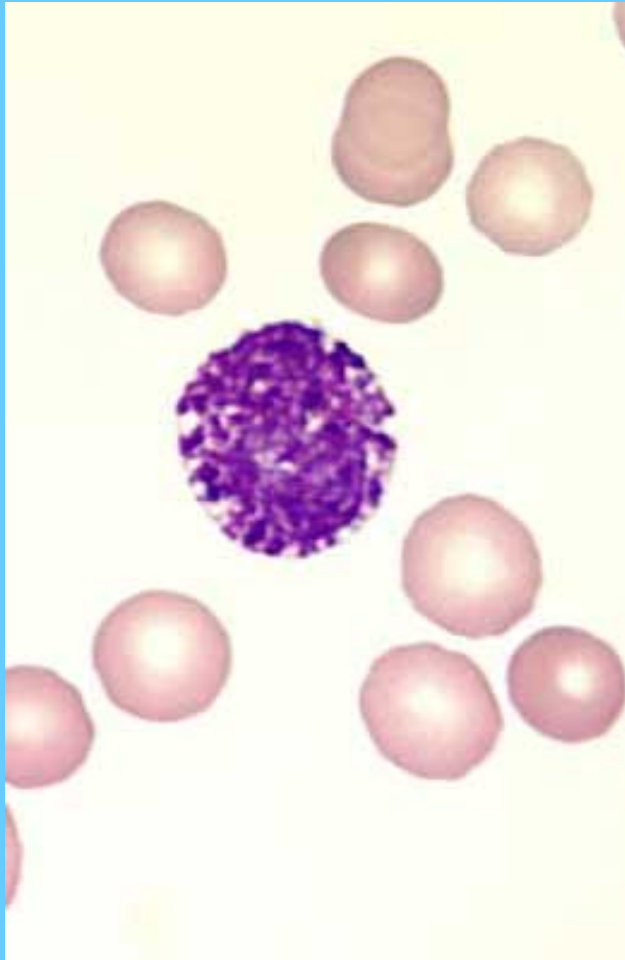
Basófilos



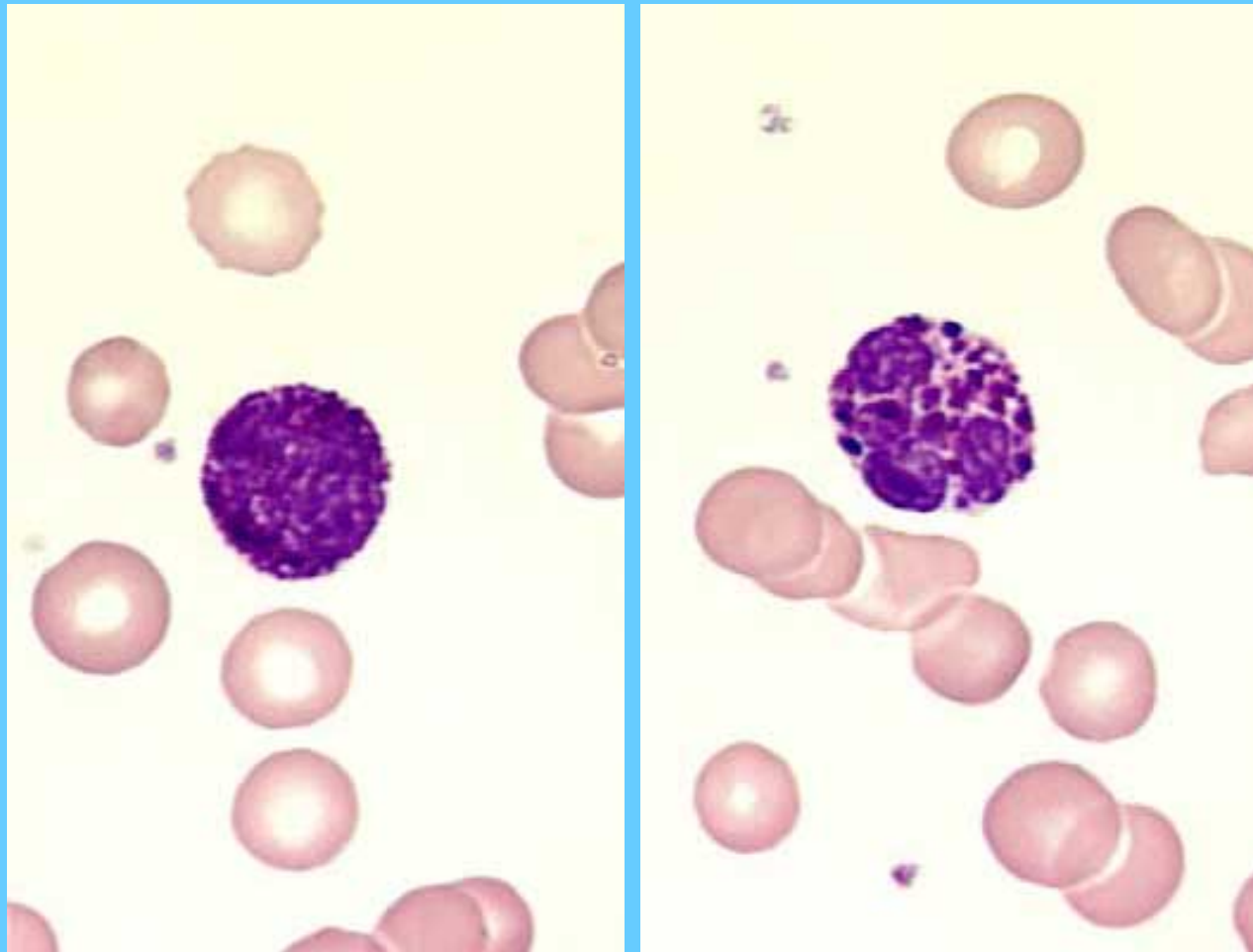
Basófilos



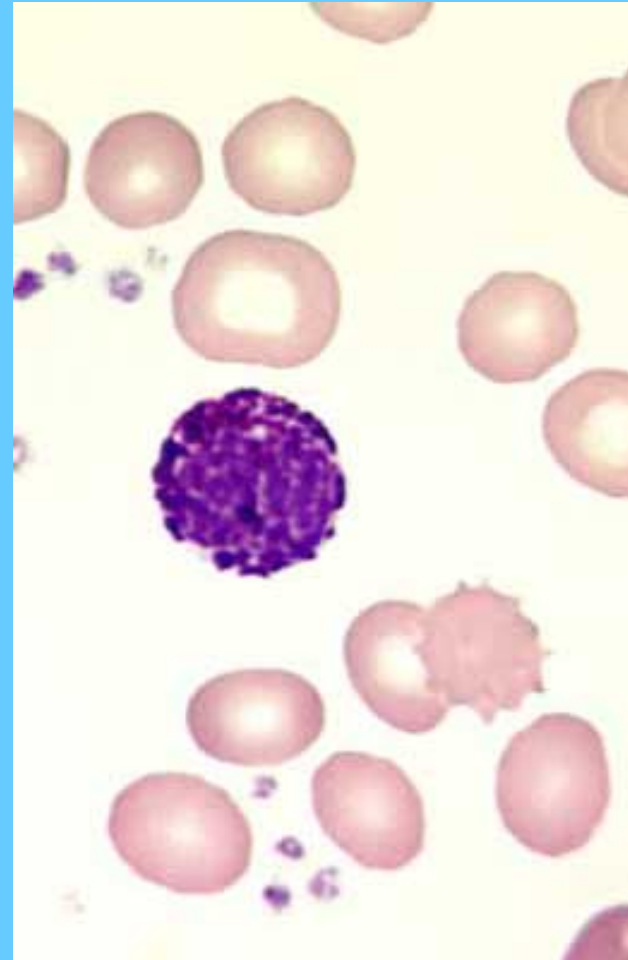
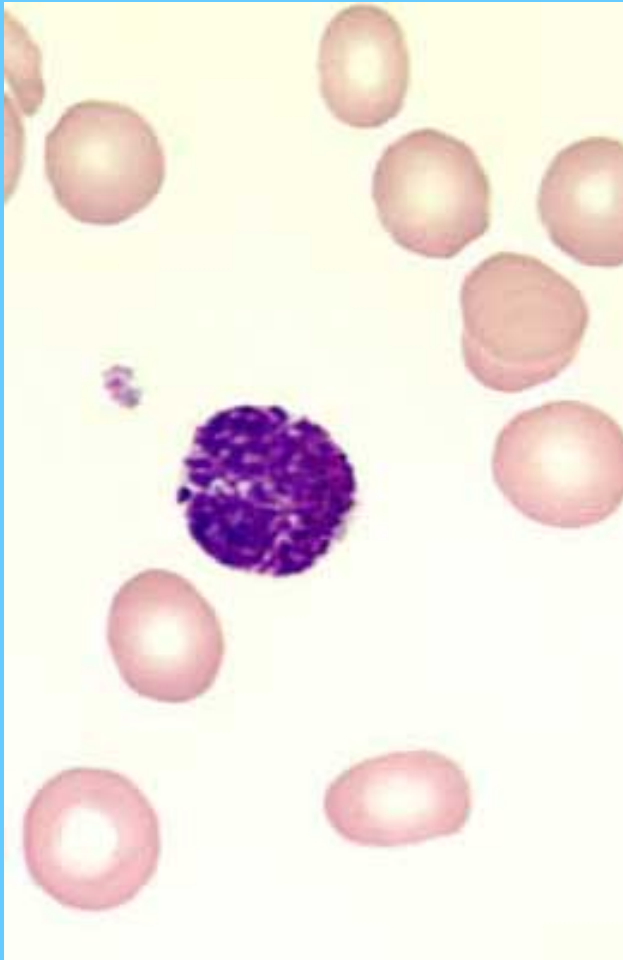
Basófilos



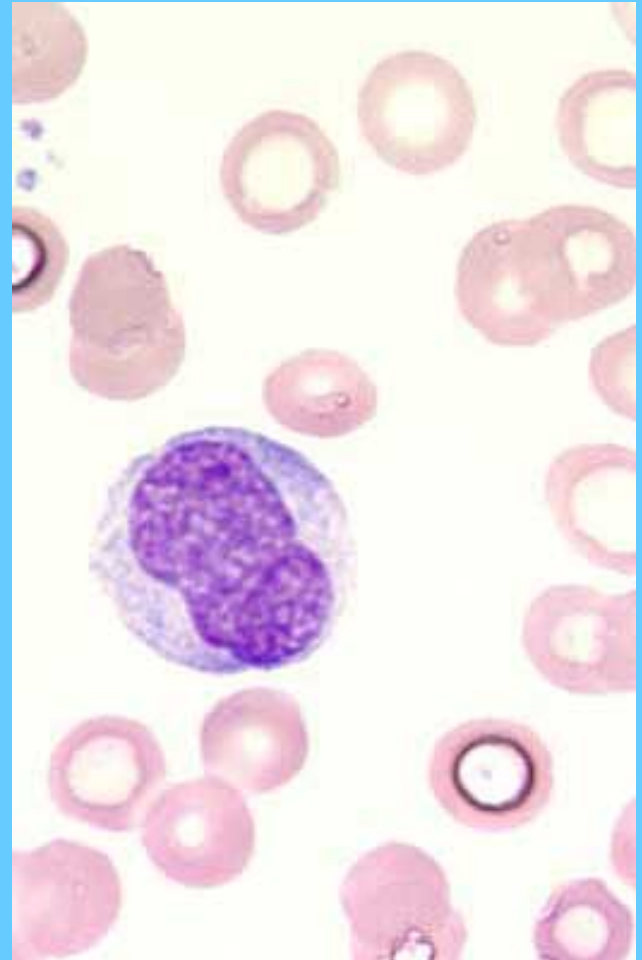
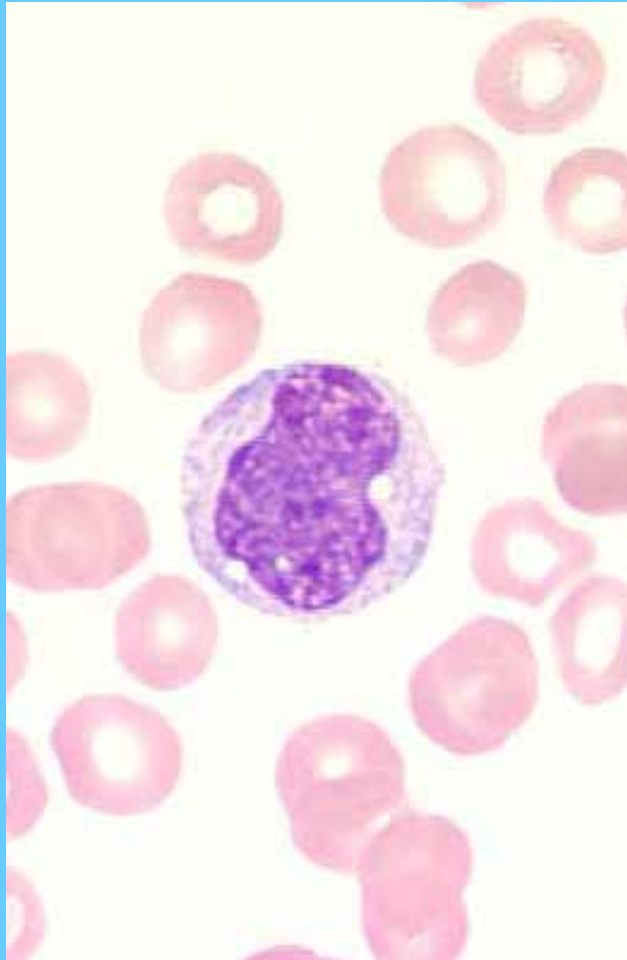
Basófilos



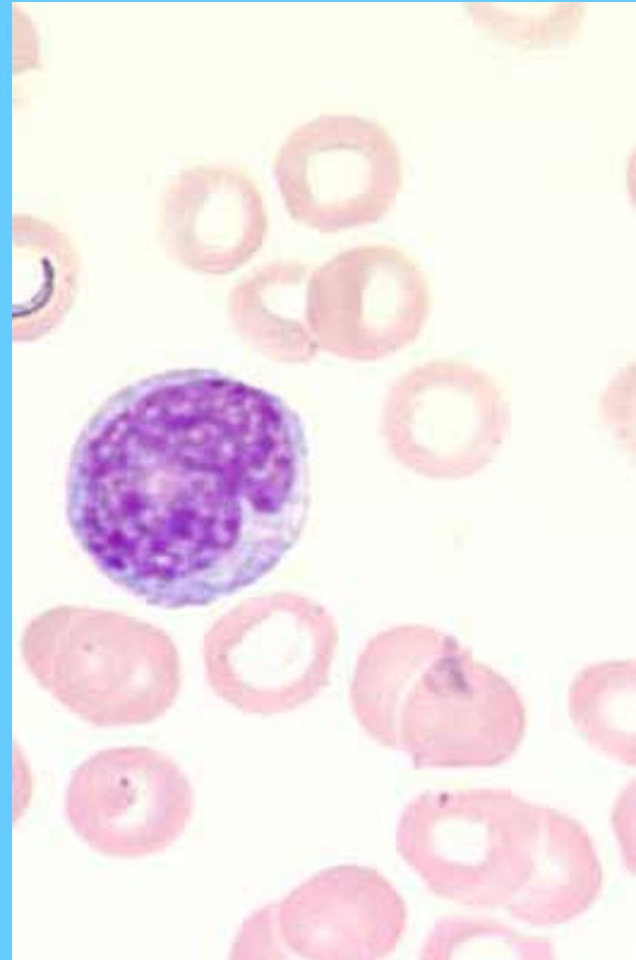
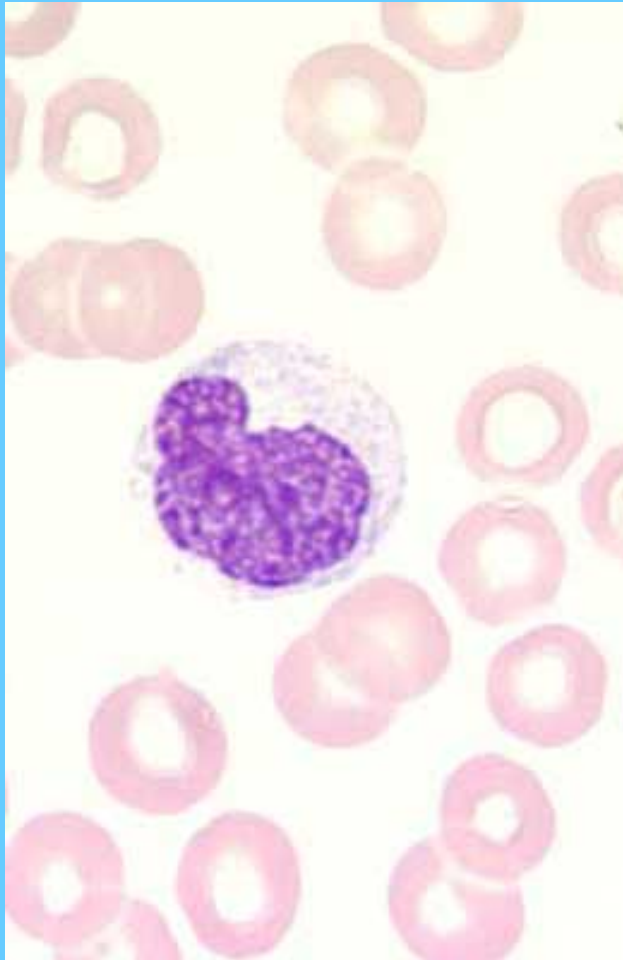
Basófilos



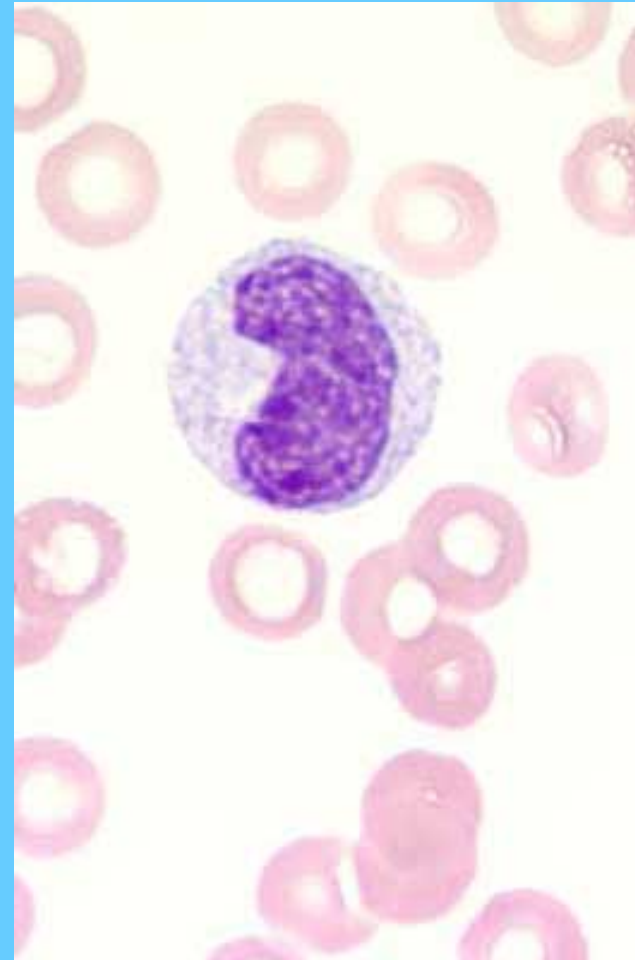
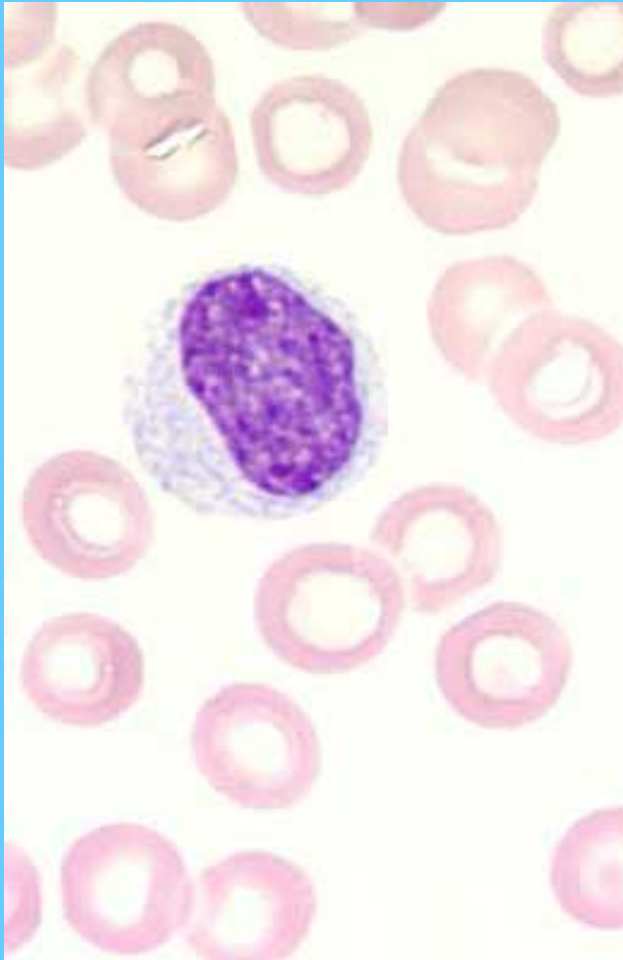
Monocitos



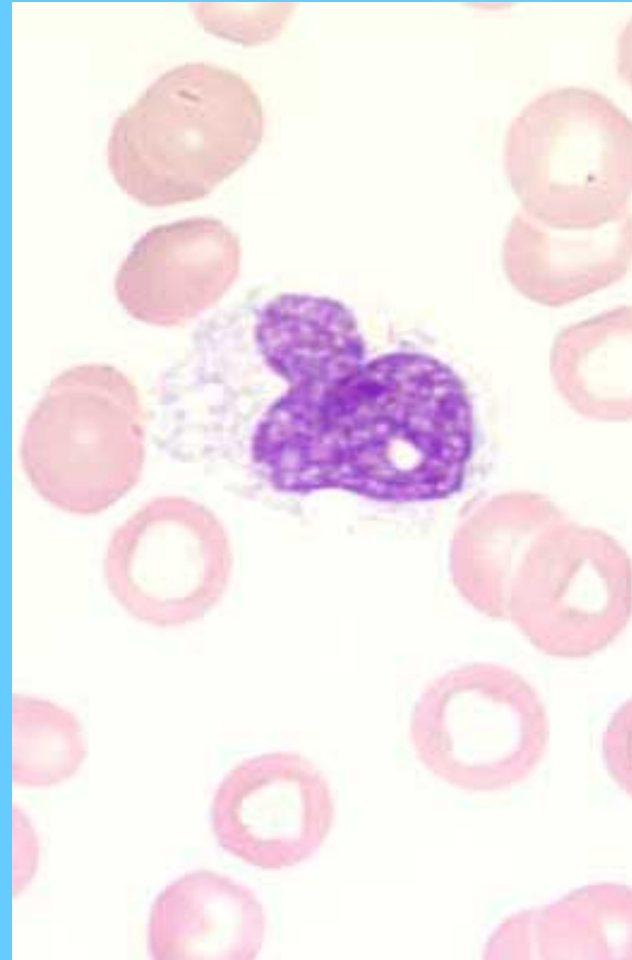
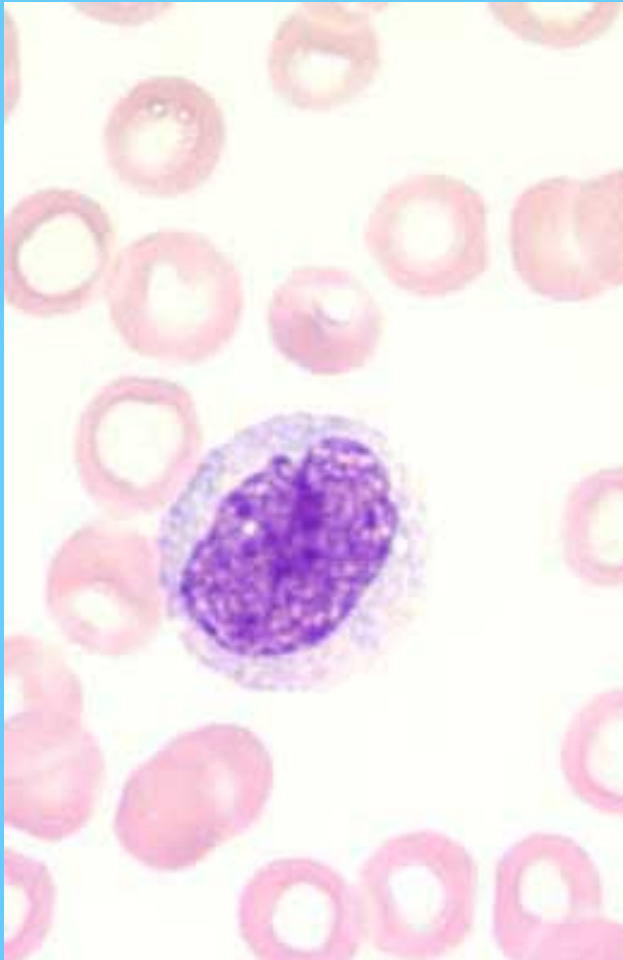
Monocitos



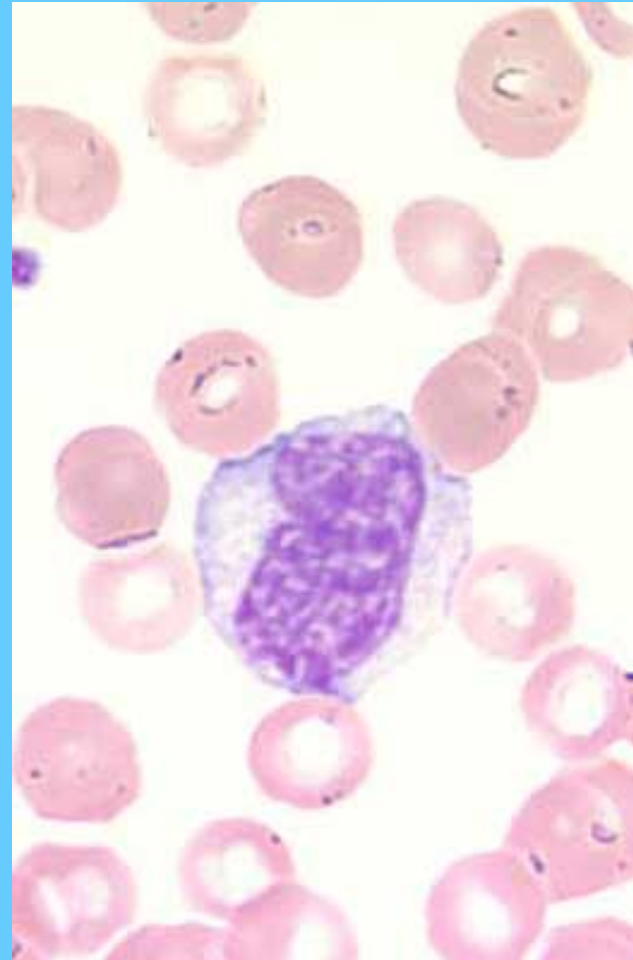
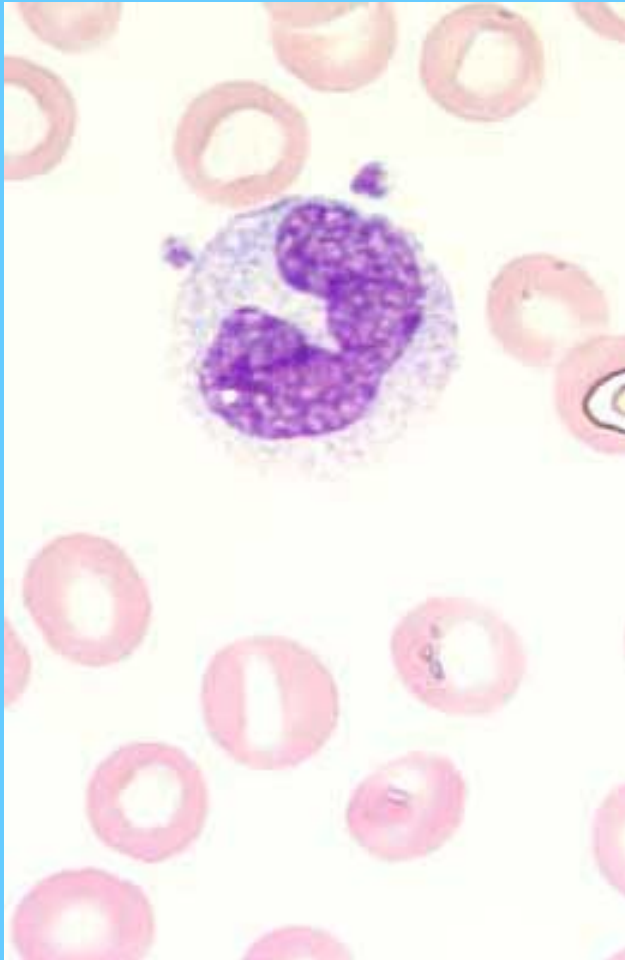
Monocitos



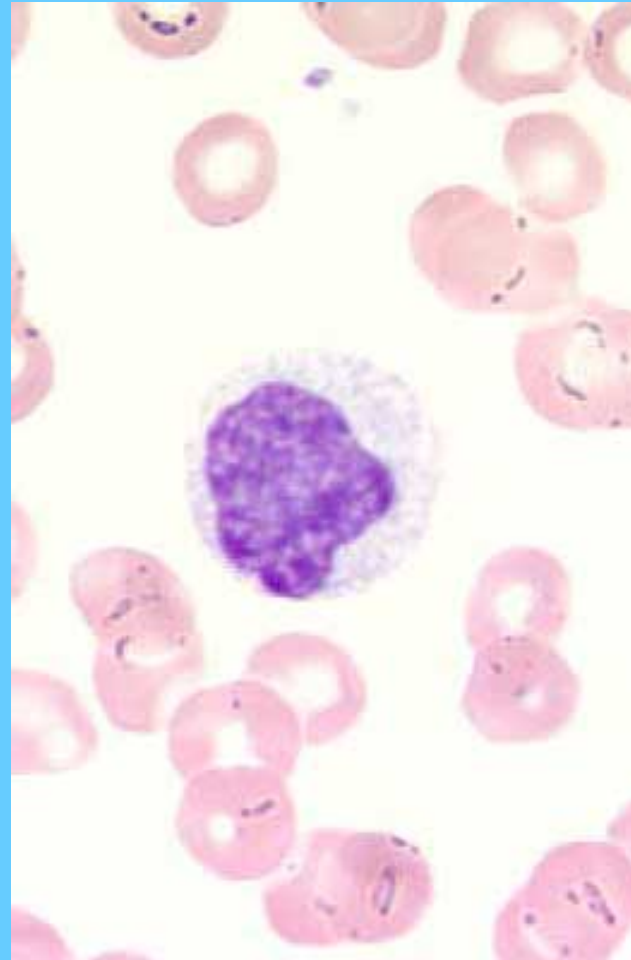
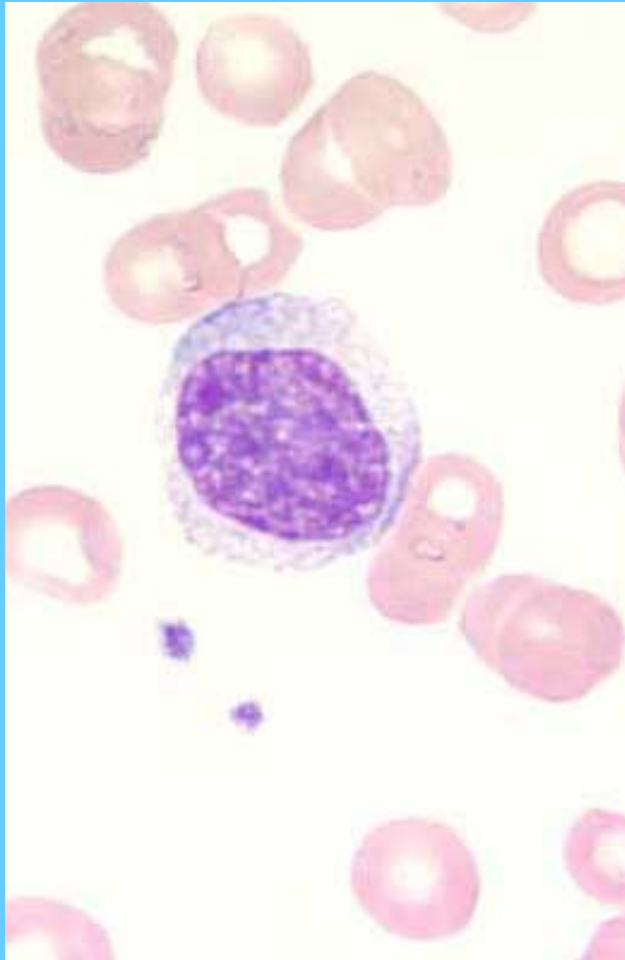
Monocitos



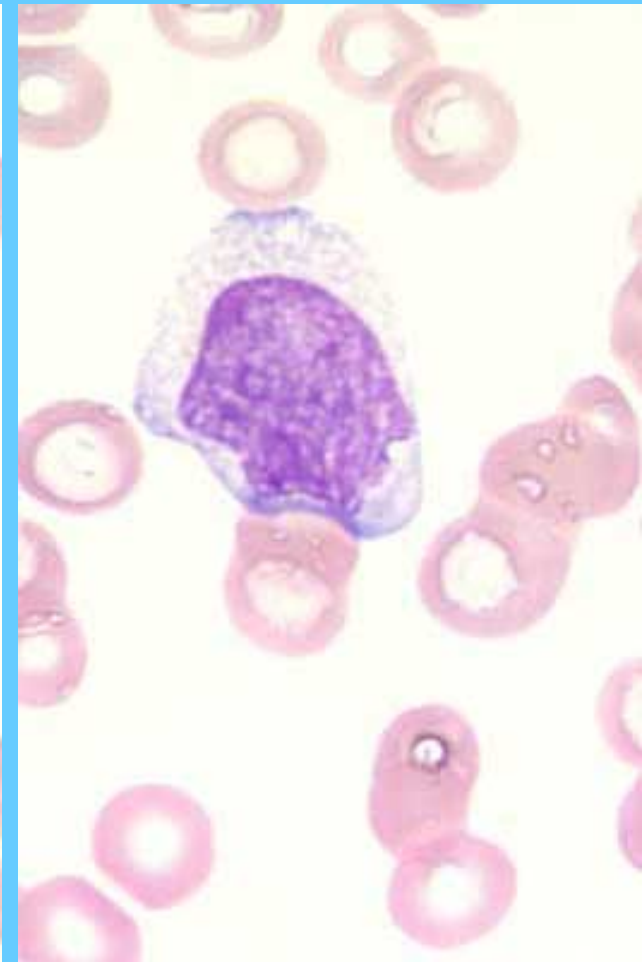
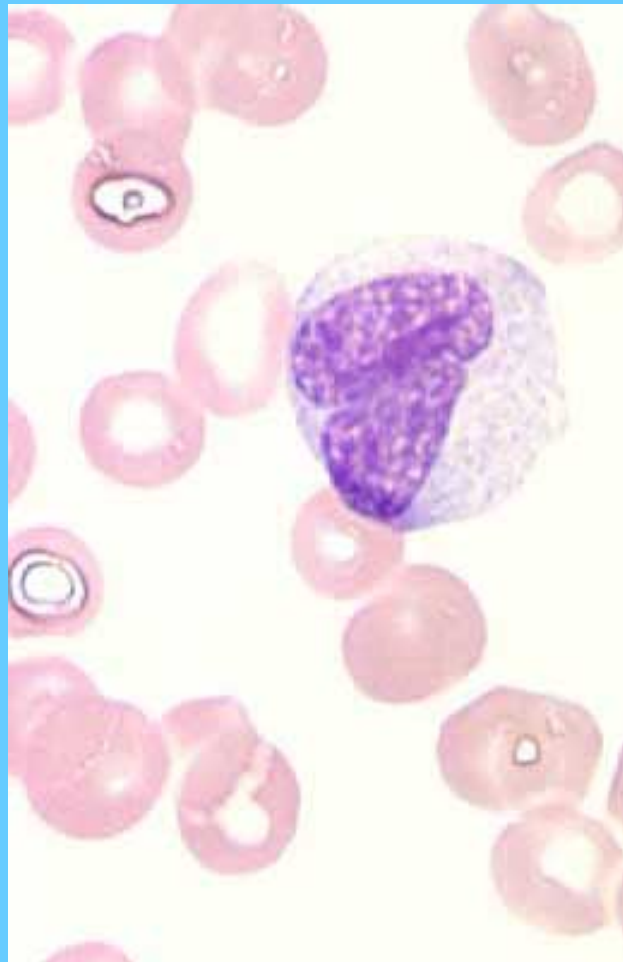
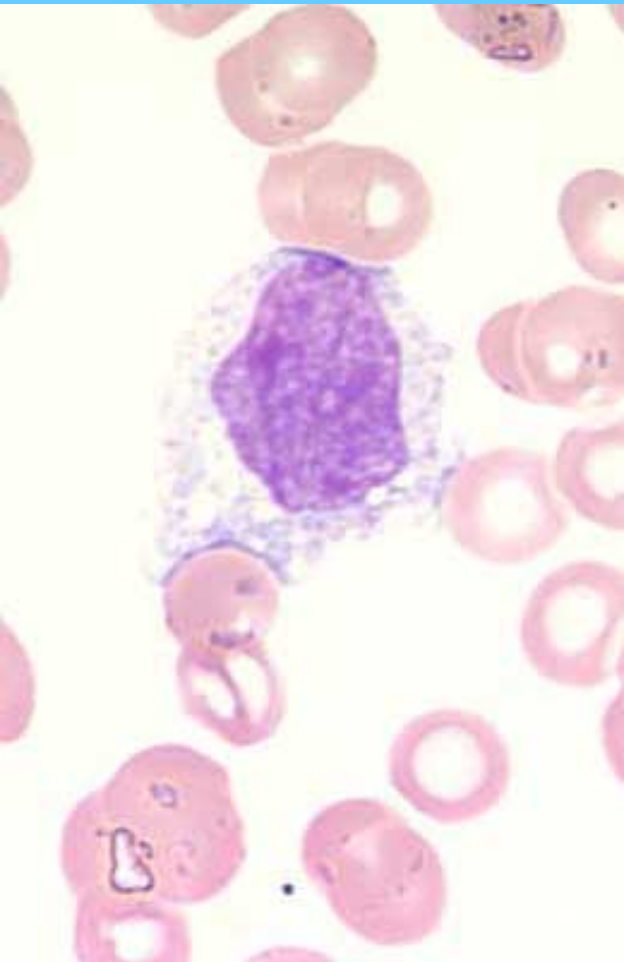
Monocitos



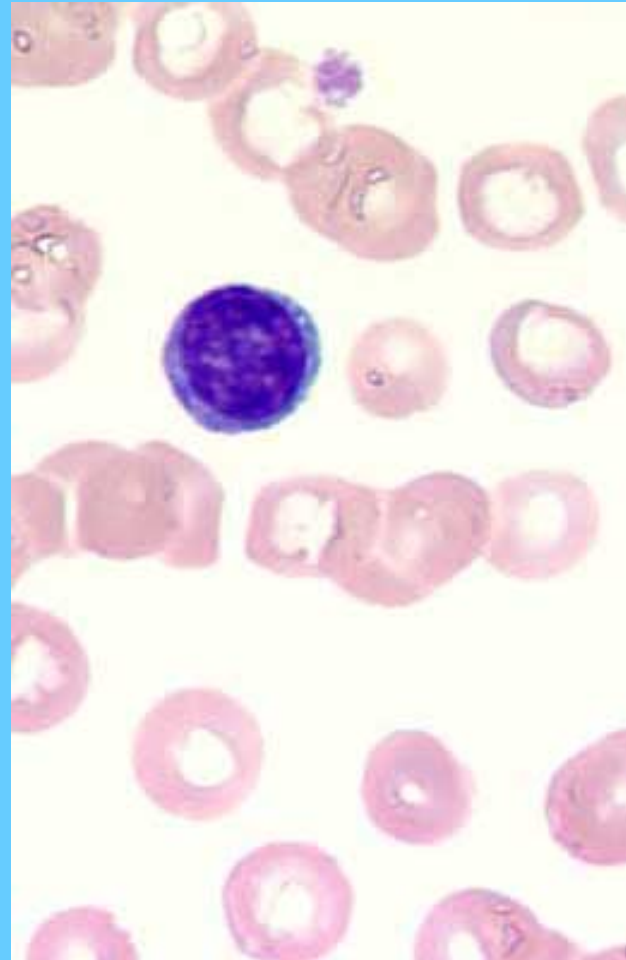
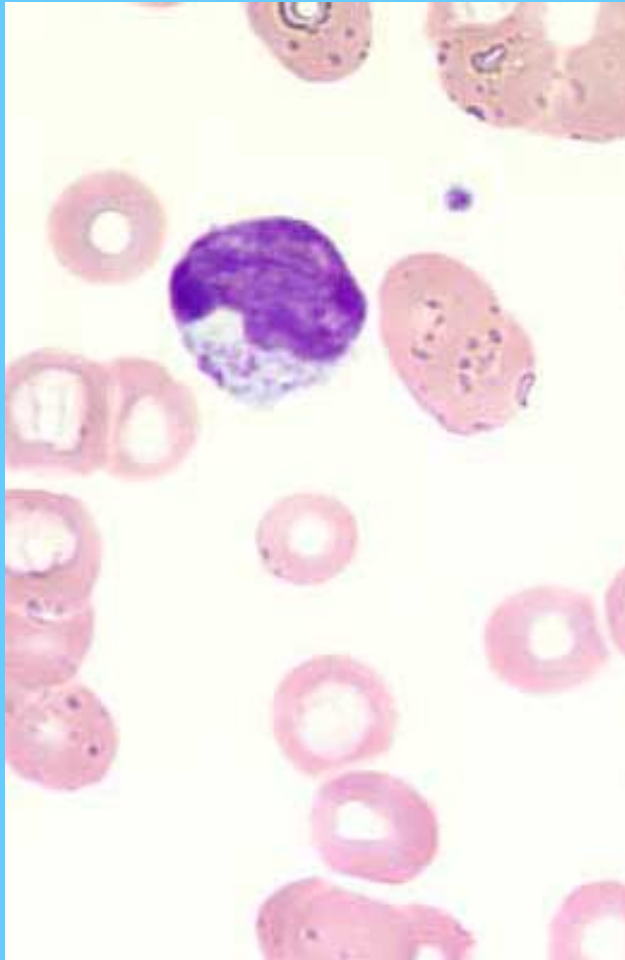
Monocitos



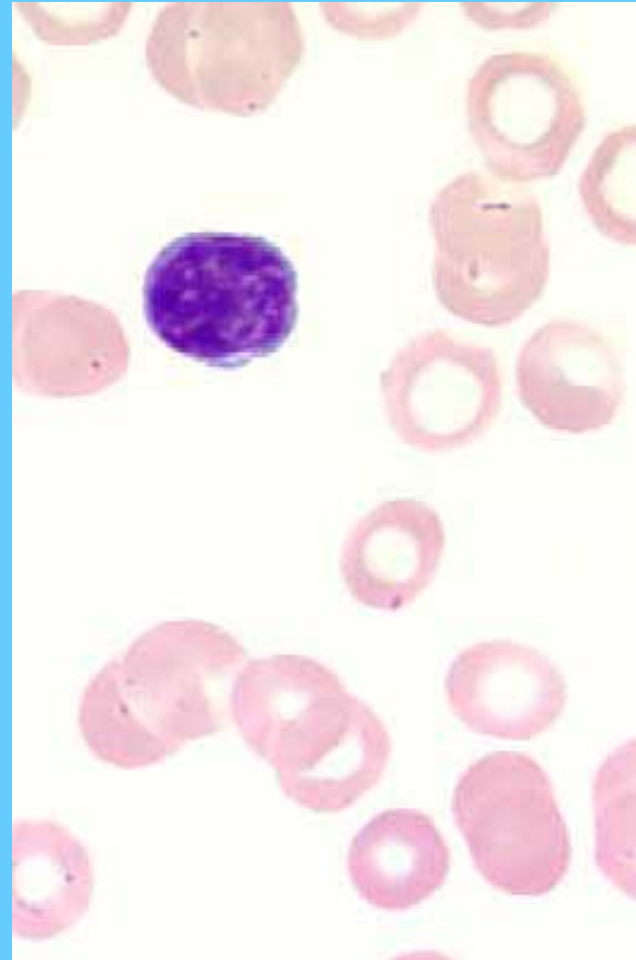
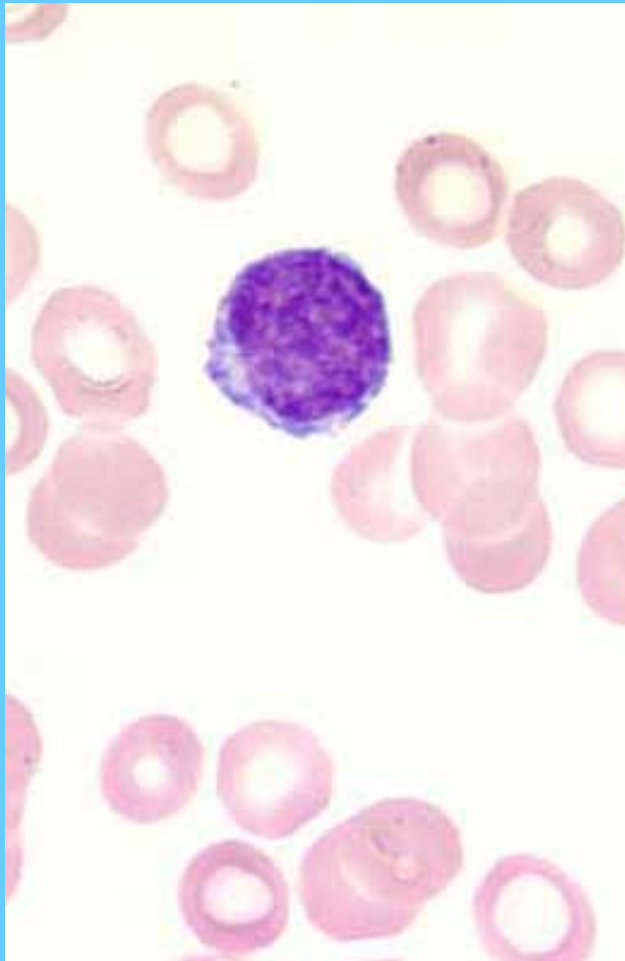
Monocitos



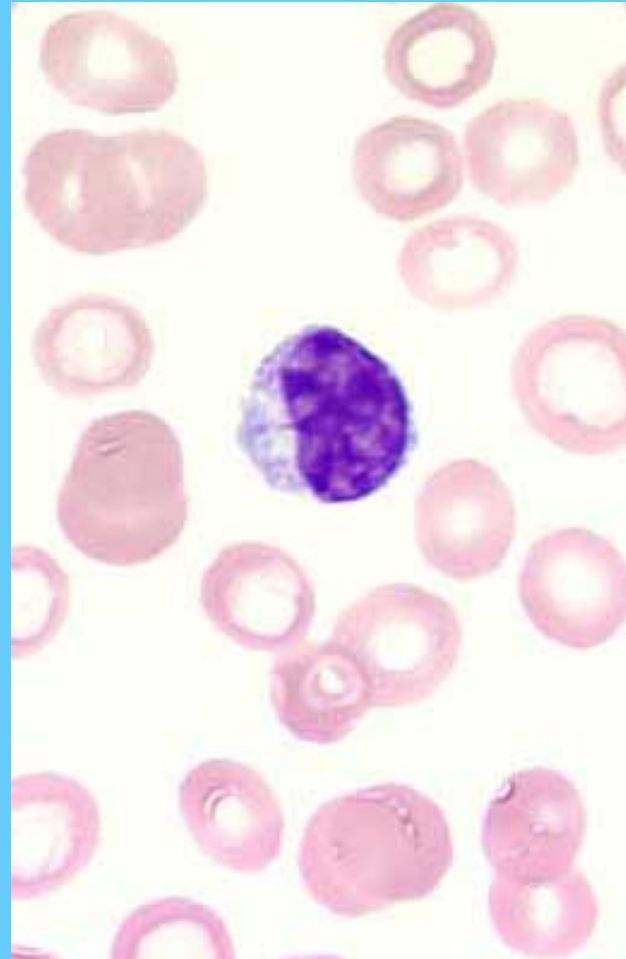
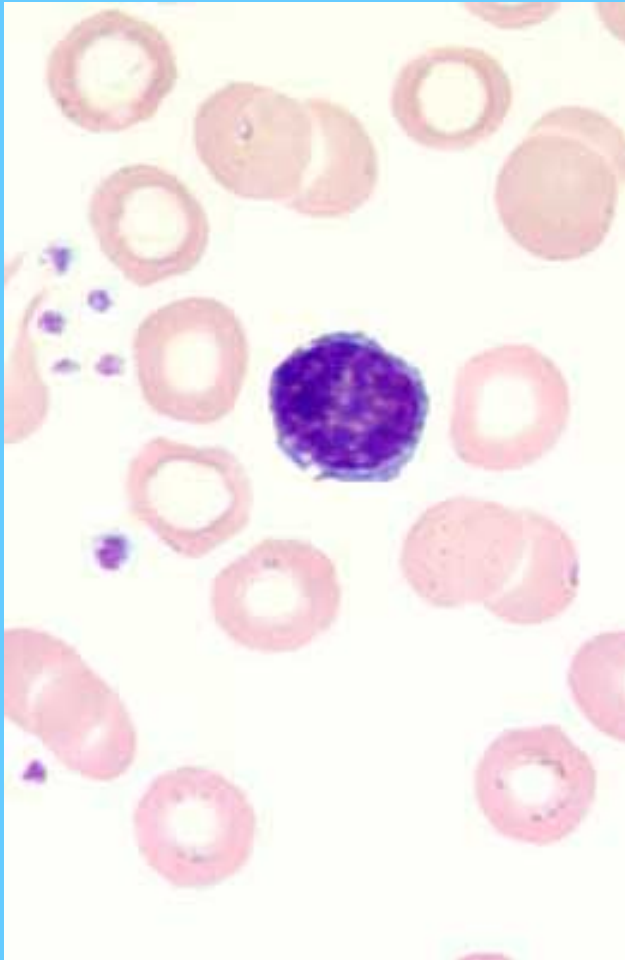
Linfocitos



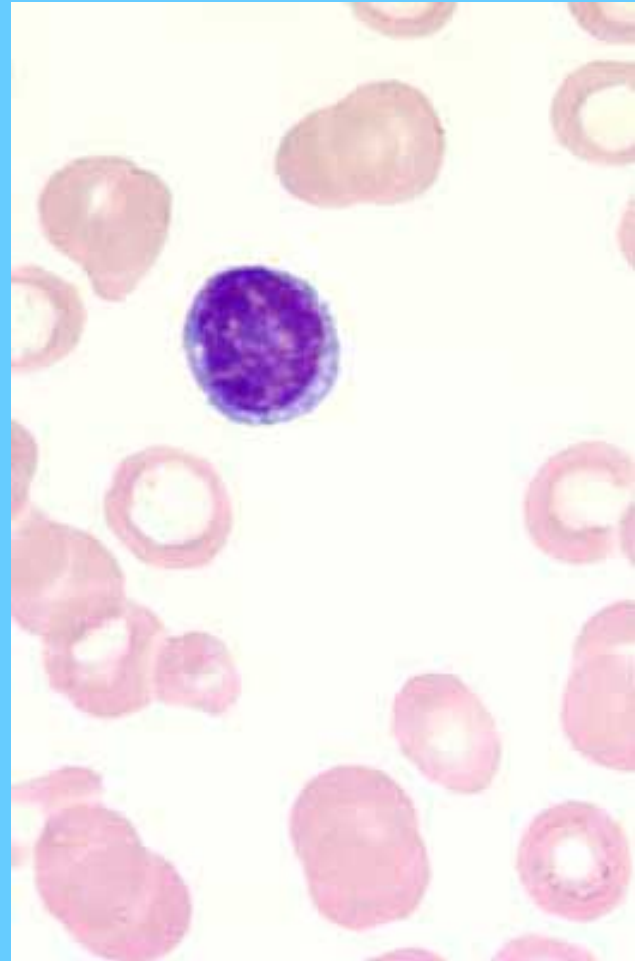
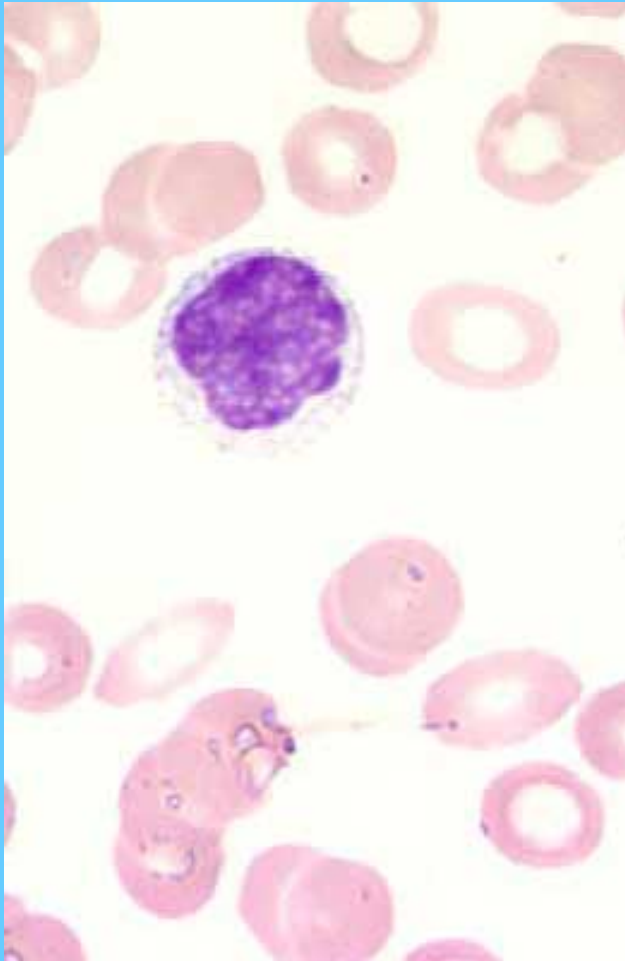
Linfocitos



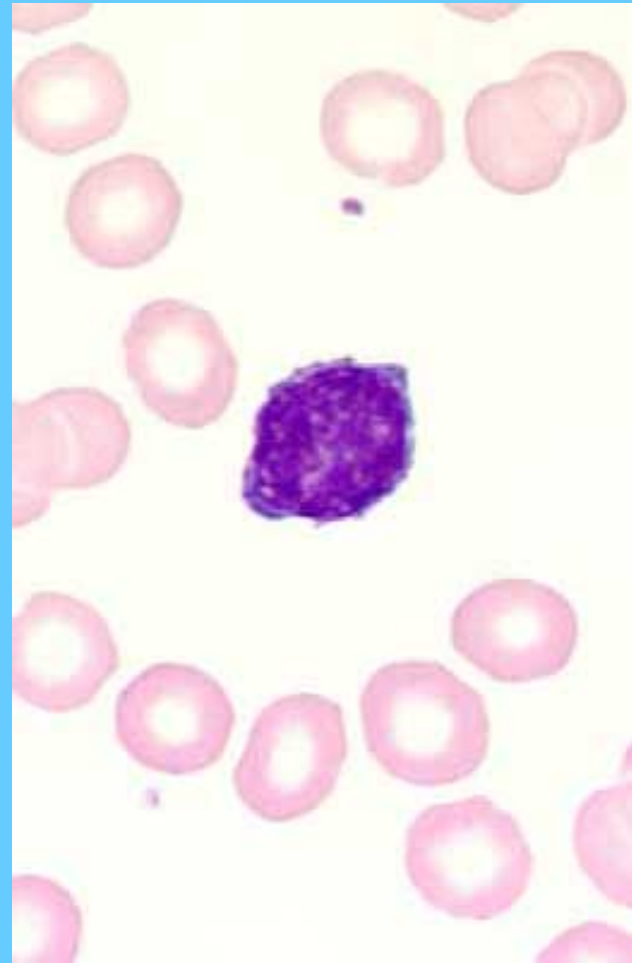
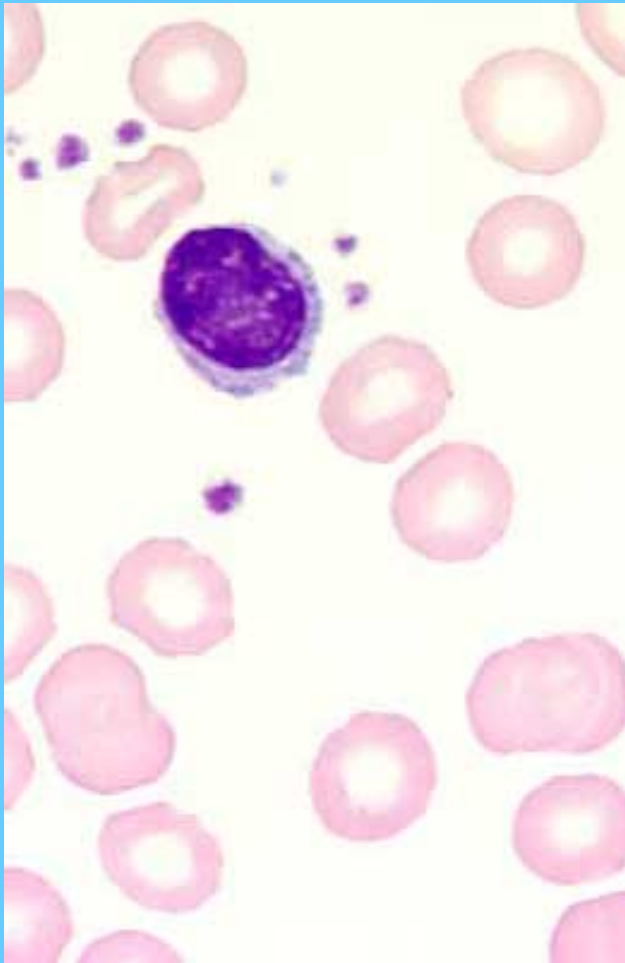
Linfocitos



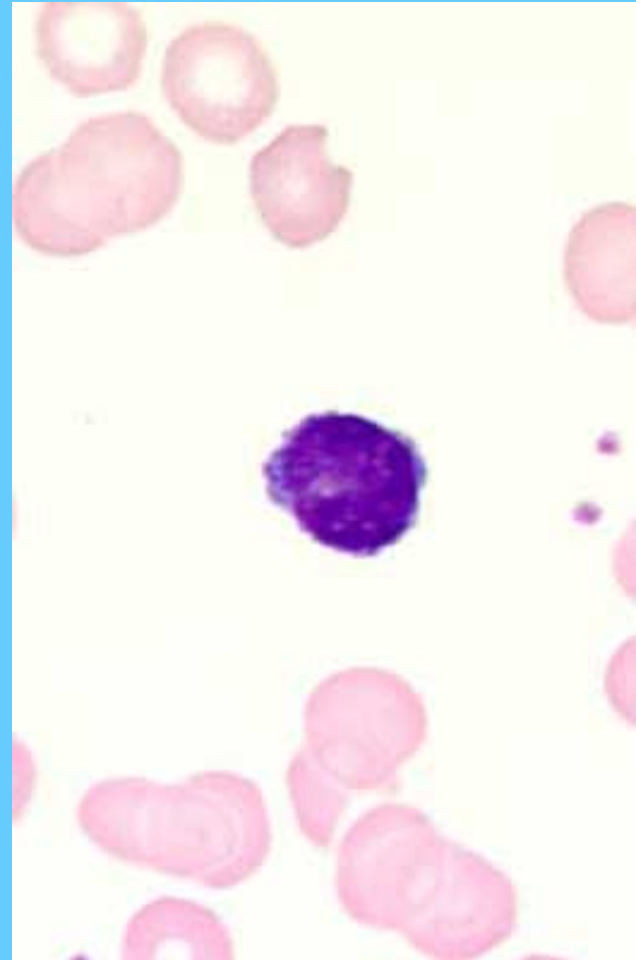
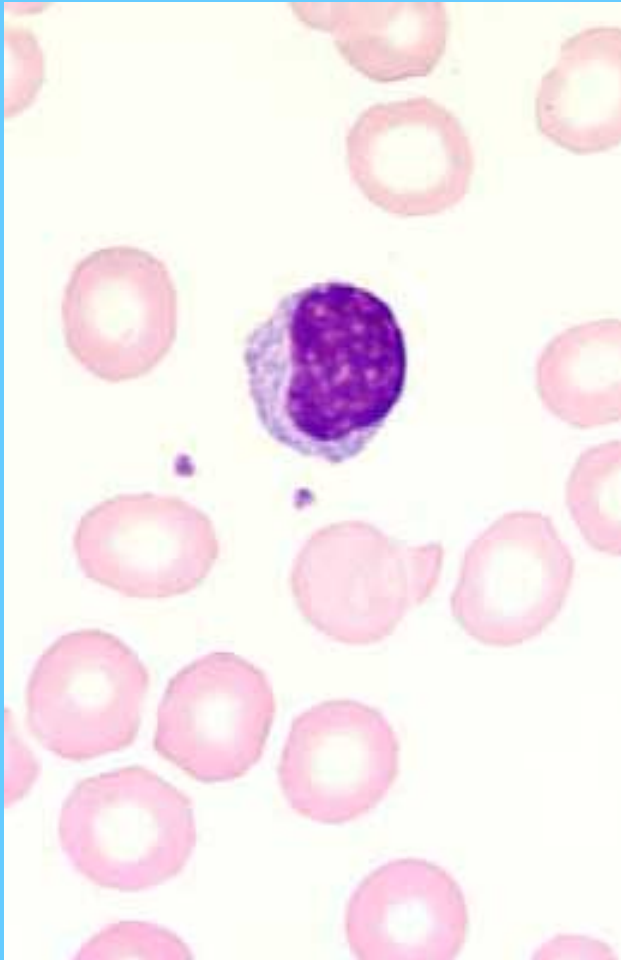
Linfocitos



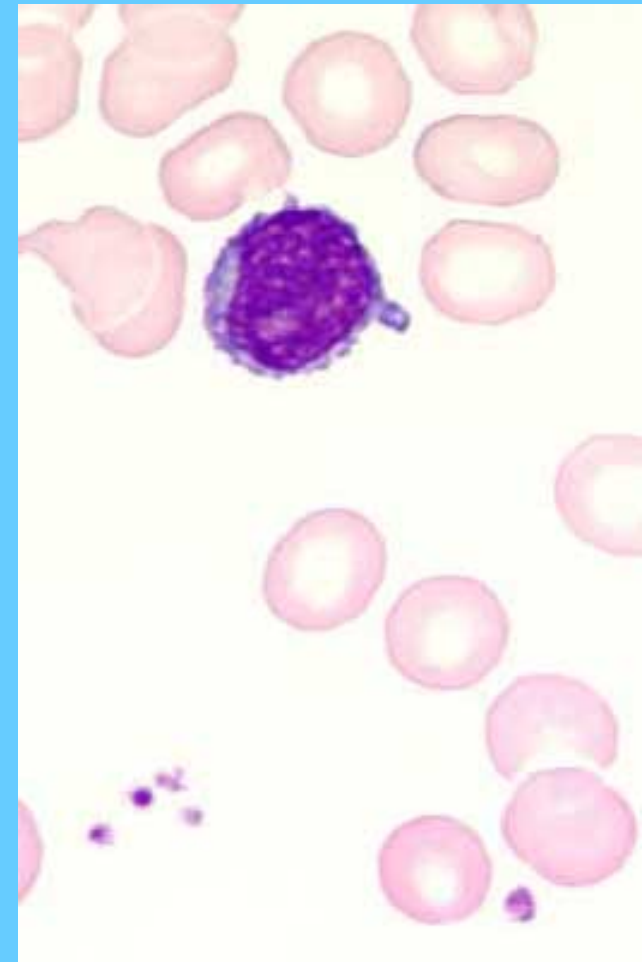
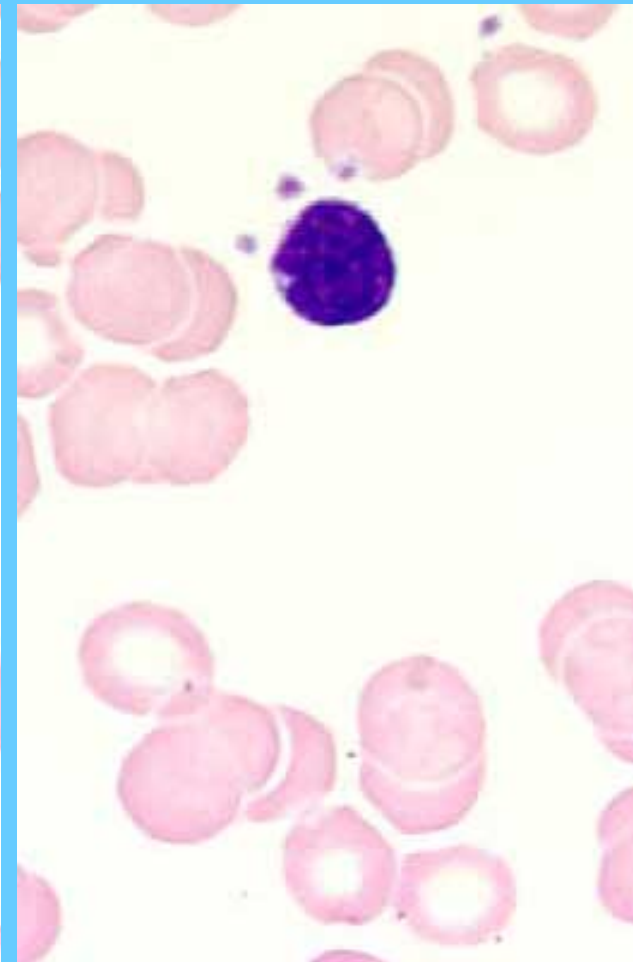
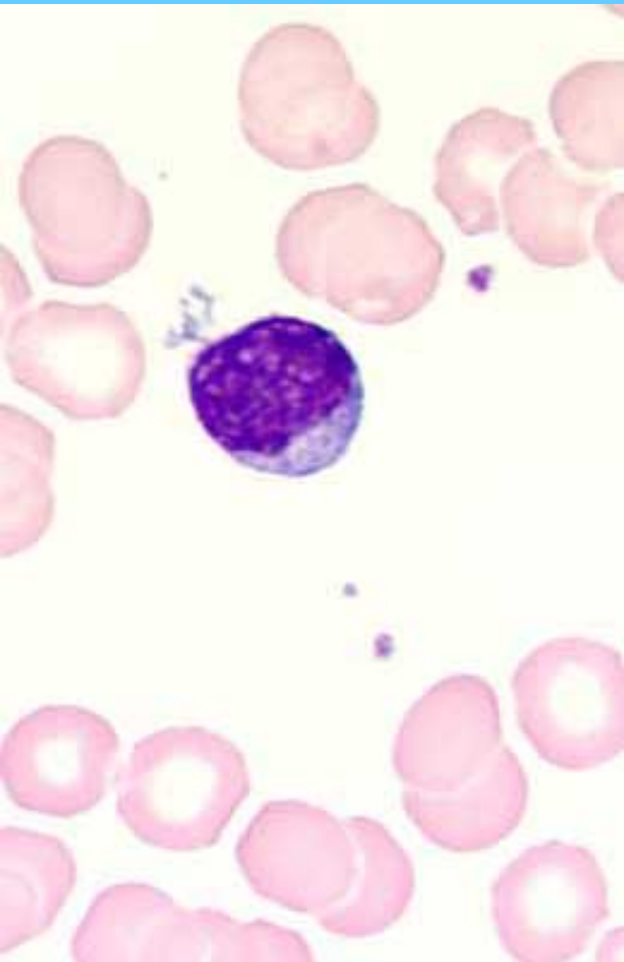Linfocitos



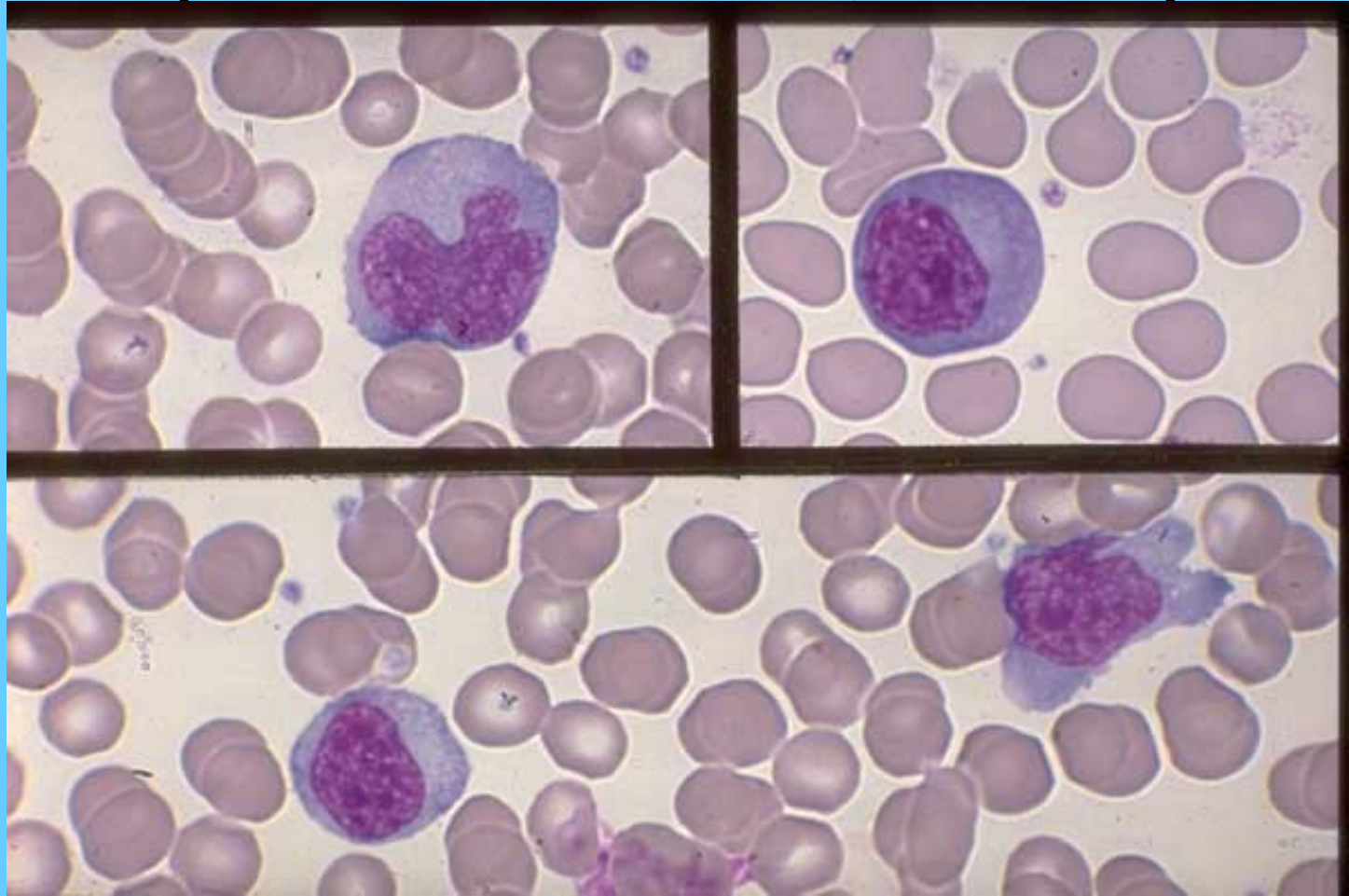
Linfocitos



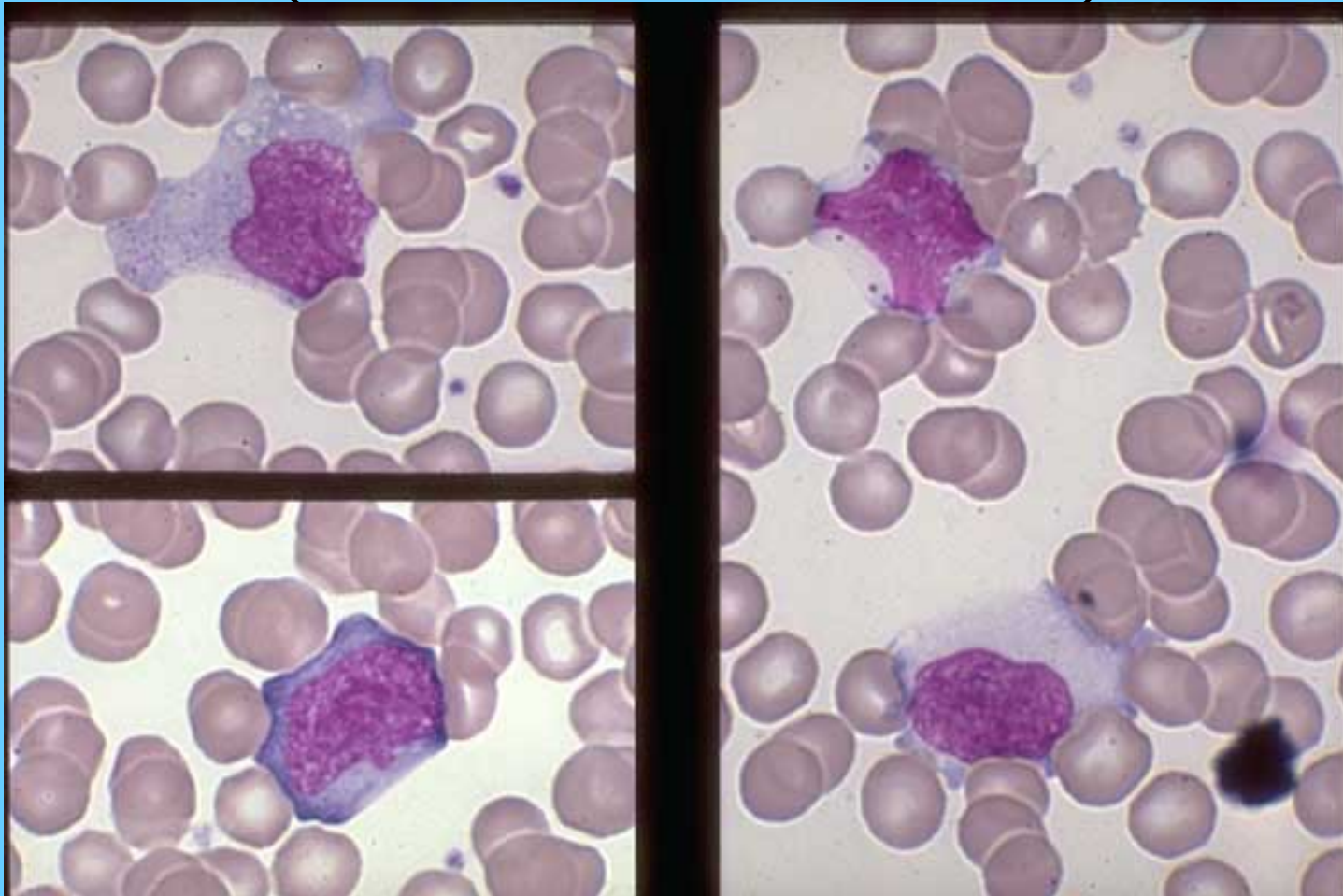
Linfocitos



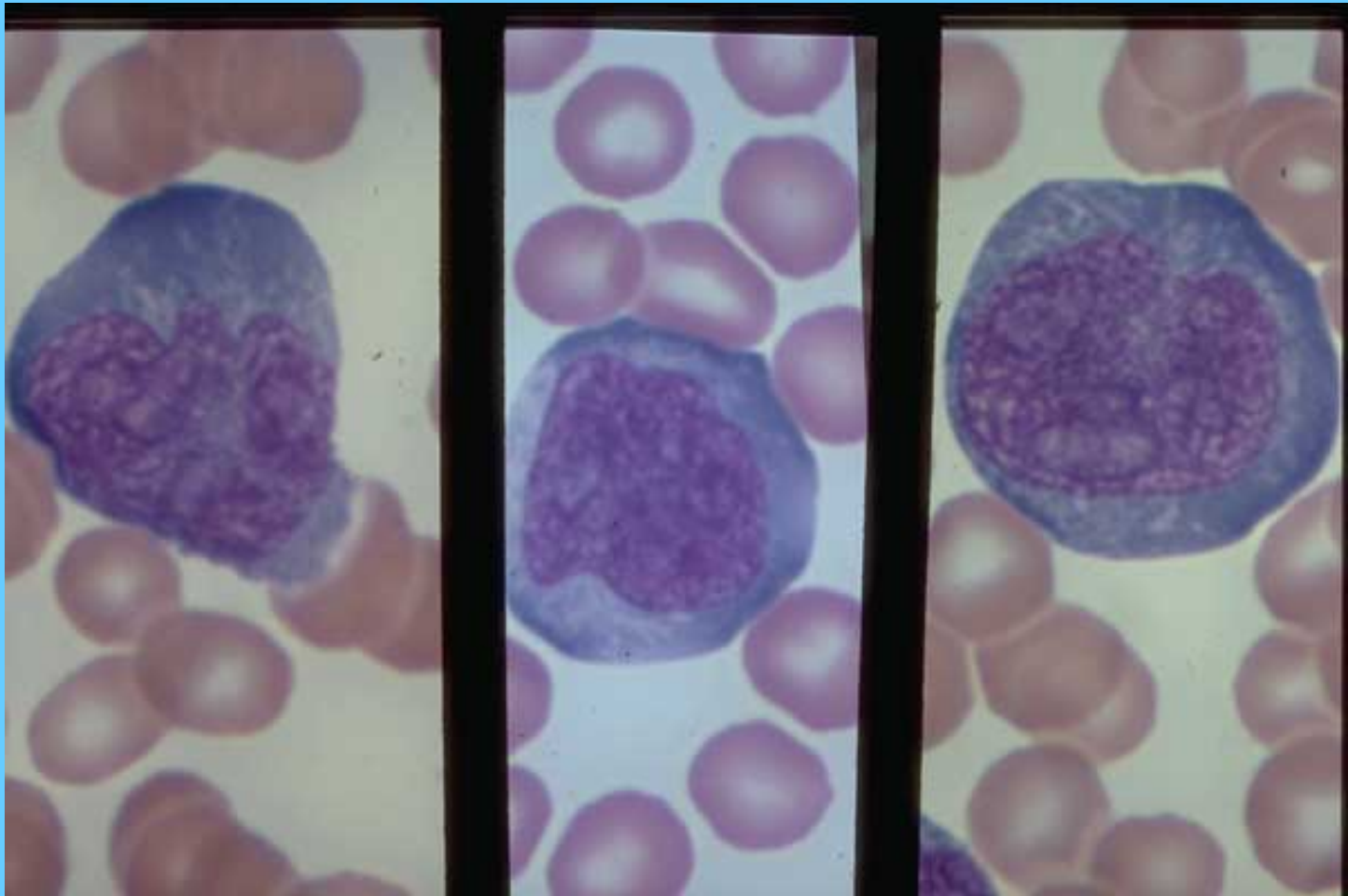
LINFOCITOS ACTIVADOS (INFECCIÓN VIRAL)



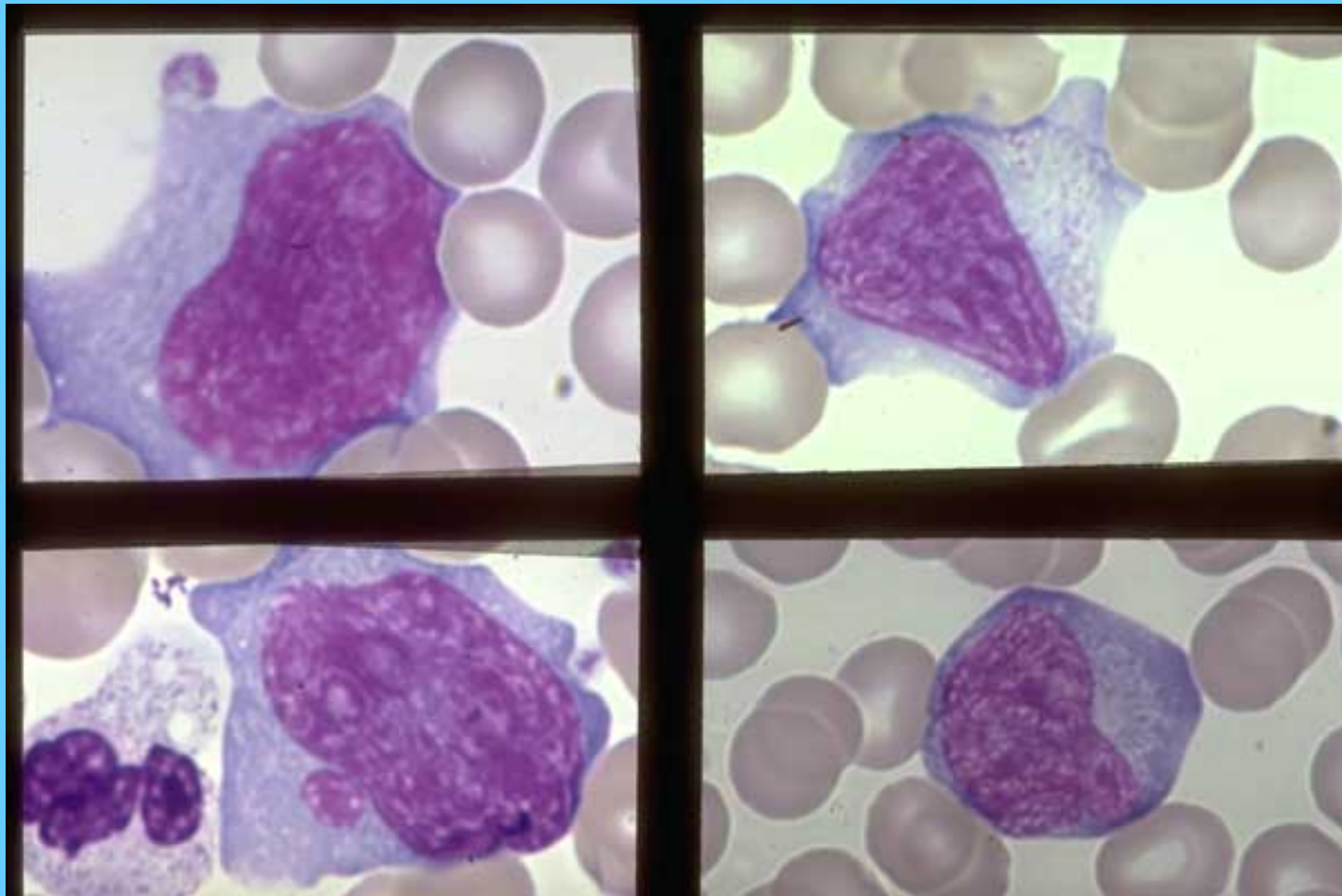
UN MONOCITO Y TRES LINFOCITOS ACTIVADOS (INFECCIÓN VIRAL)



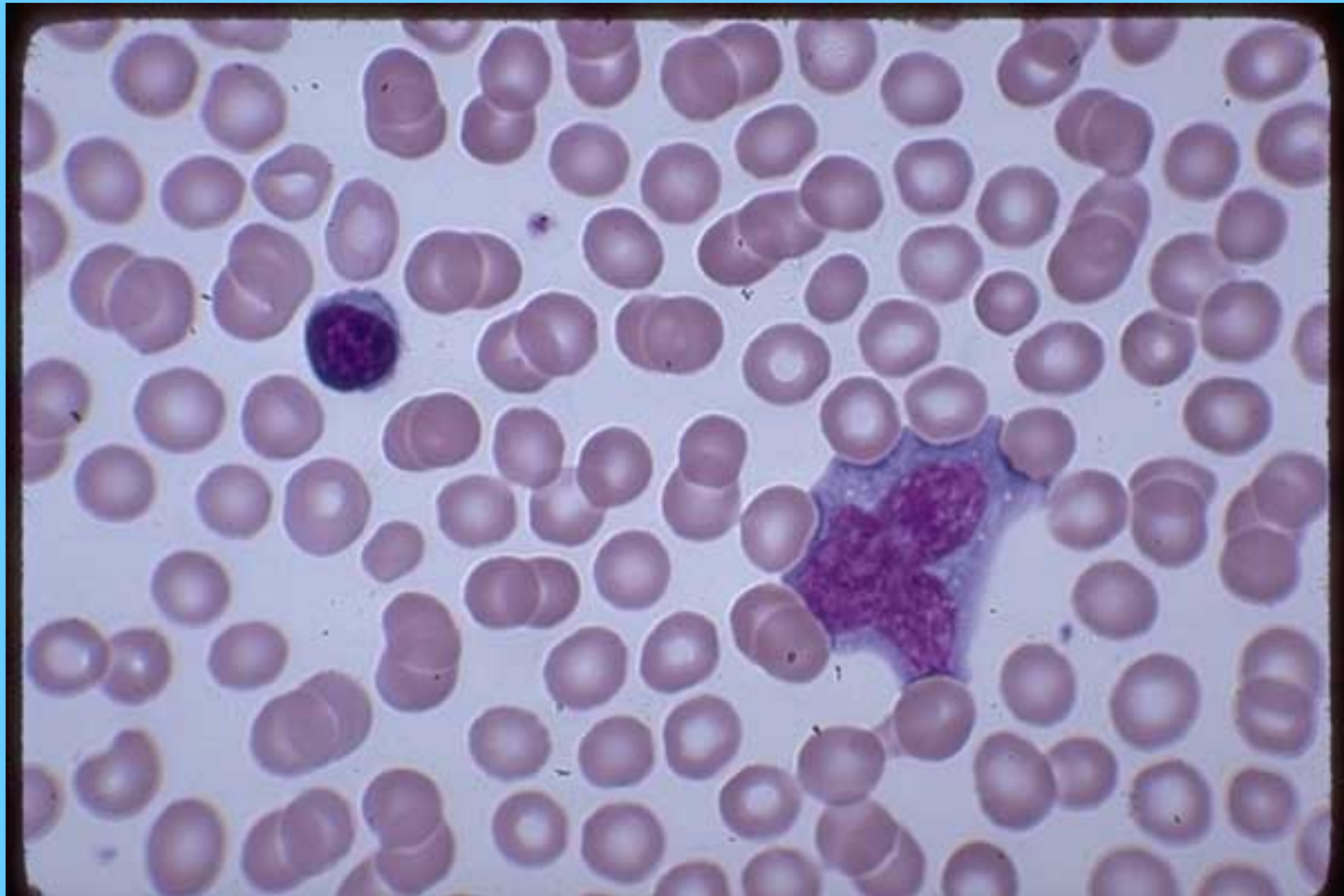
LINFOCITOS ACTIVADOS (INFECCIÓN VIRAL O BACTERIANA)



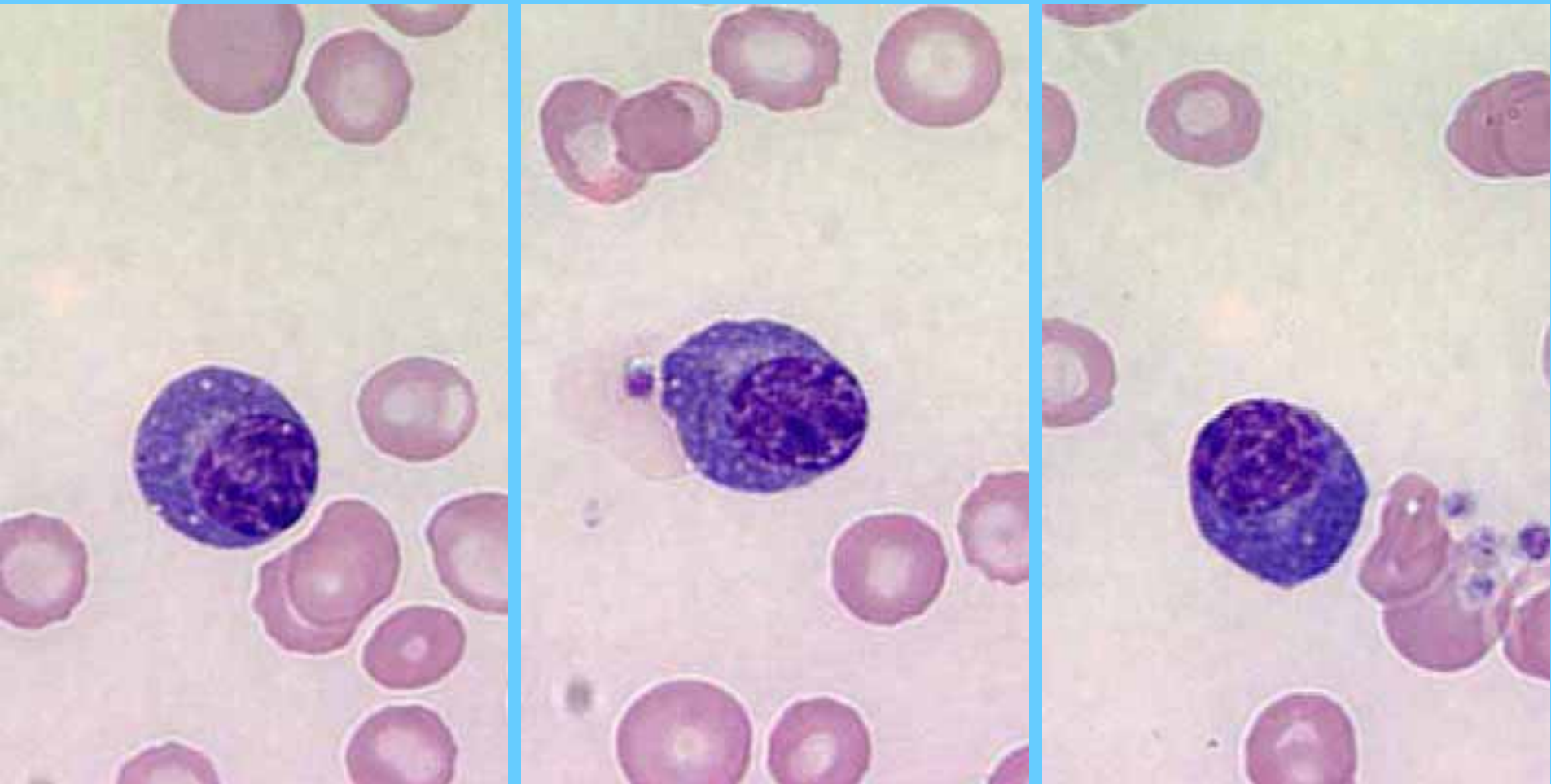
LINFOCITOS REACTIVOS EN INFECCIÓN VIRAL



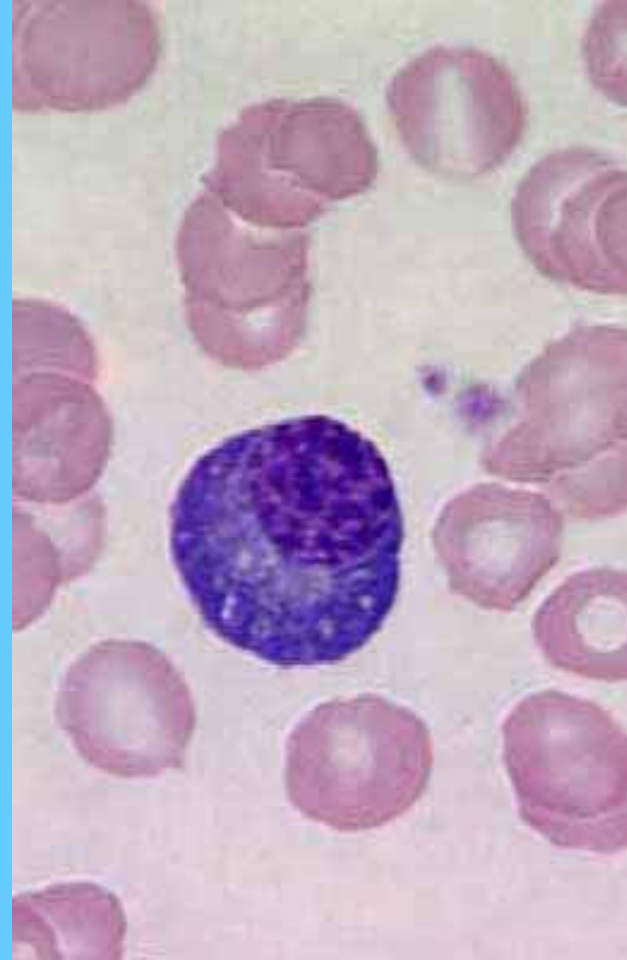
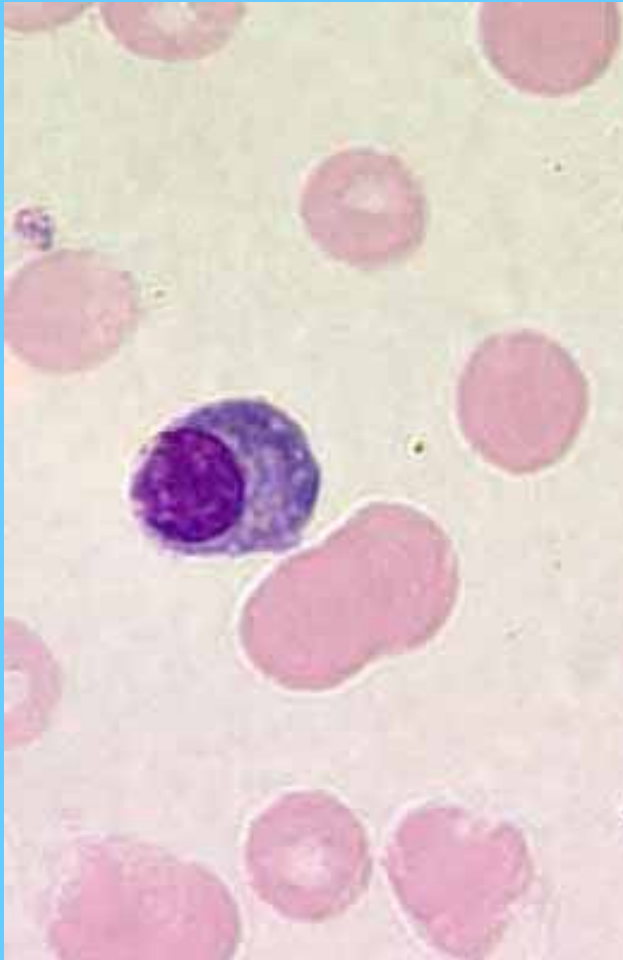
LINFOCITO ATÍPICO DE LA MONONUCLEOSIS INFECCIOSA



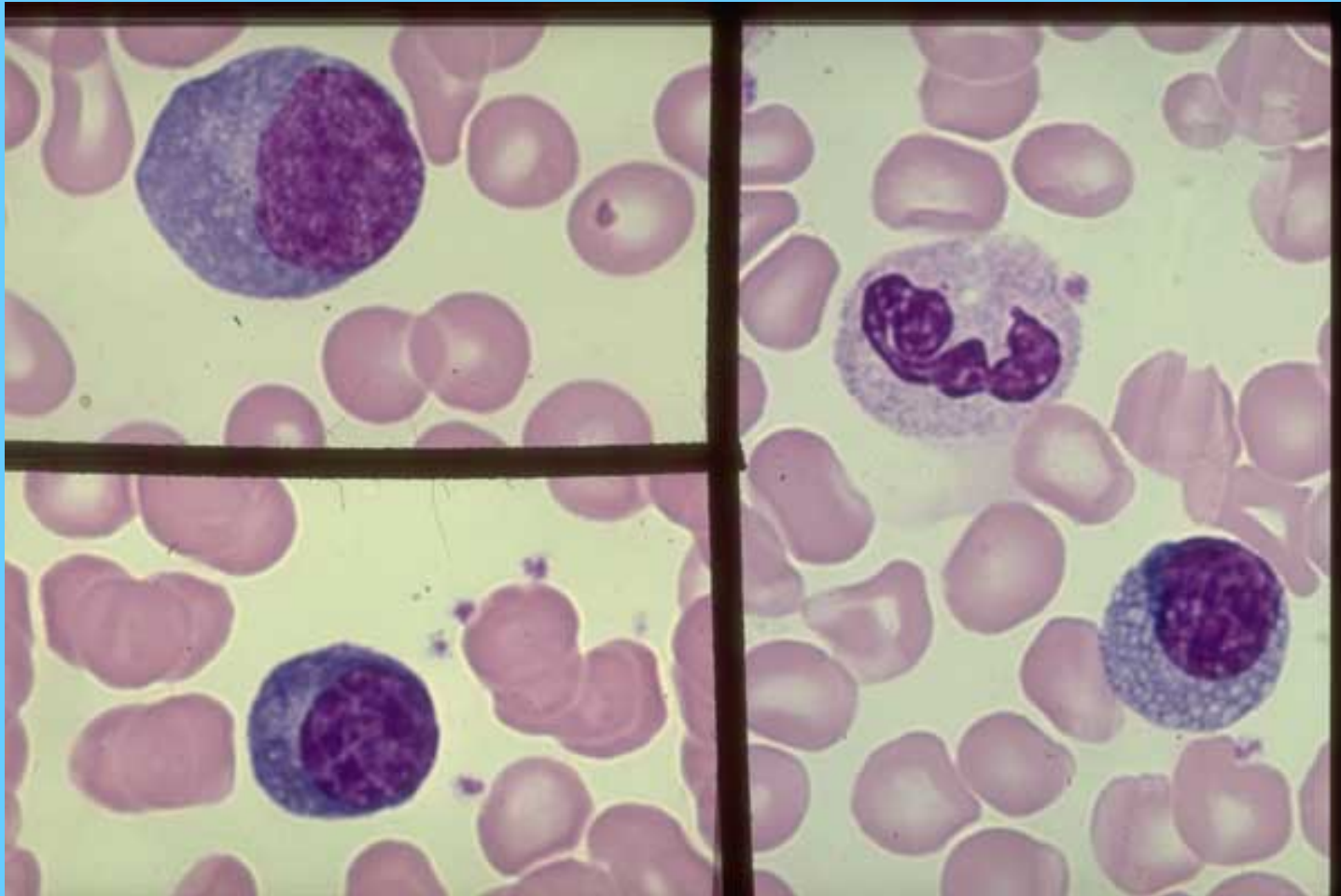
Células plasmáticas



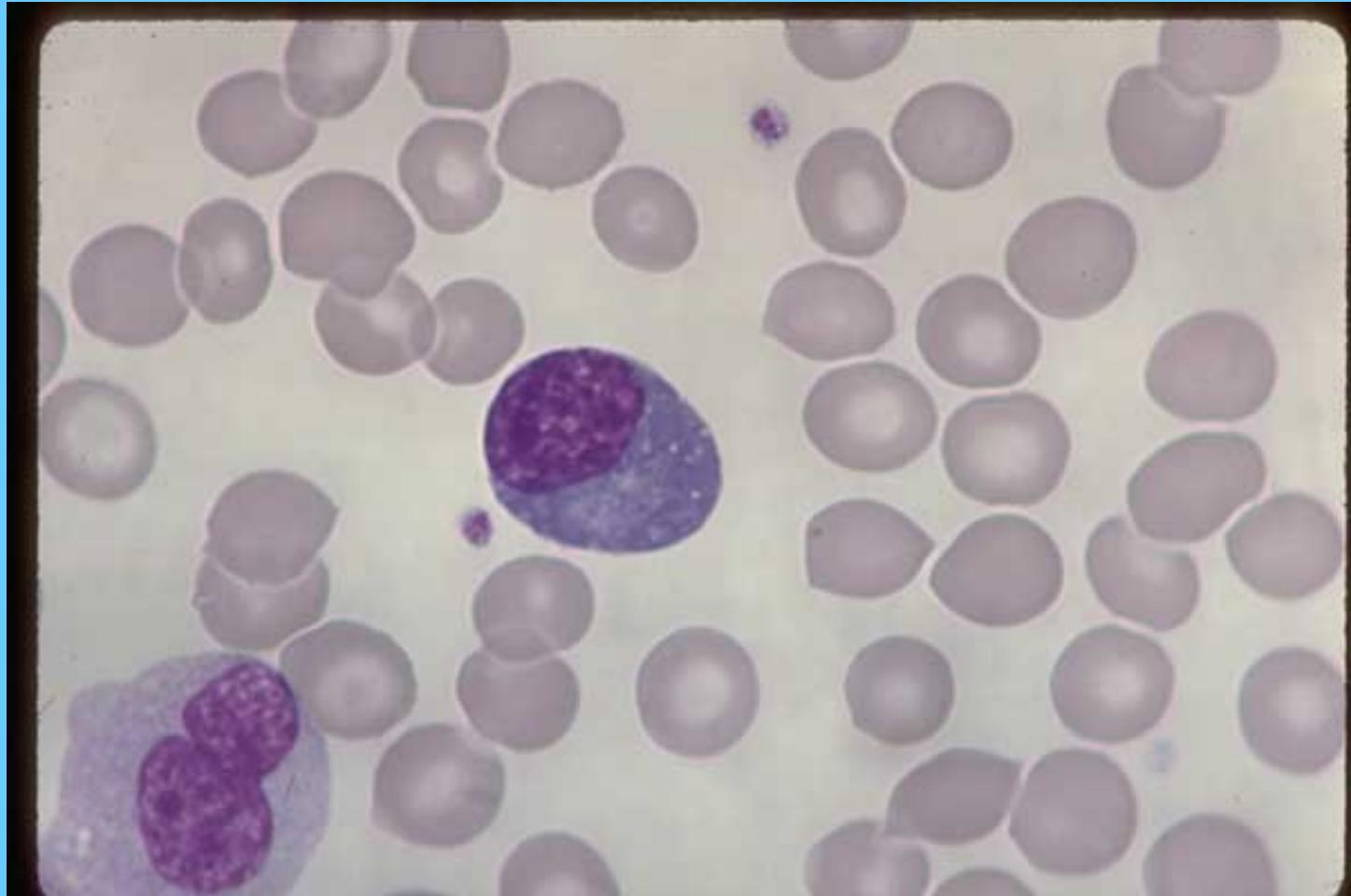
Células plasmáticas



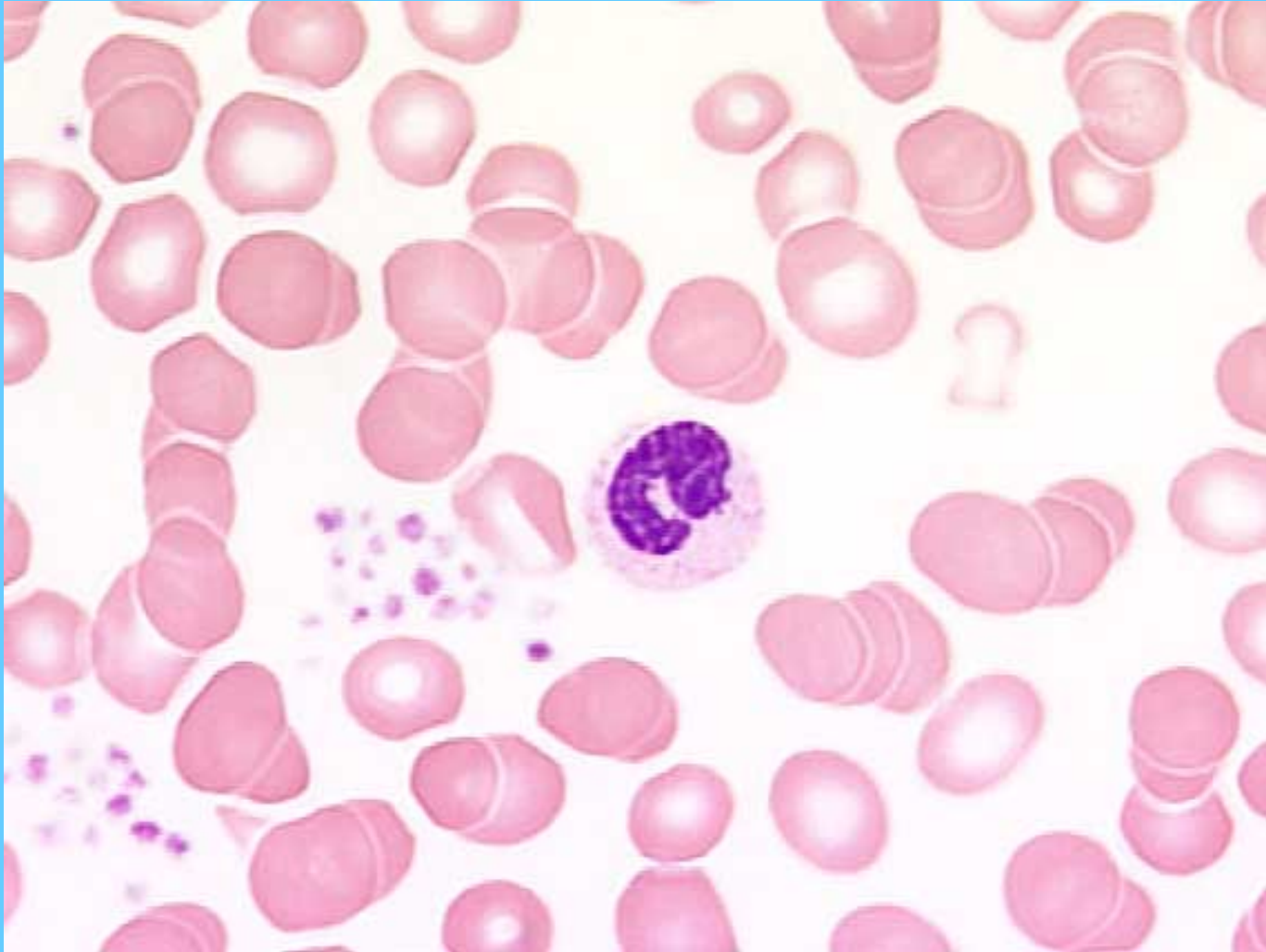
CÉLULAS PLASMÁTICAS EN UN CASO DE ARTRITIS SEVERA CON OSTEOPOROSIS



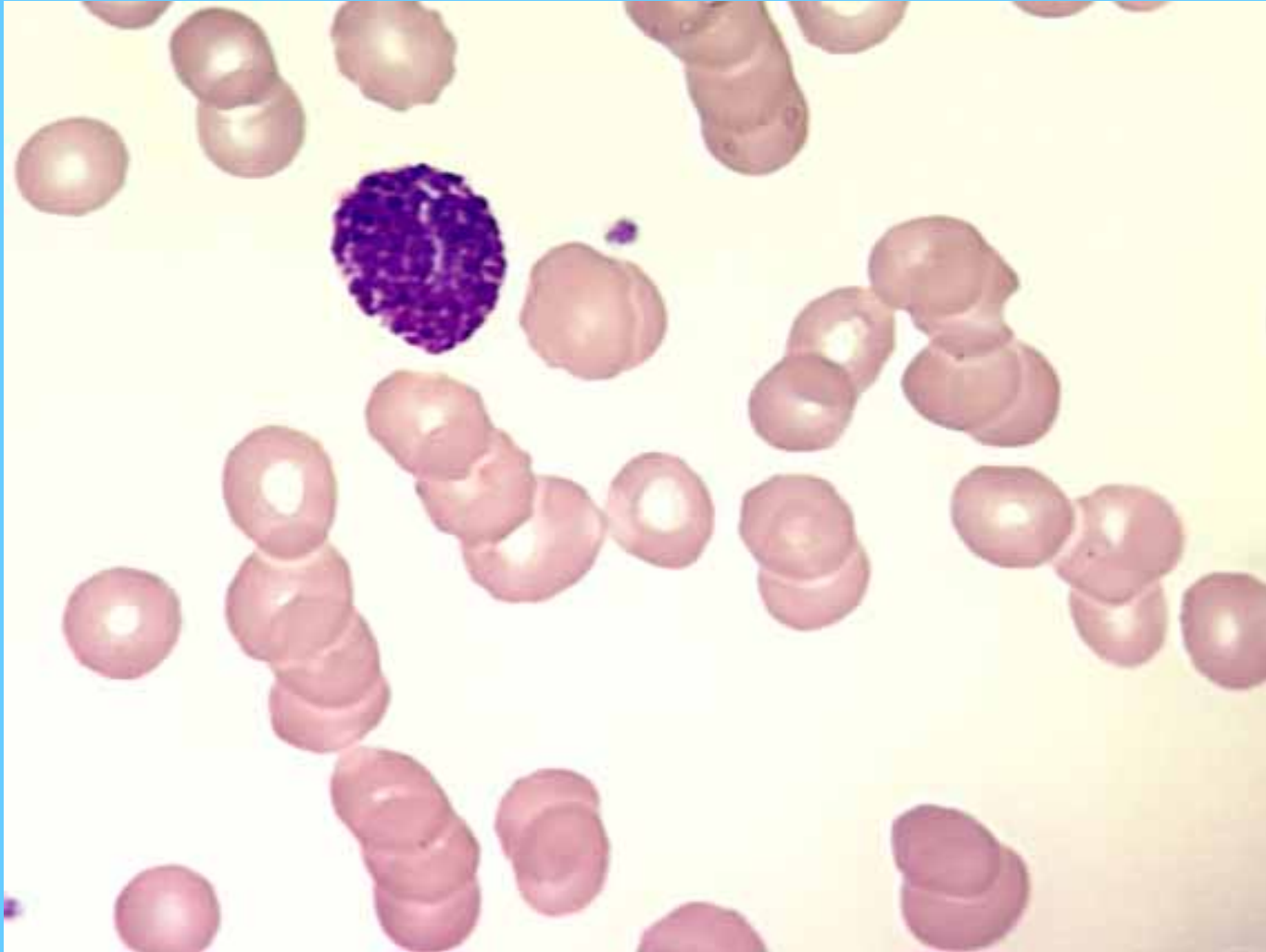
CÉLULA PLASMÁTICA EN UN CASO DE SEPSIS

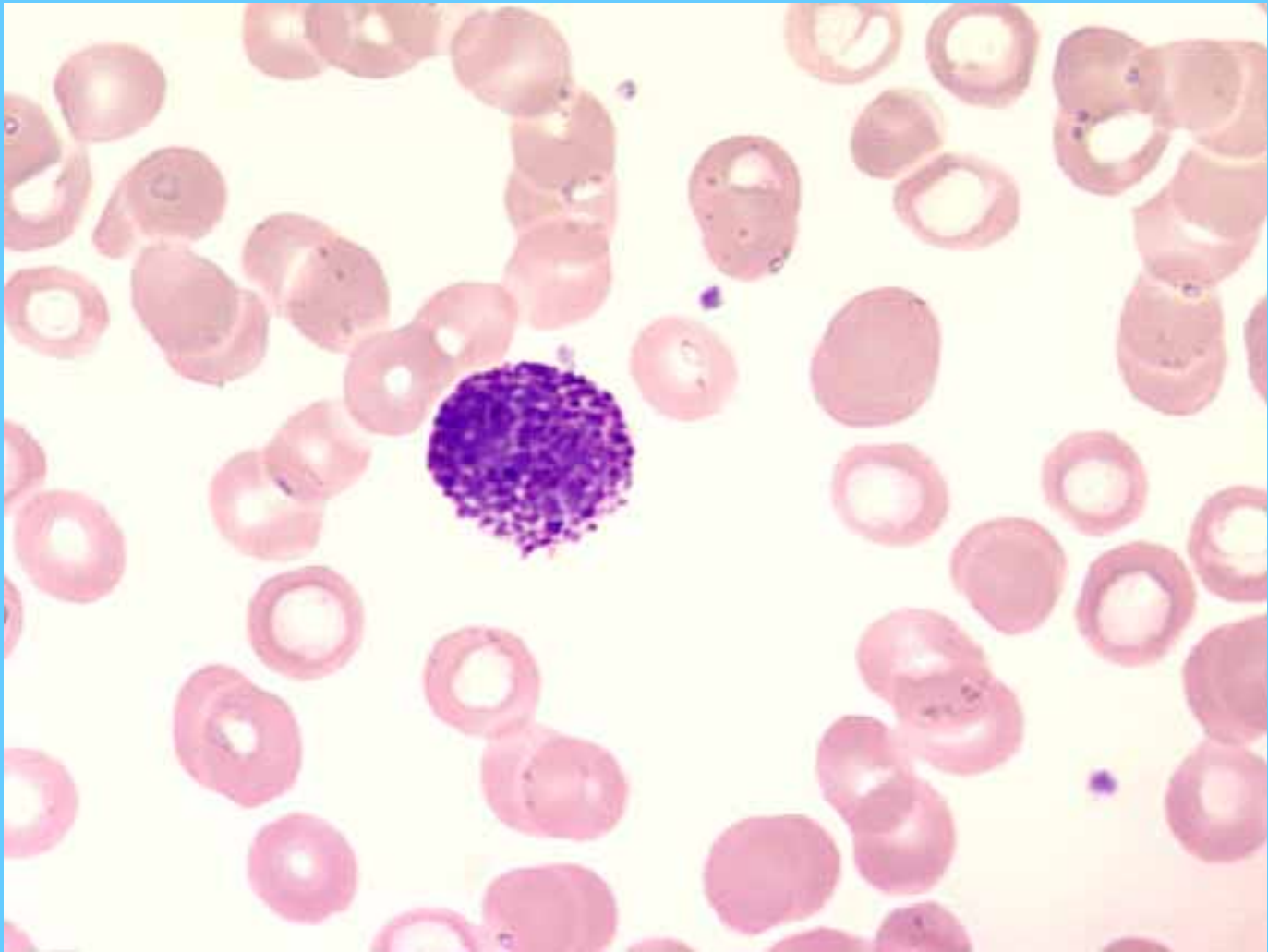


Banda

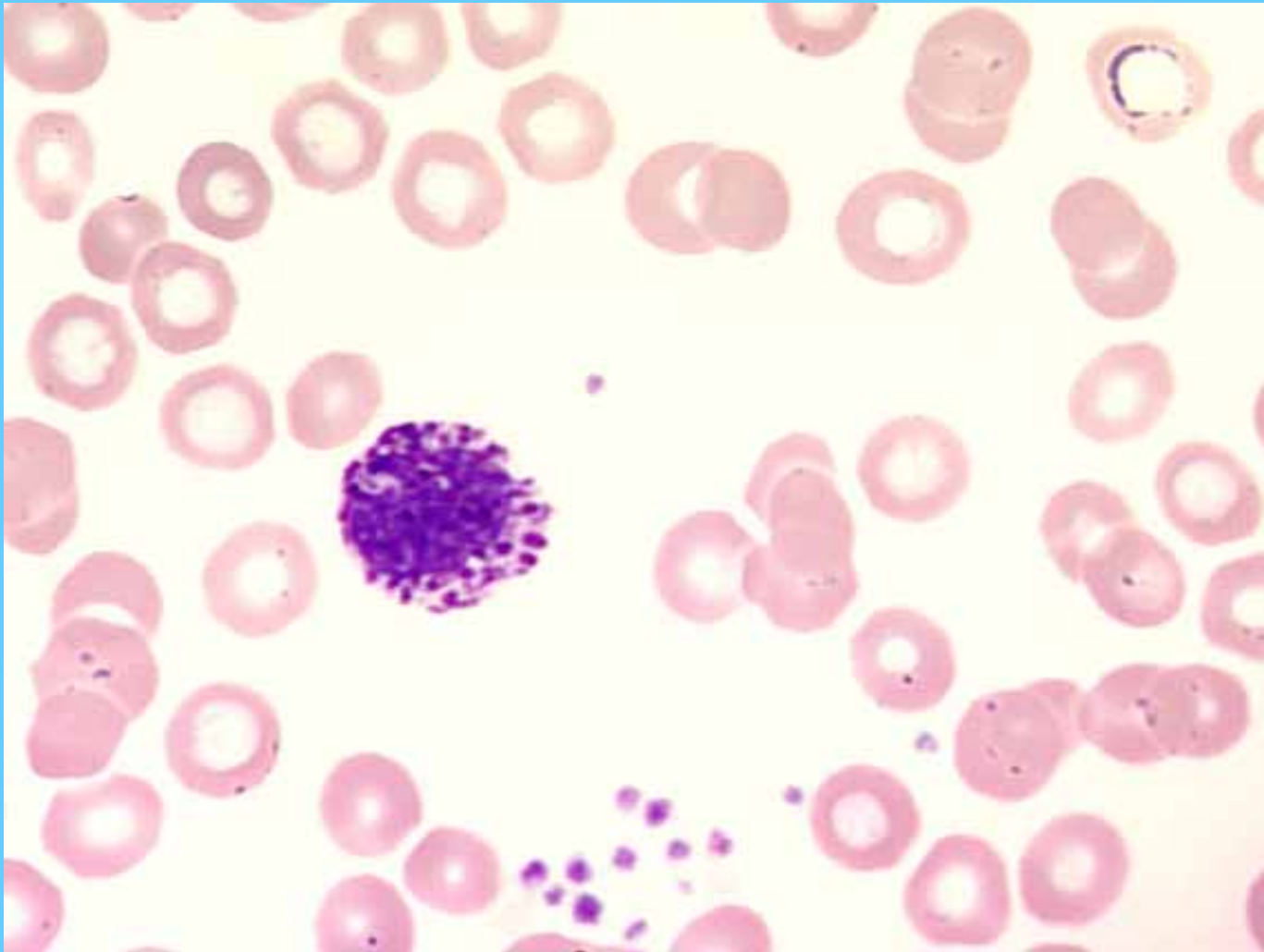


Basófilo

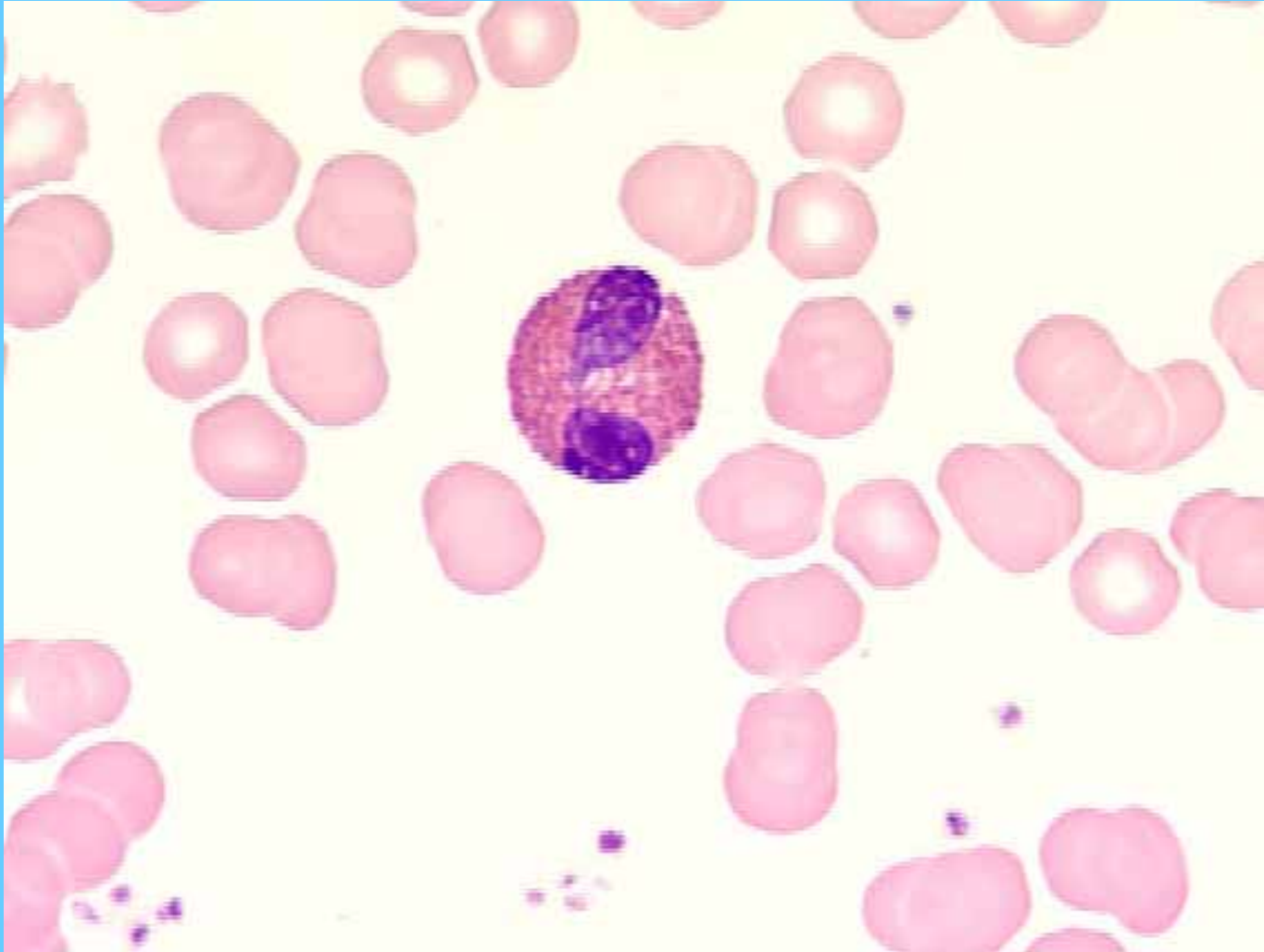




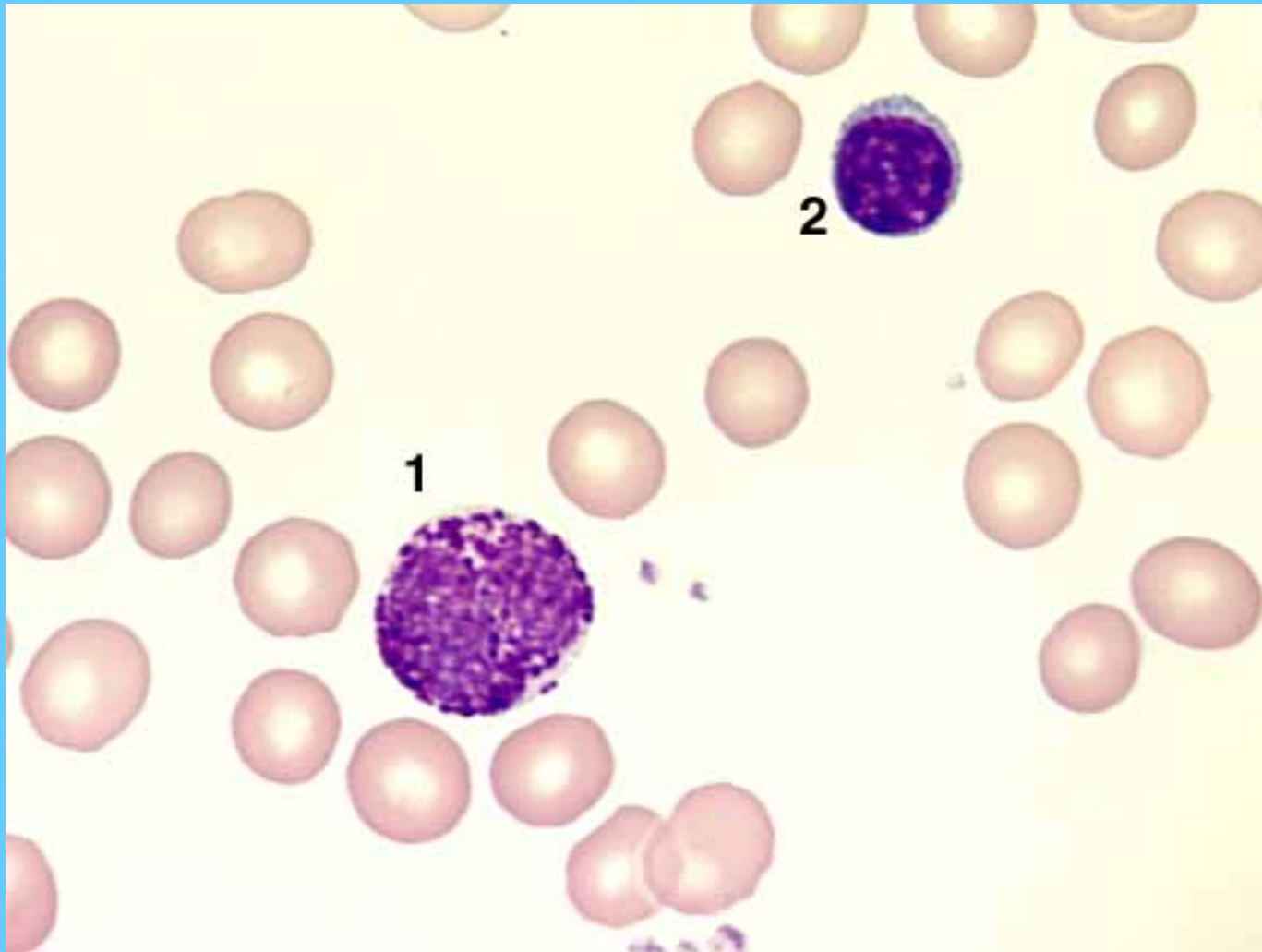
Basófilo



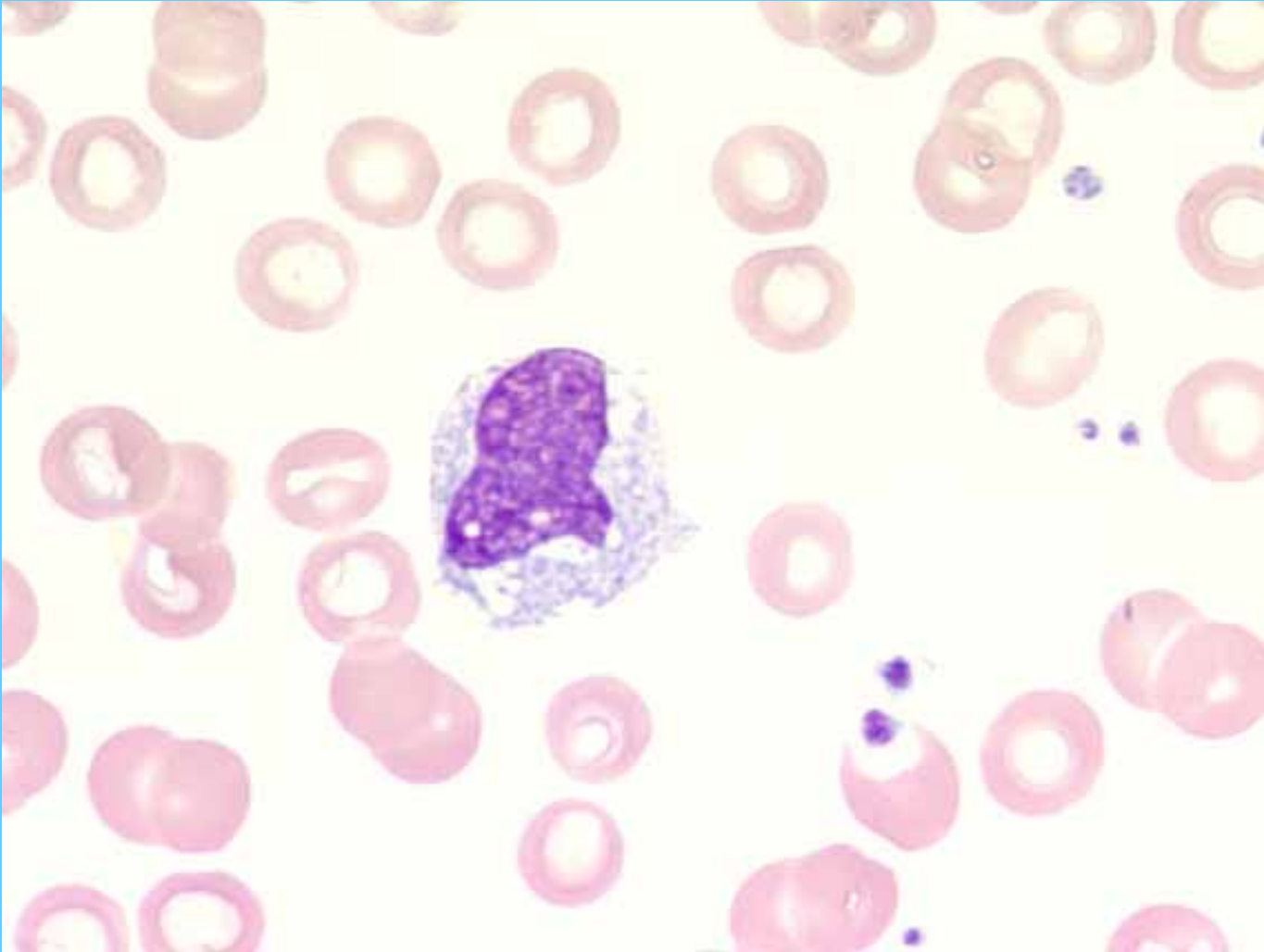
Eosinófilo

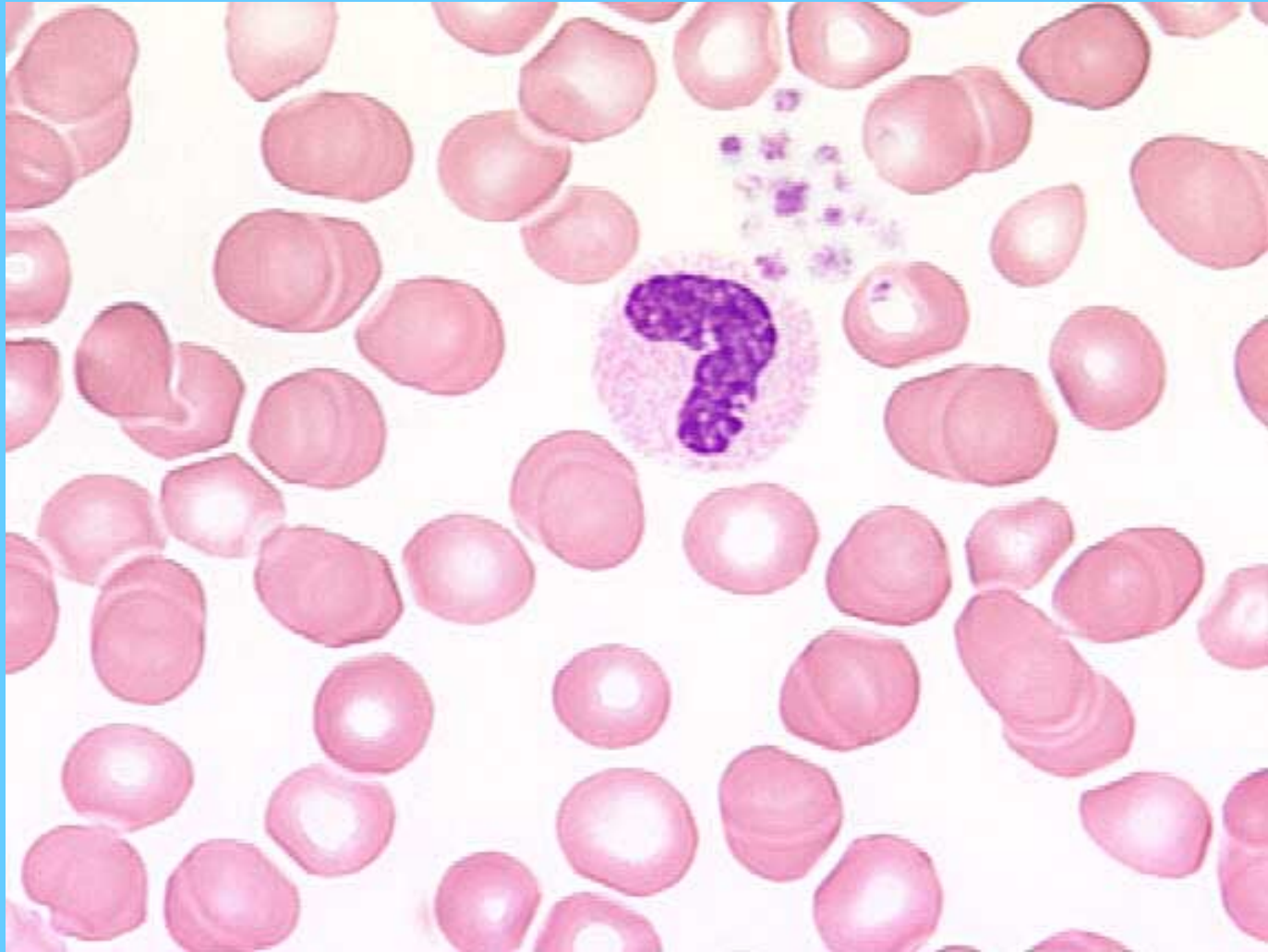


Basófilo (1), linfocito (2)

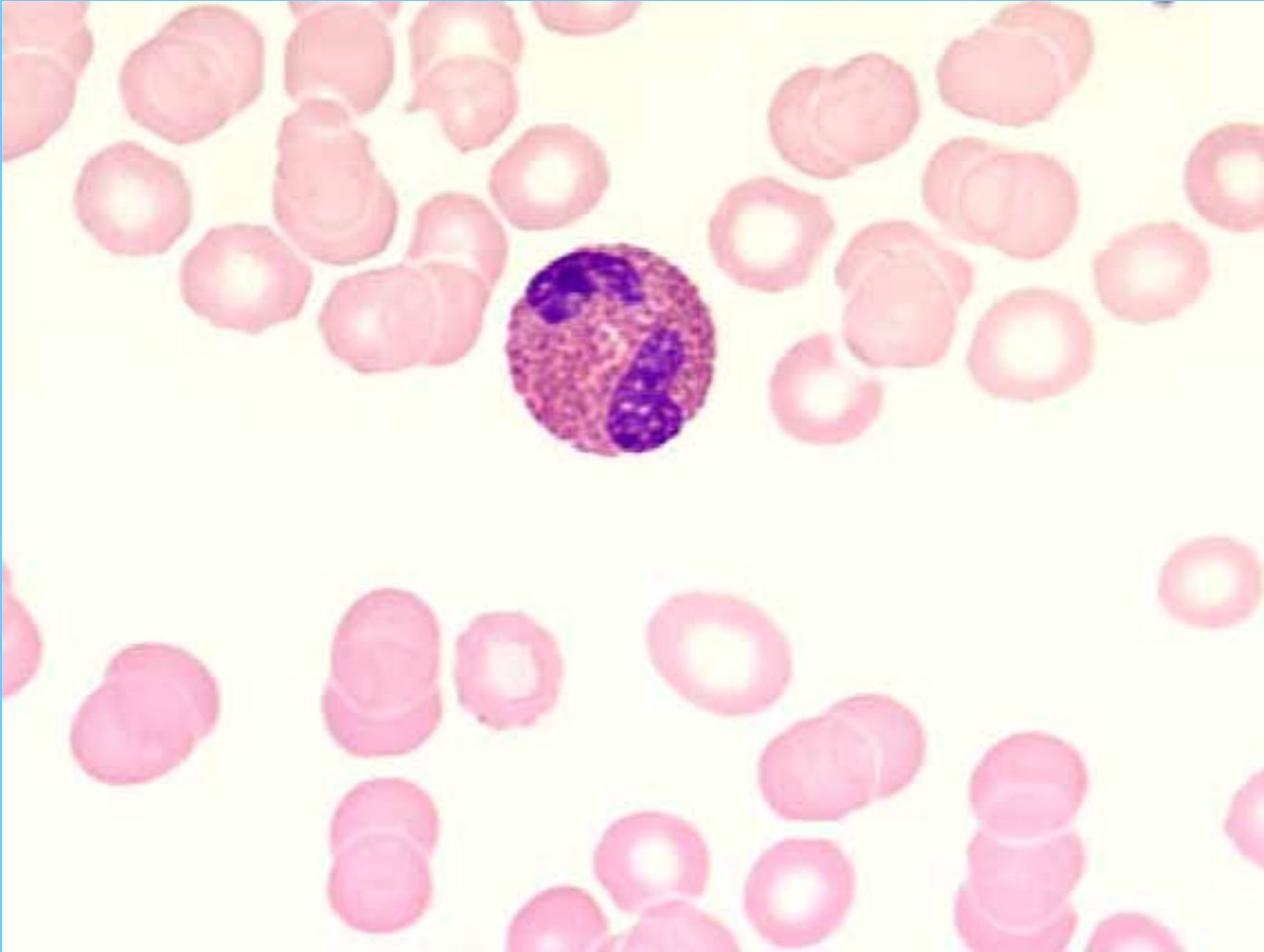


Monocito

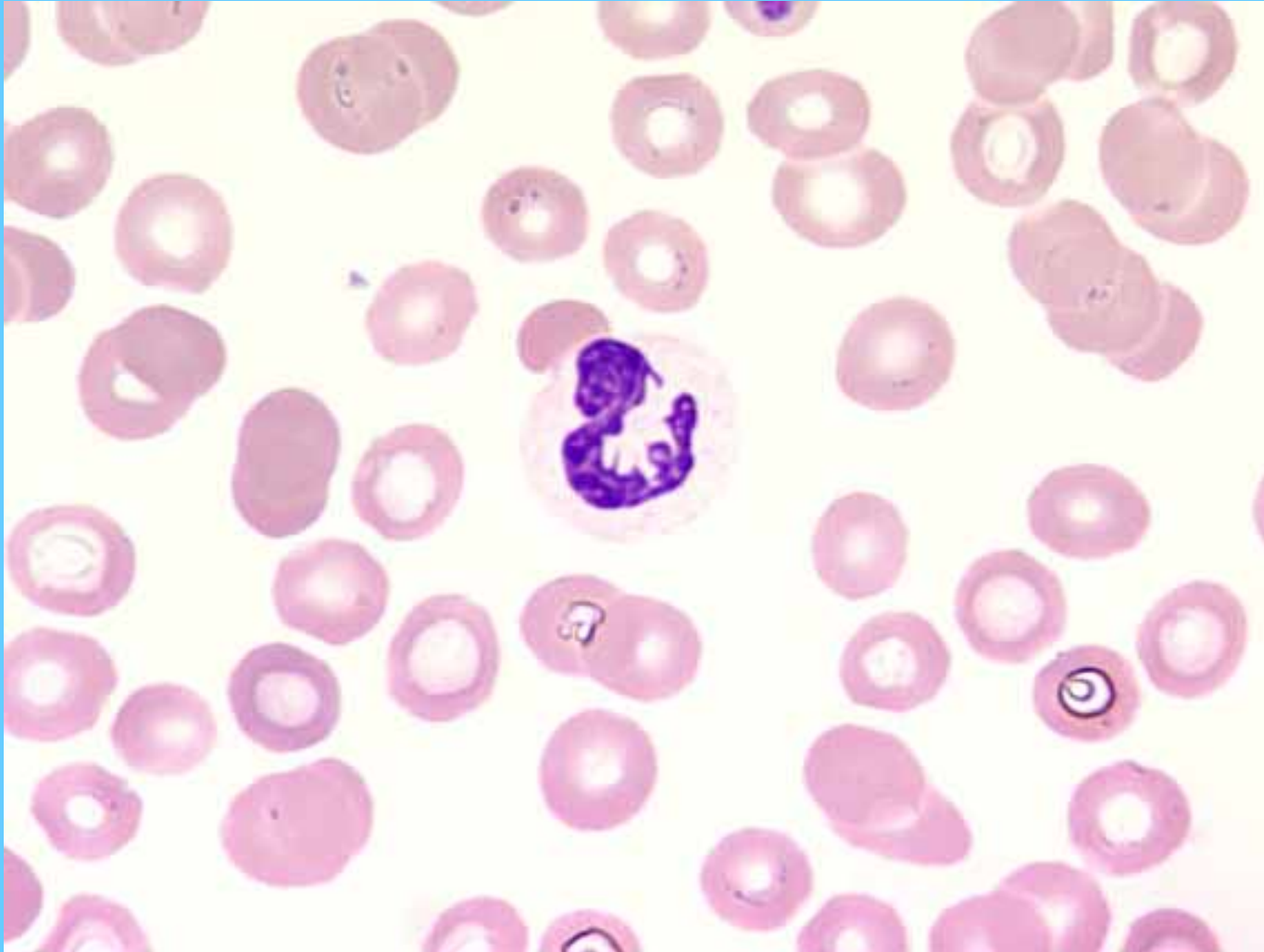



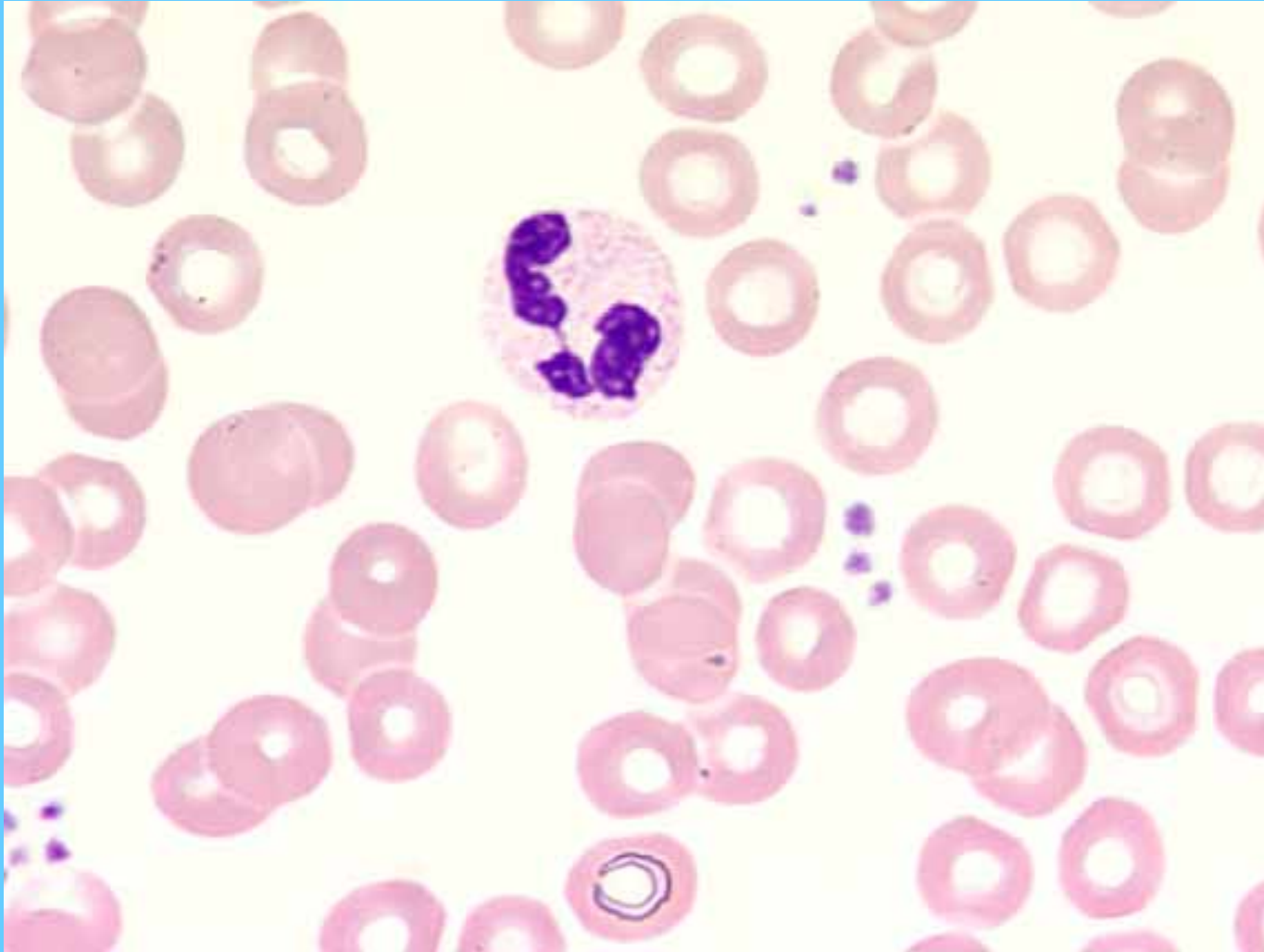
Eosinófilo



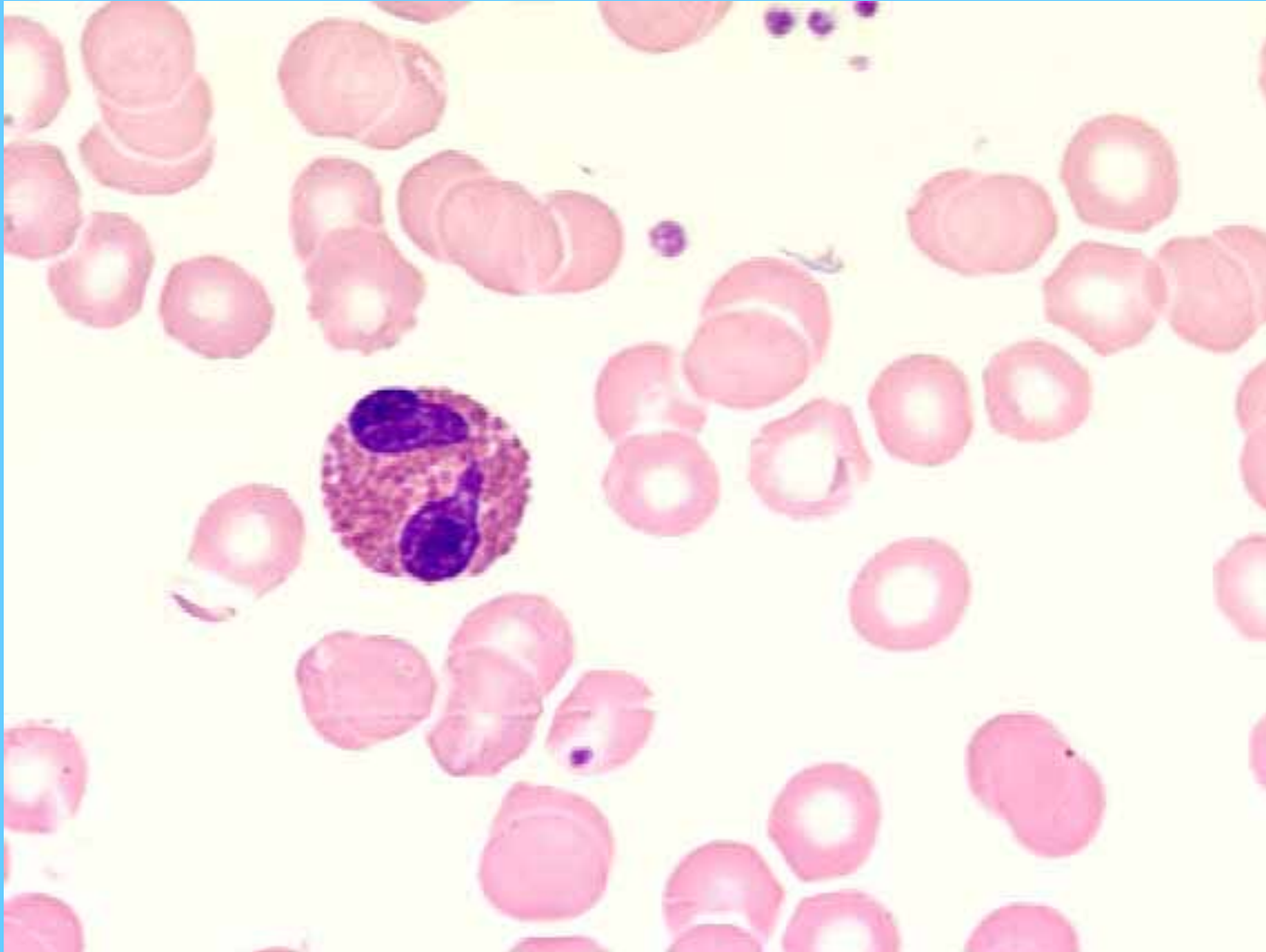
Neutrófilo segmentado



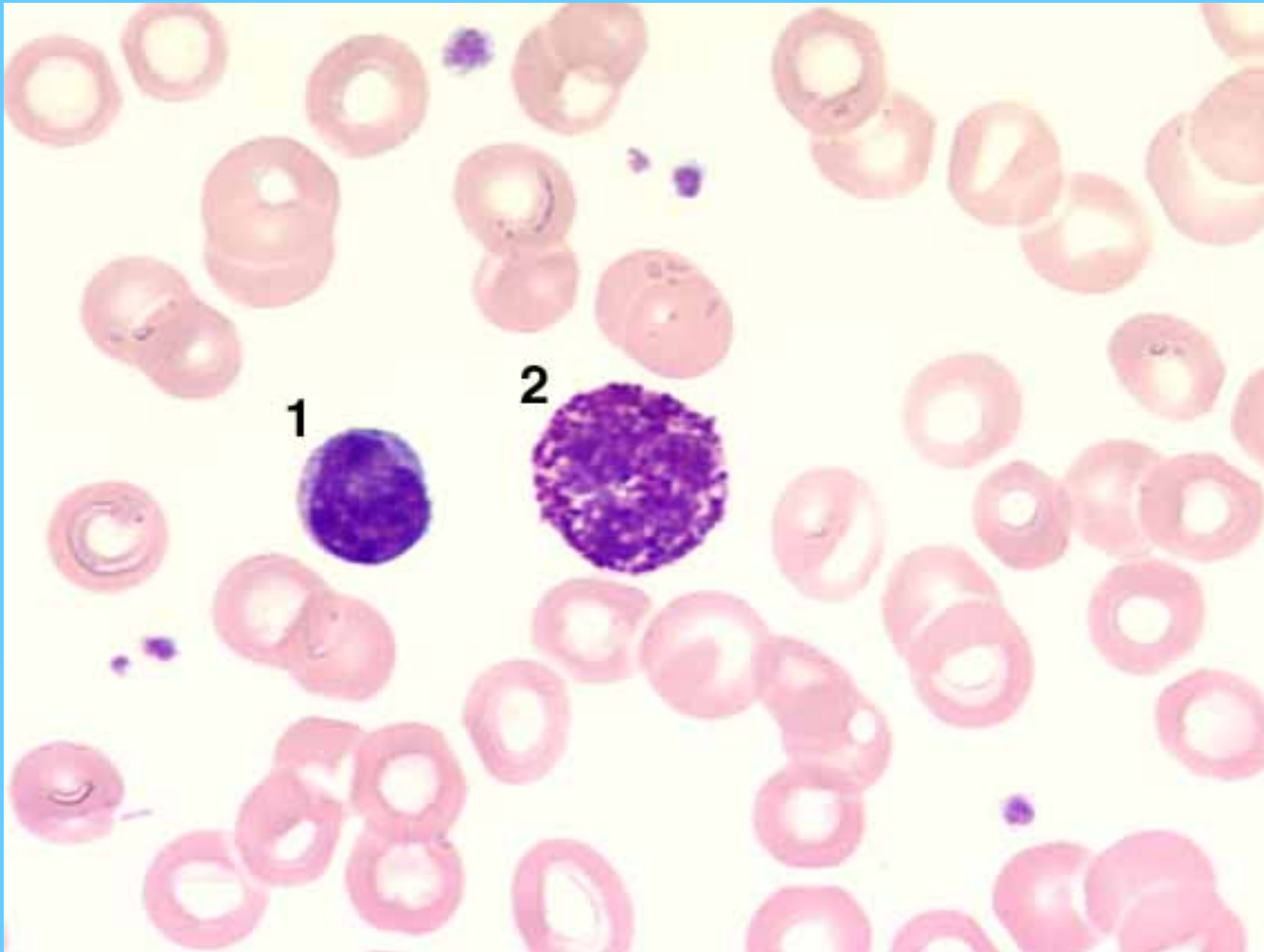
Neutrófilo segmentado



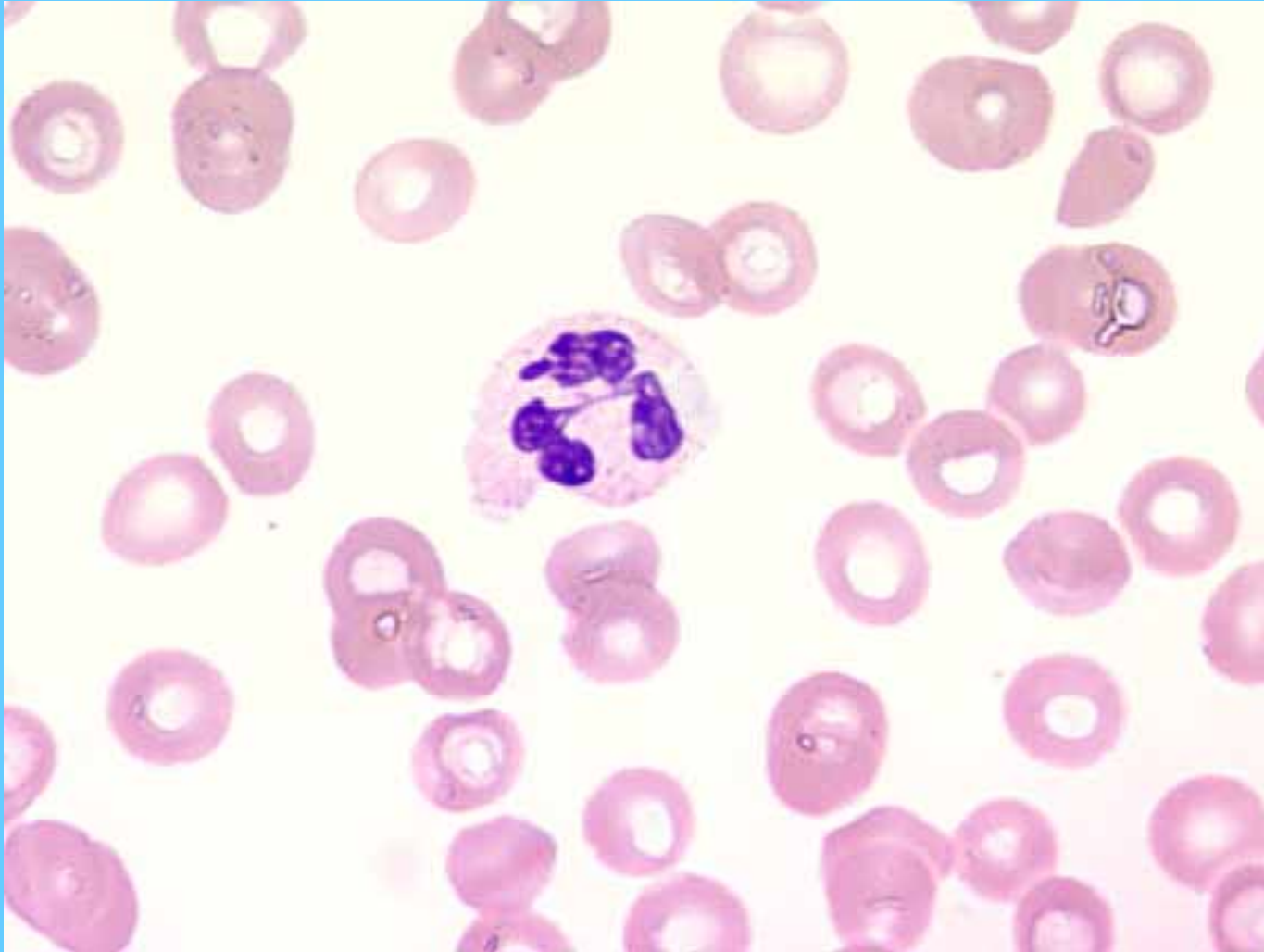
Eosinófilo



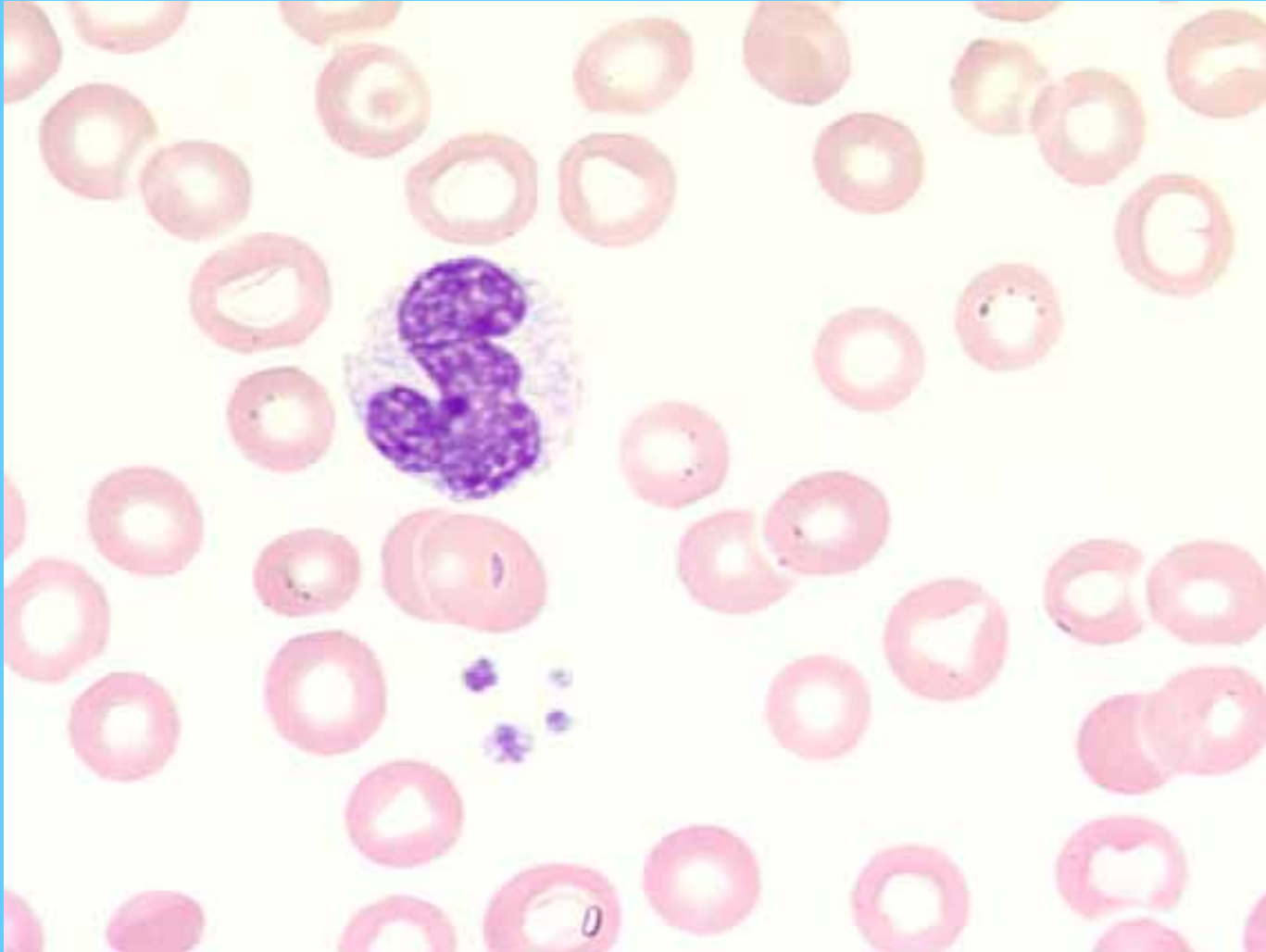
Linfocito (1), basófilo (2)



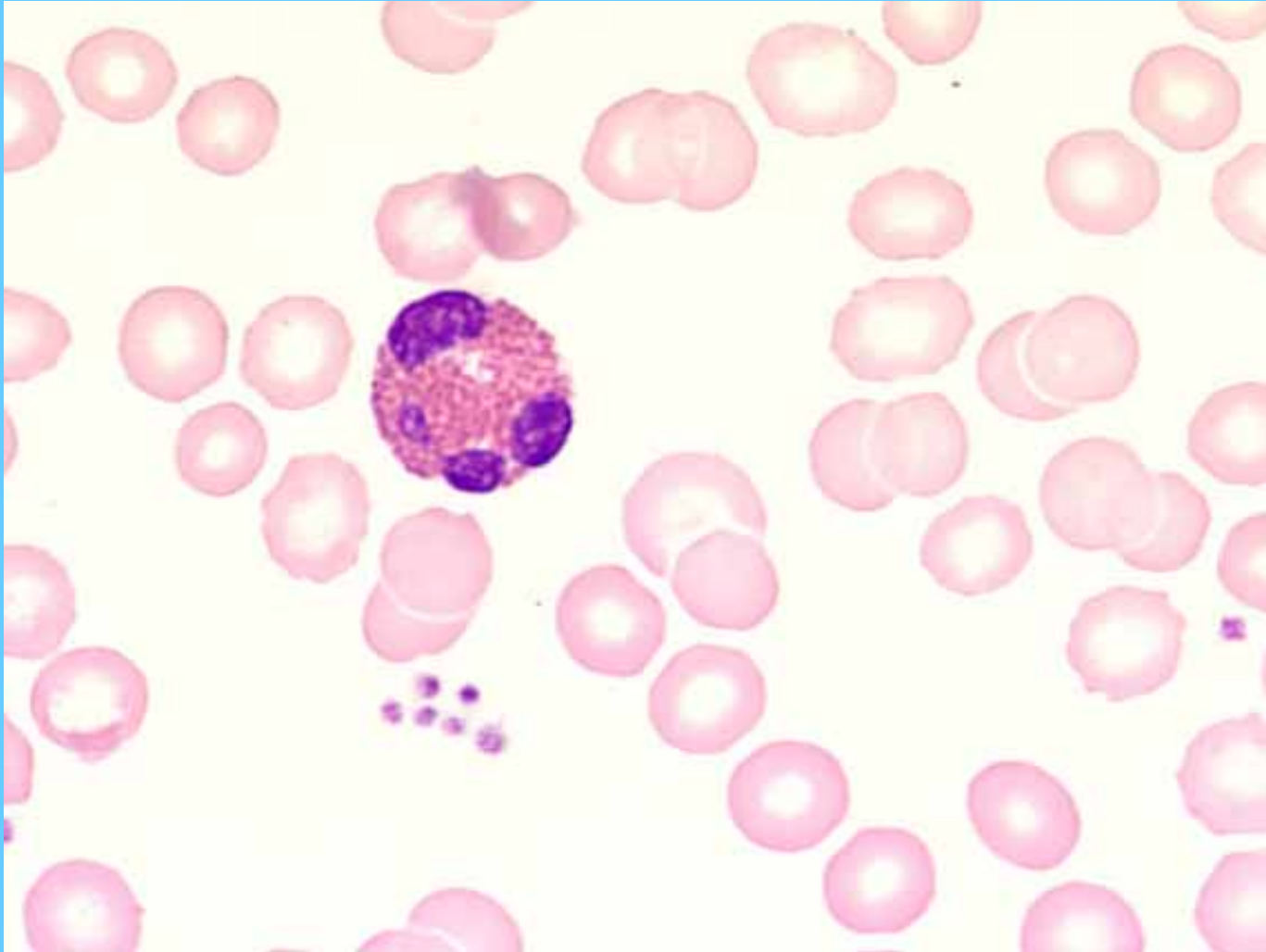
Neutrófilo segmentado



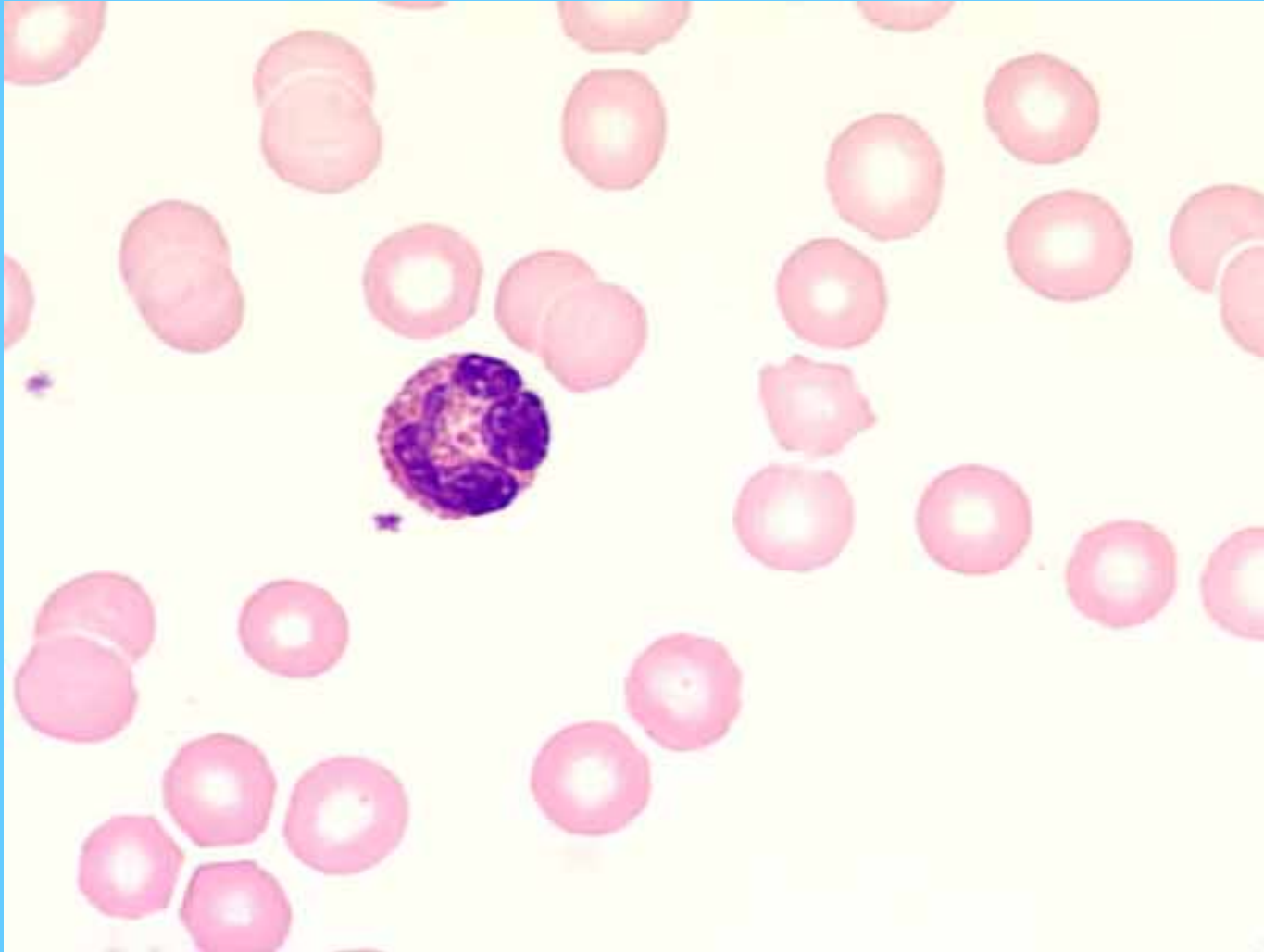
Monocito



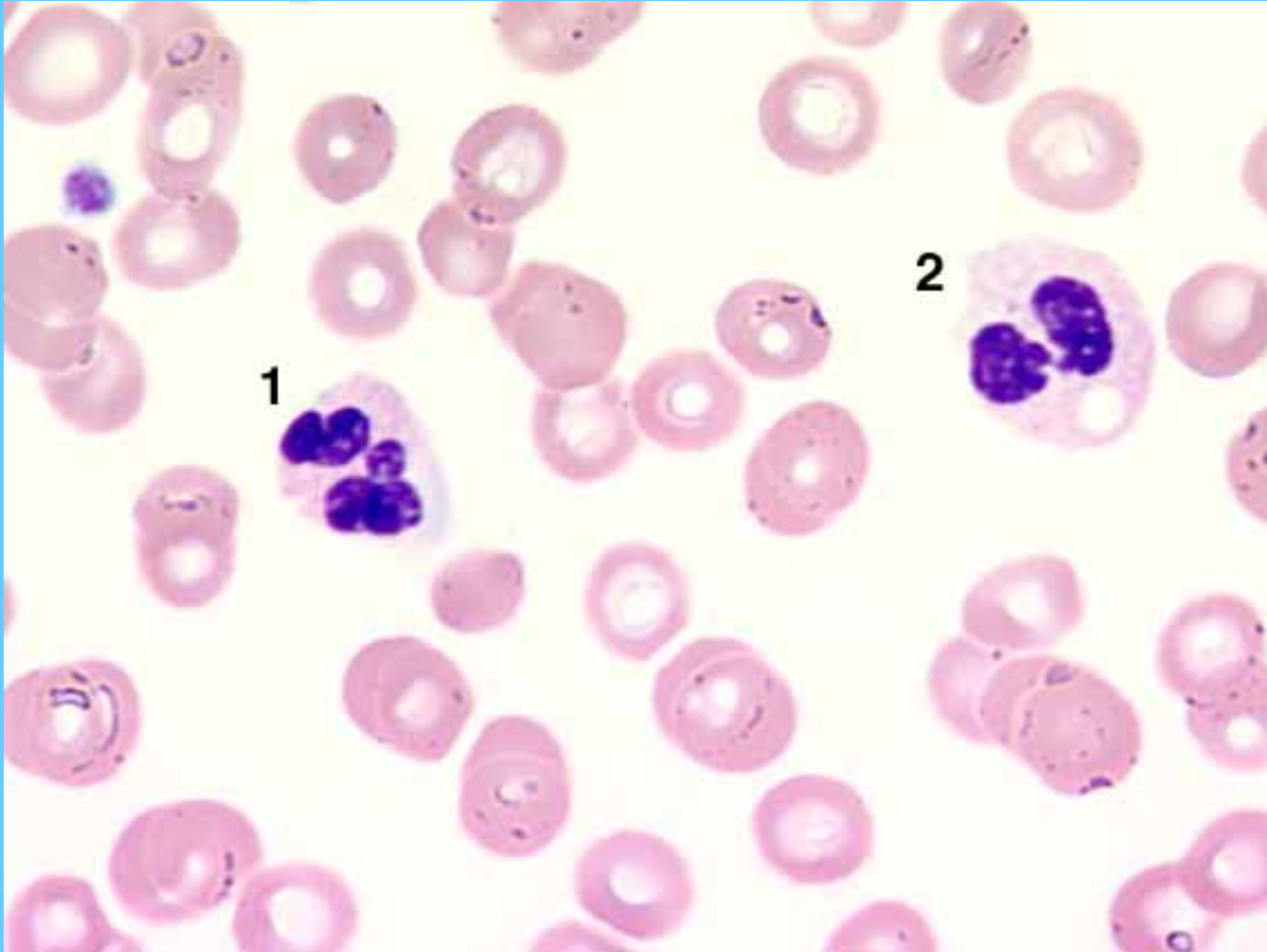
Eosinófilo



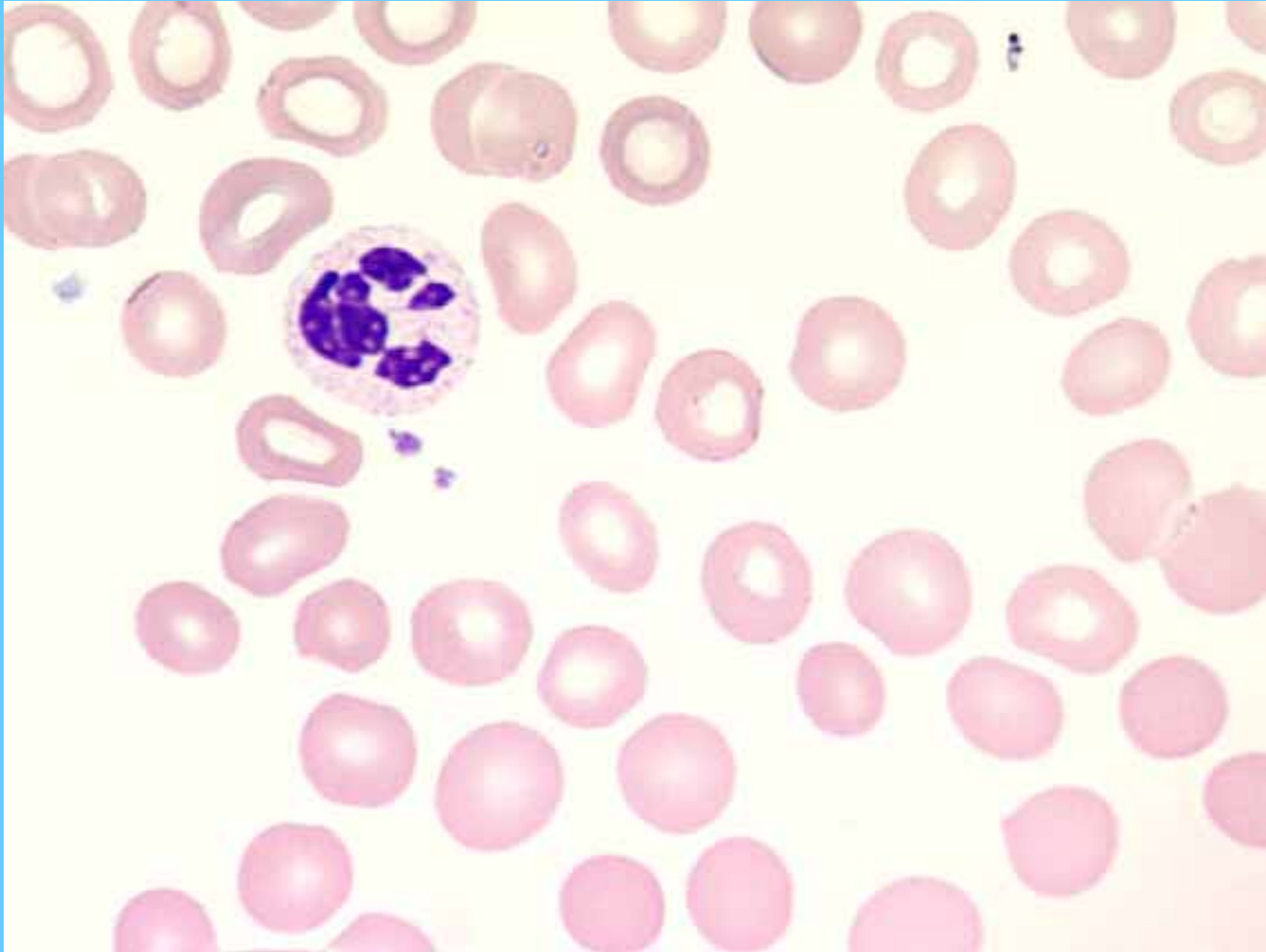
Eosinófilo



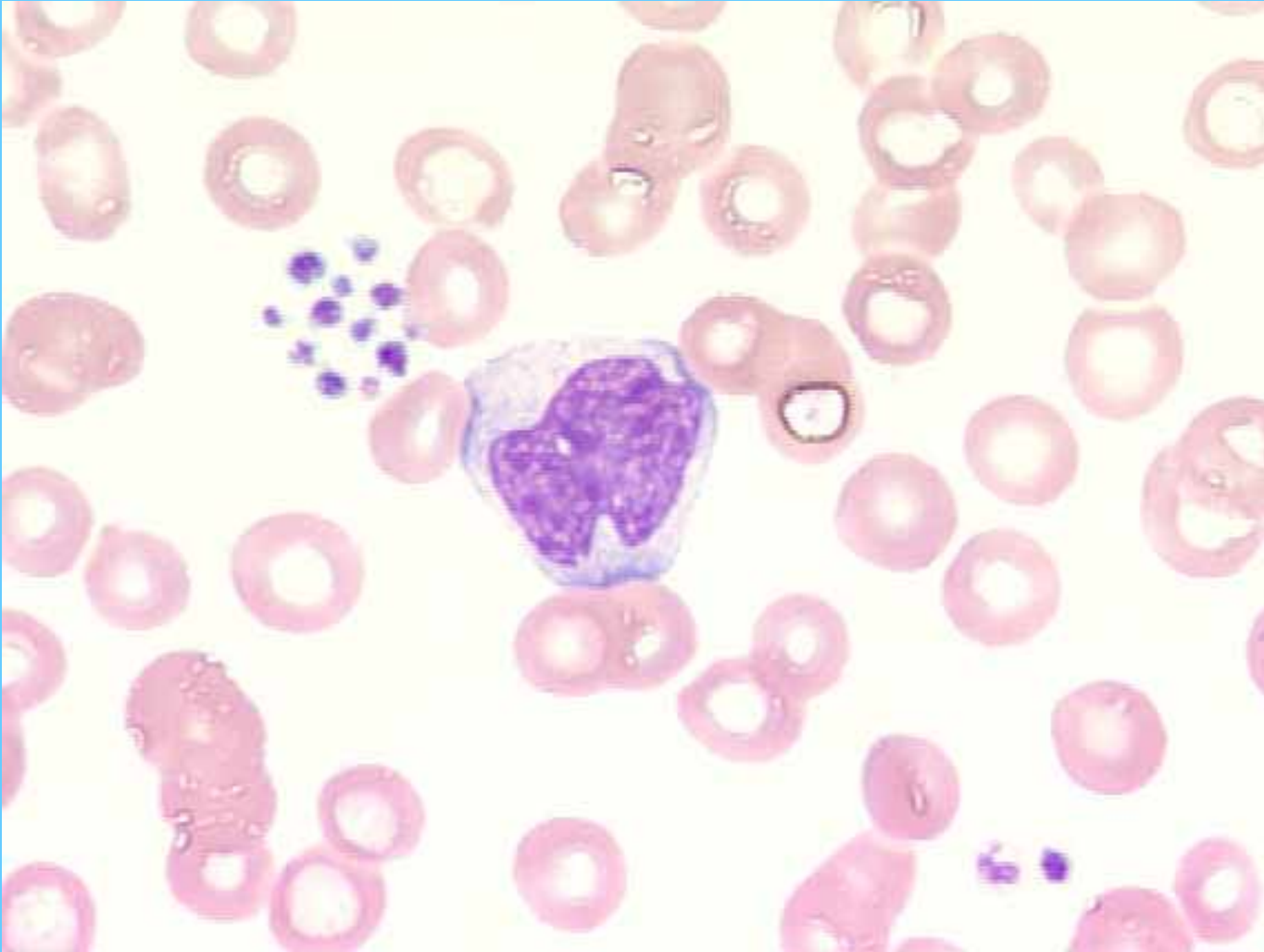
Neutrófilo con vacuola en citoplasma (2)



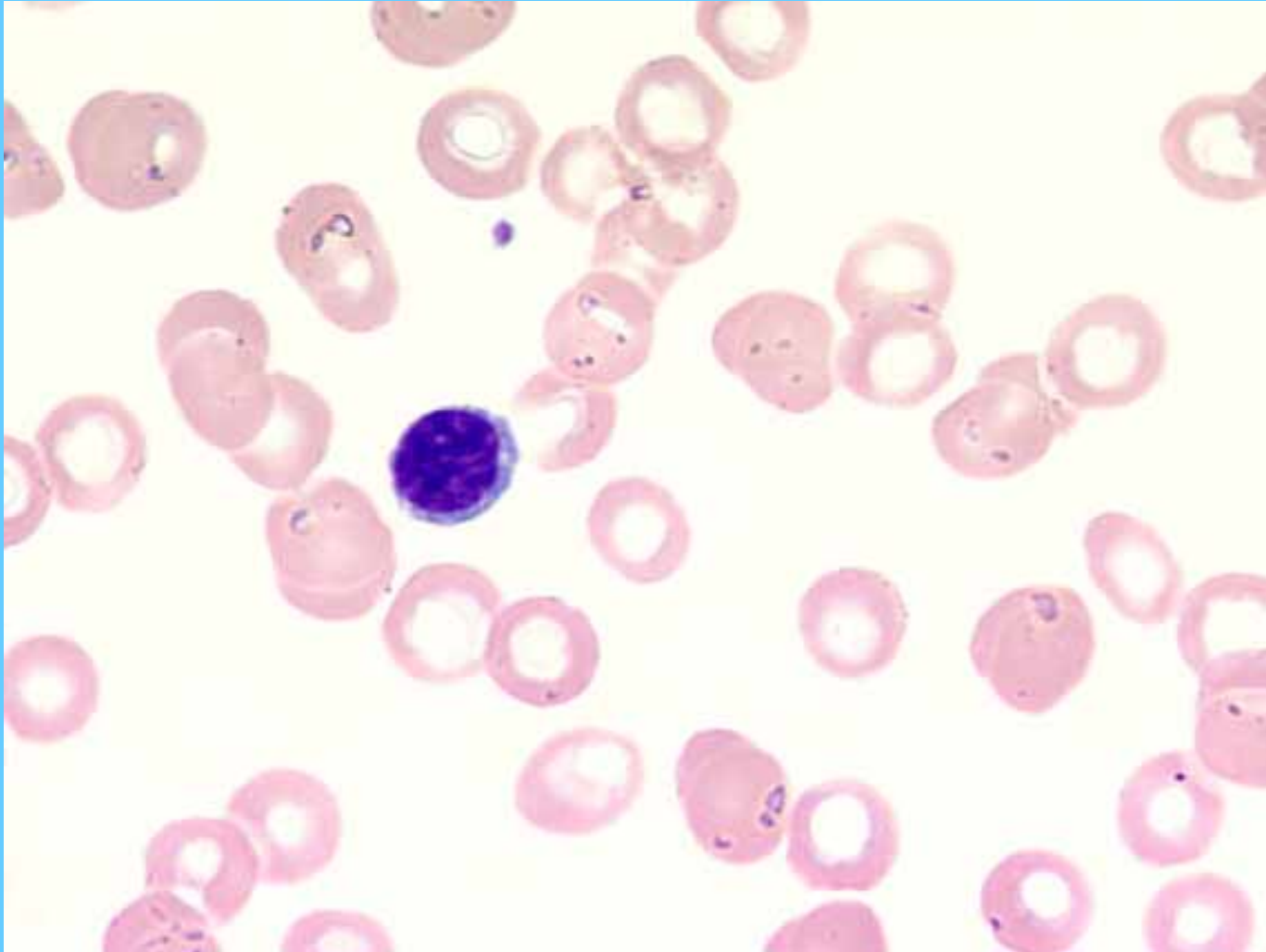
Neutrófilo segmentado



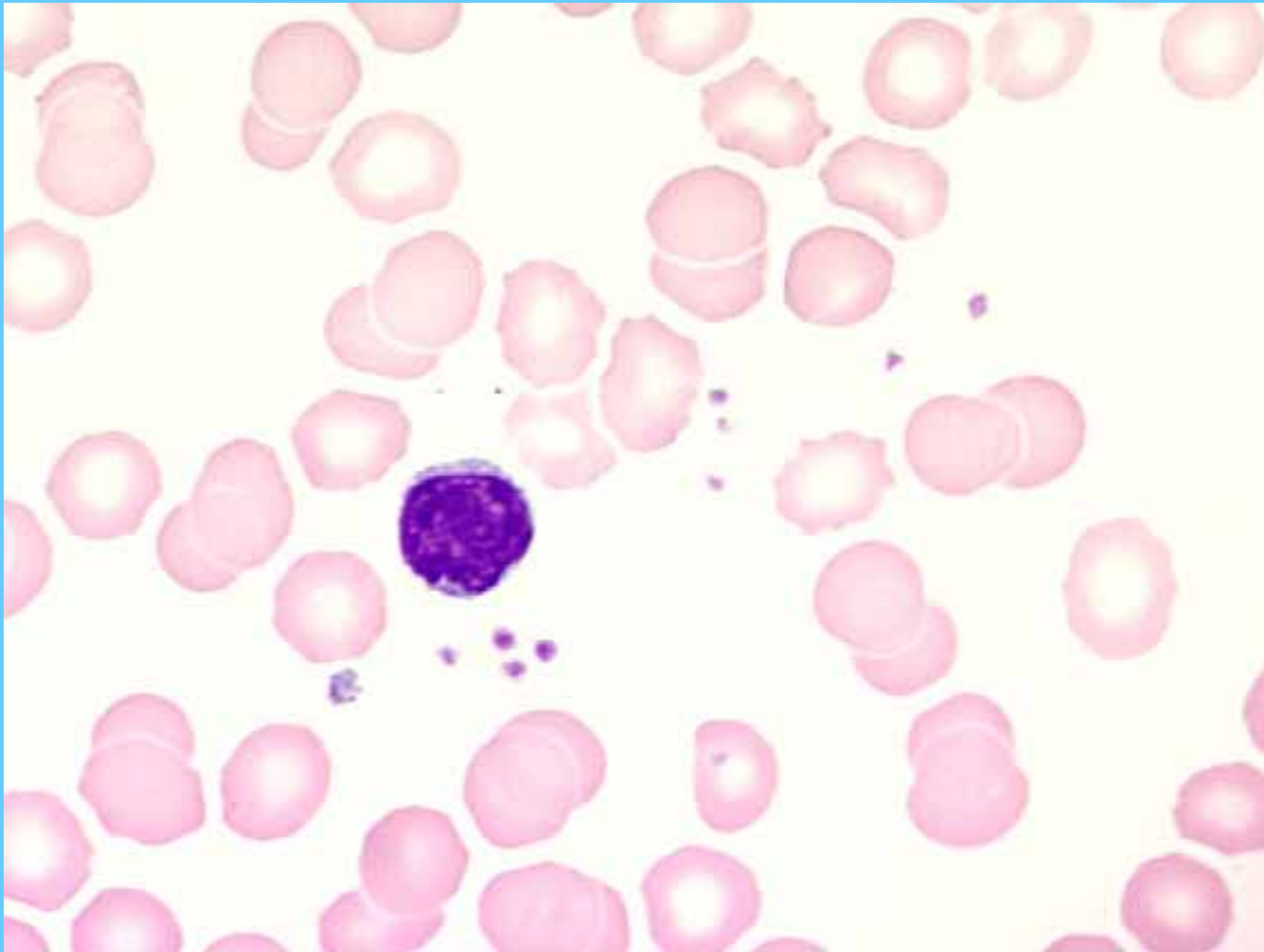
Monocito



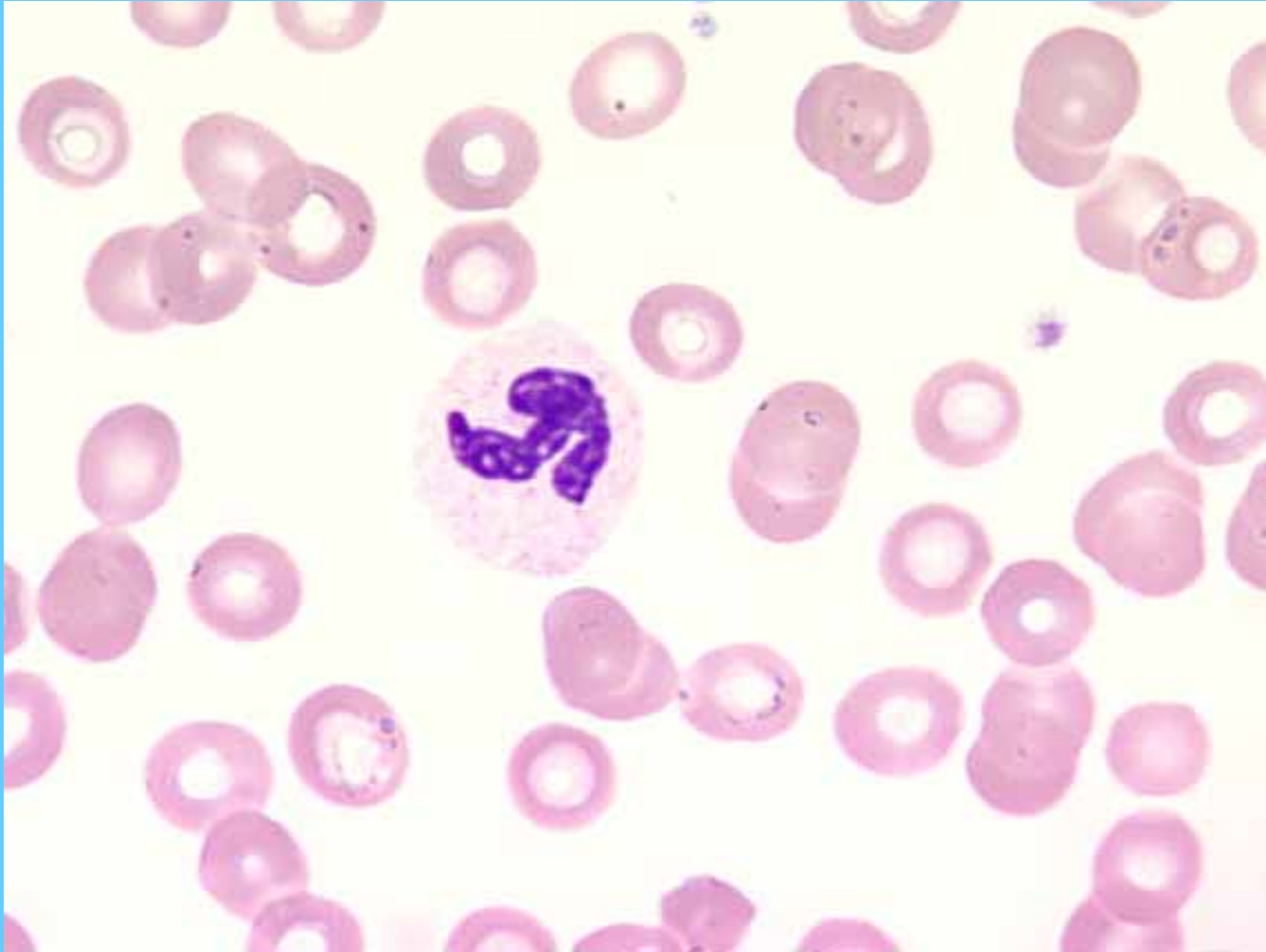
Linfocito



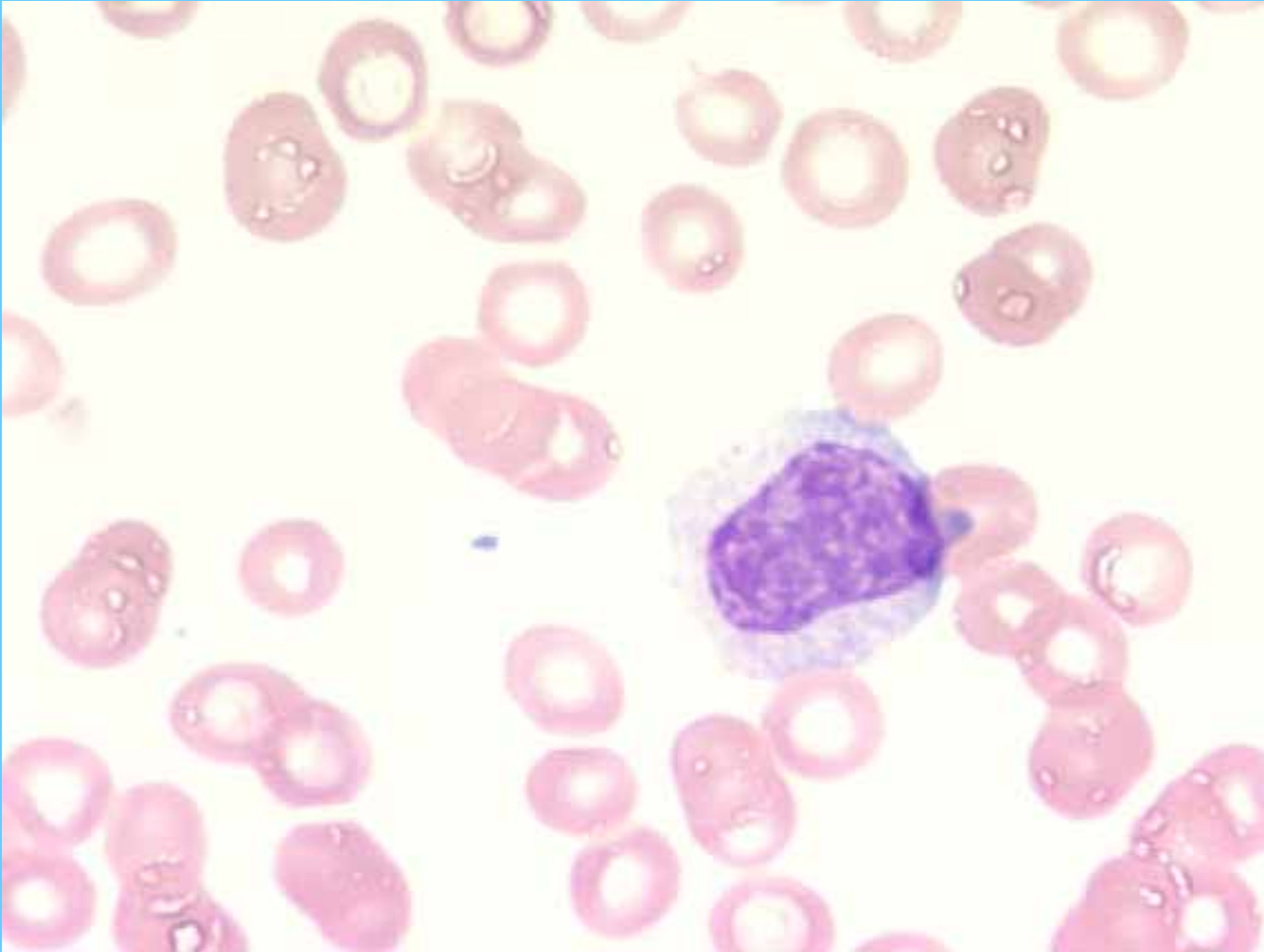
Linfocito



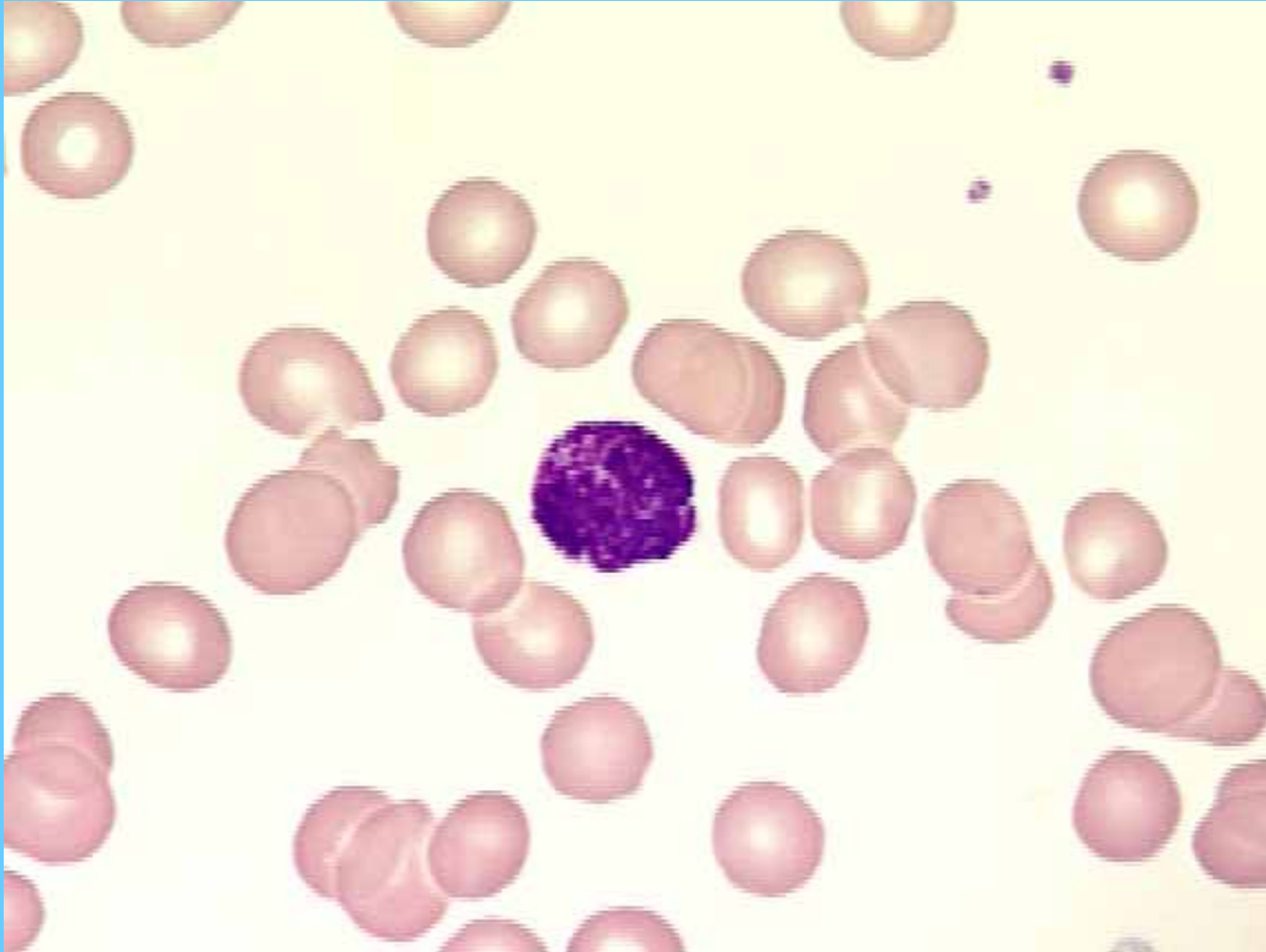Banda



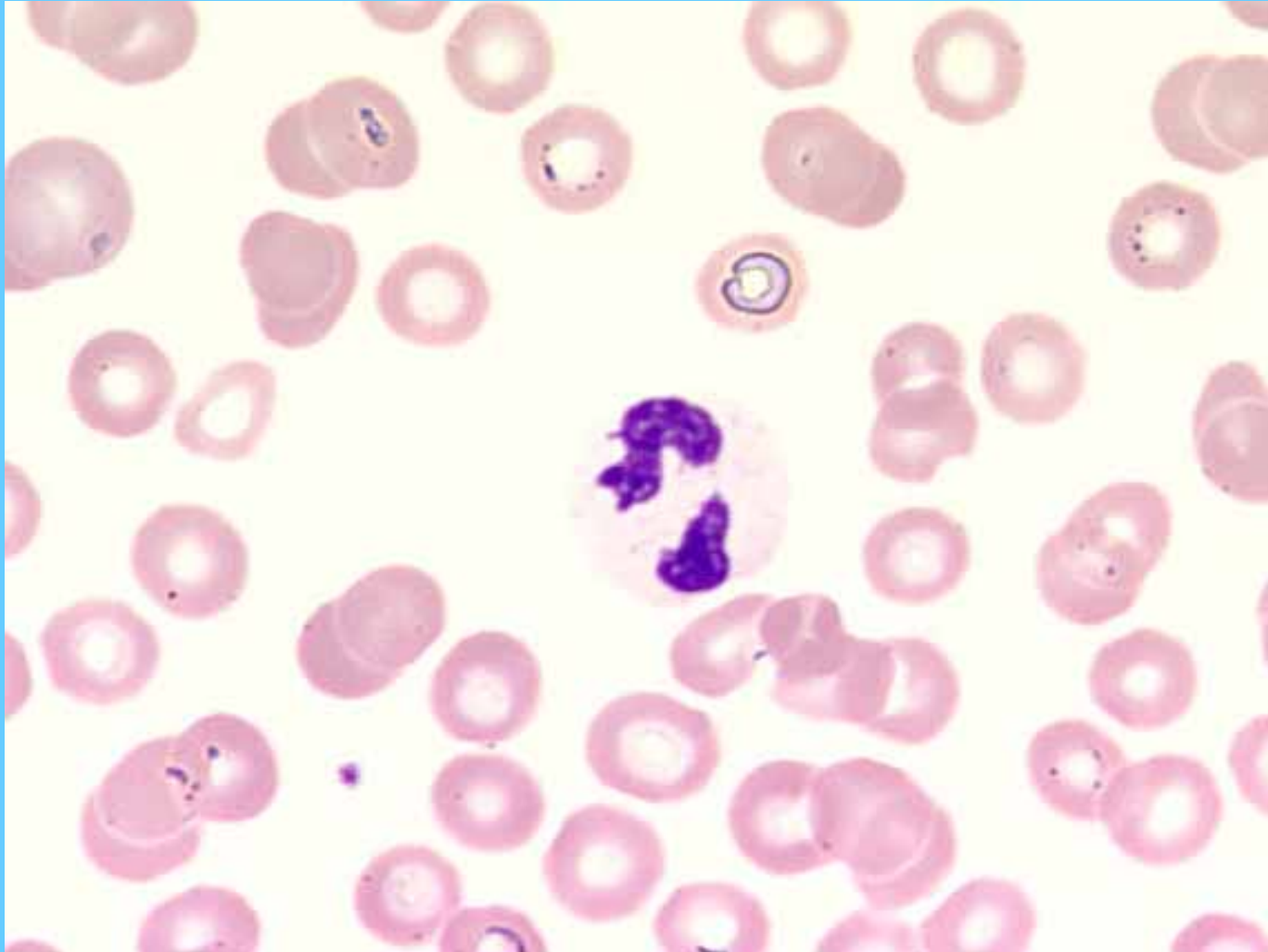
Monocito



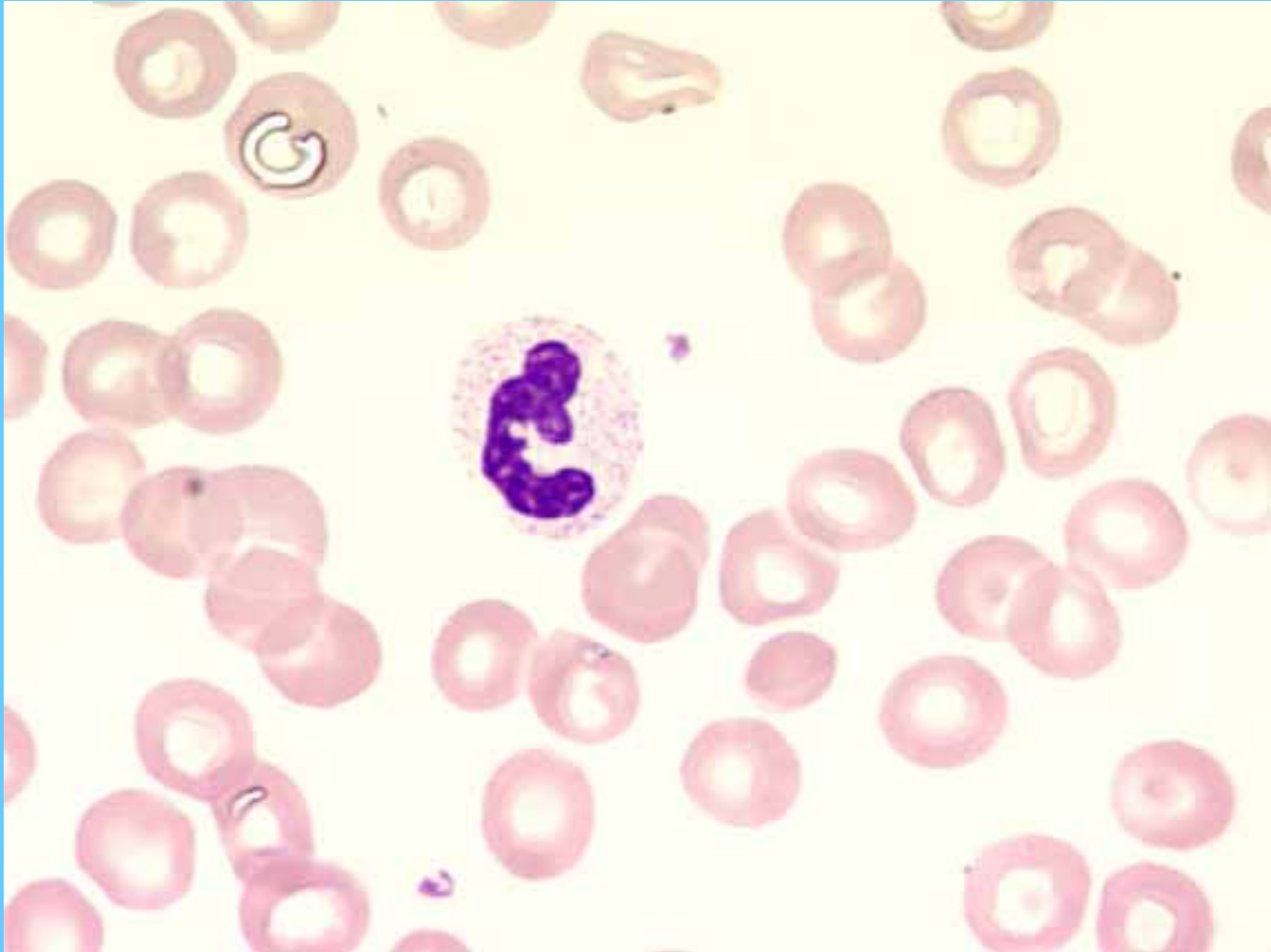
Basófilo



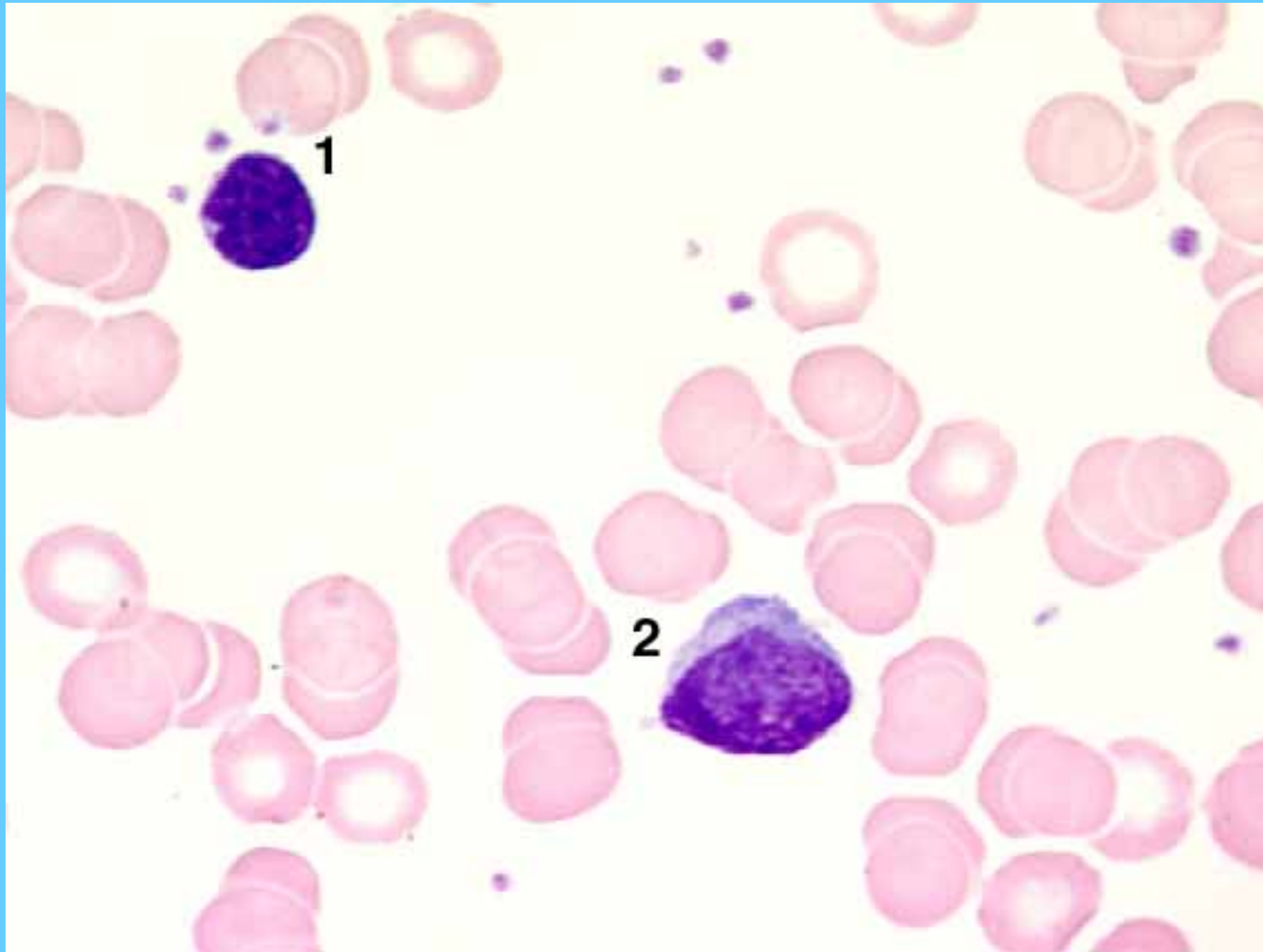
Neutrófilo segmentado



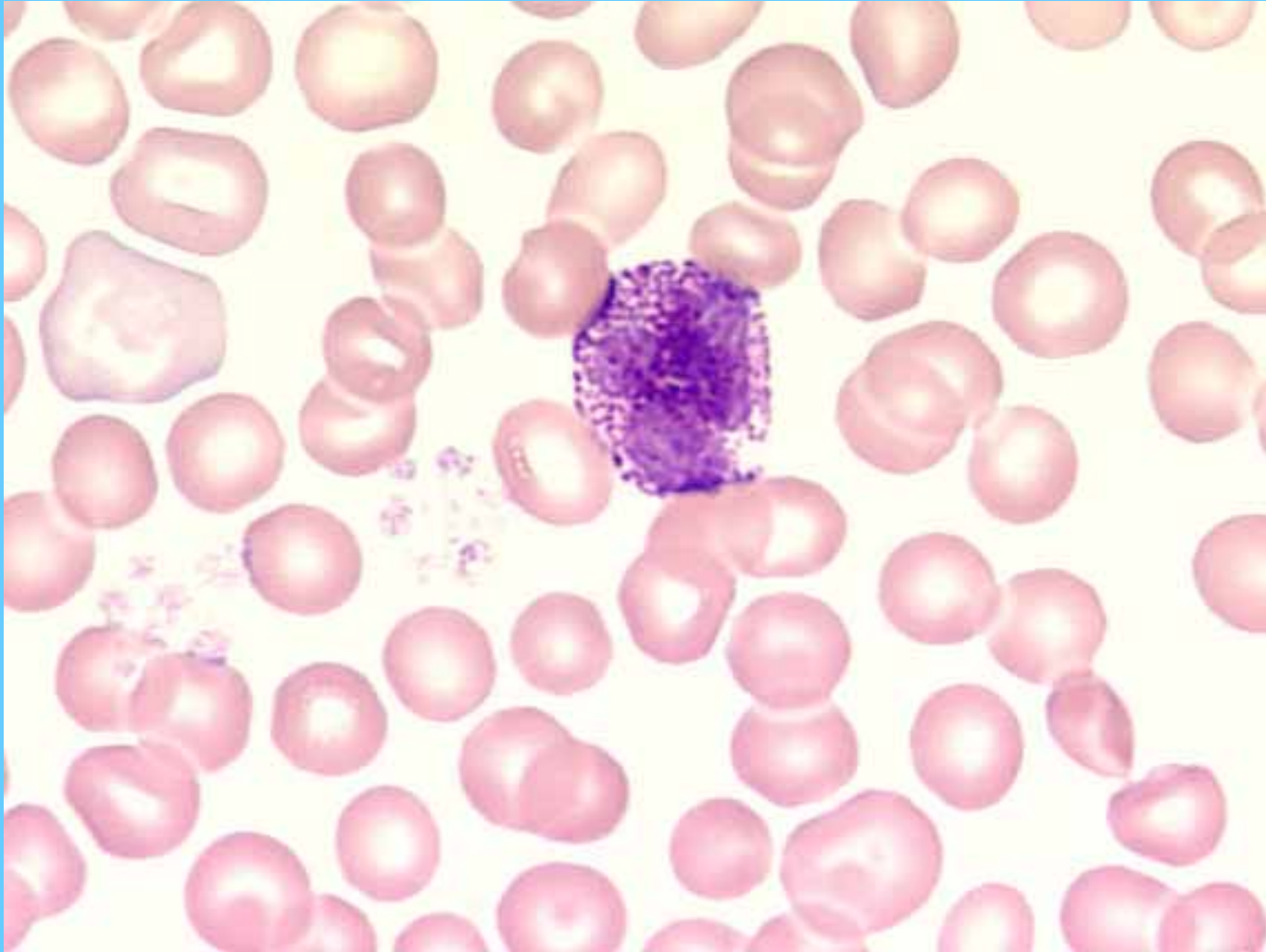
Neutrófilo segmentado



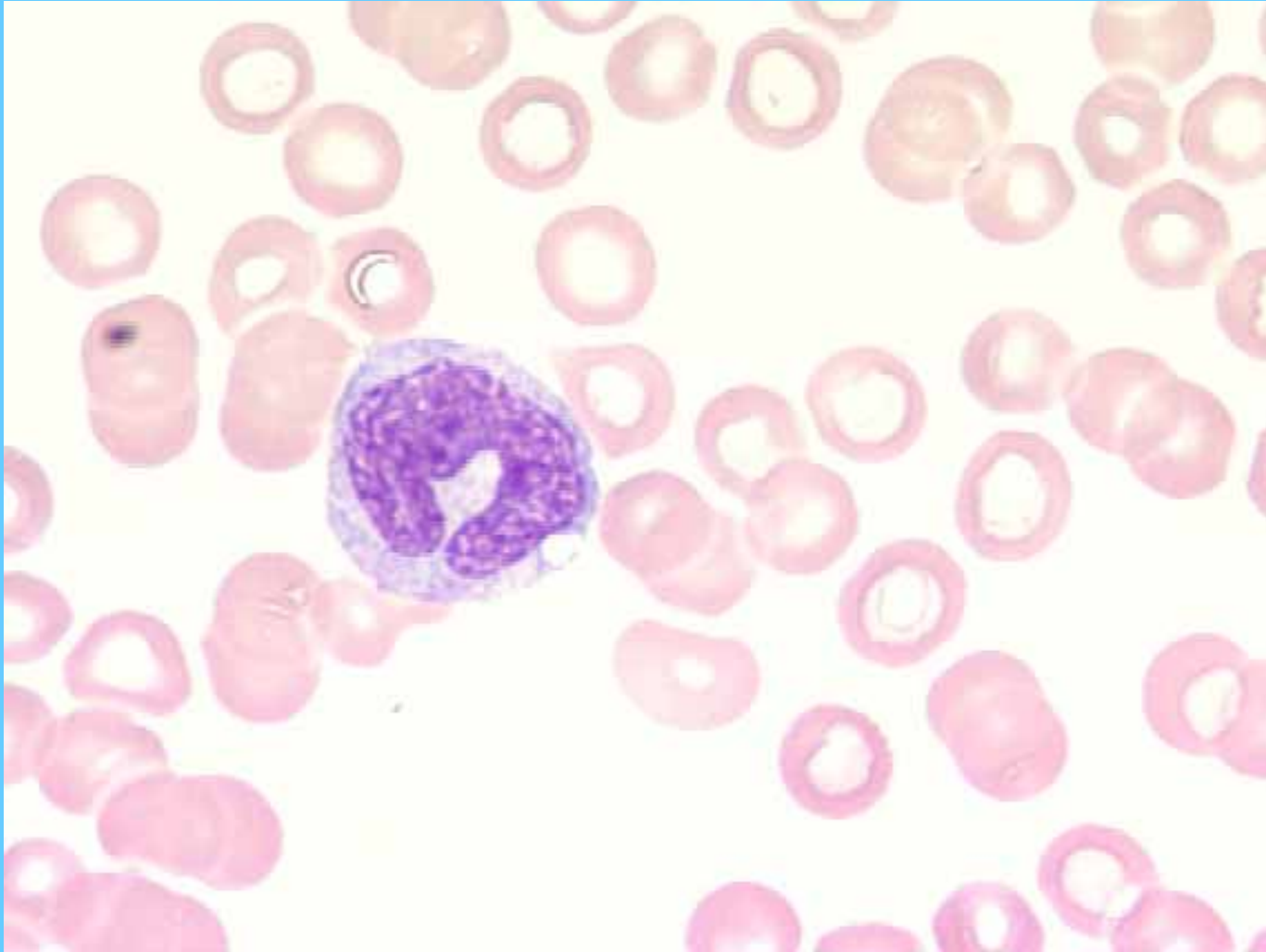
Linfocito



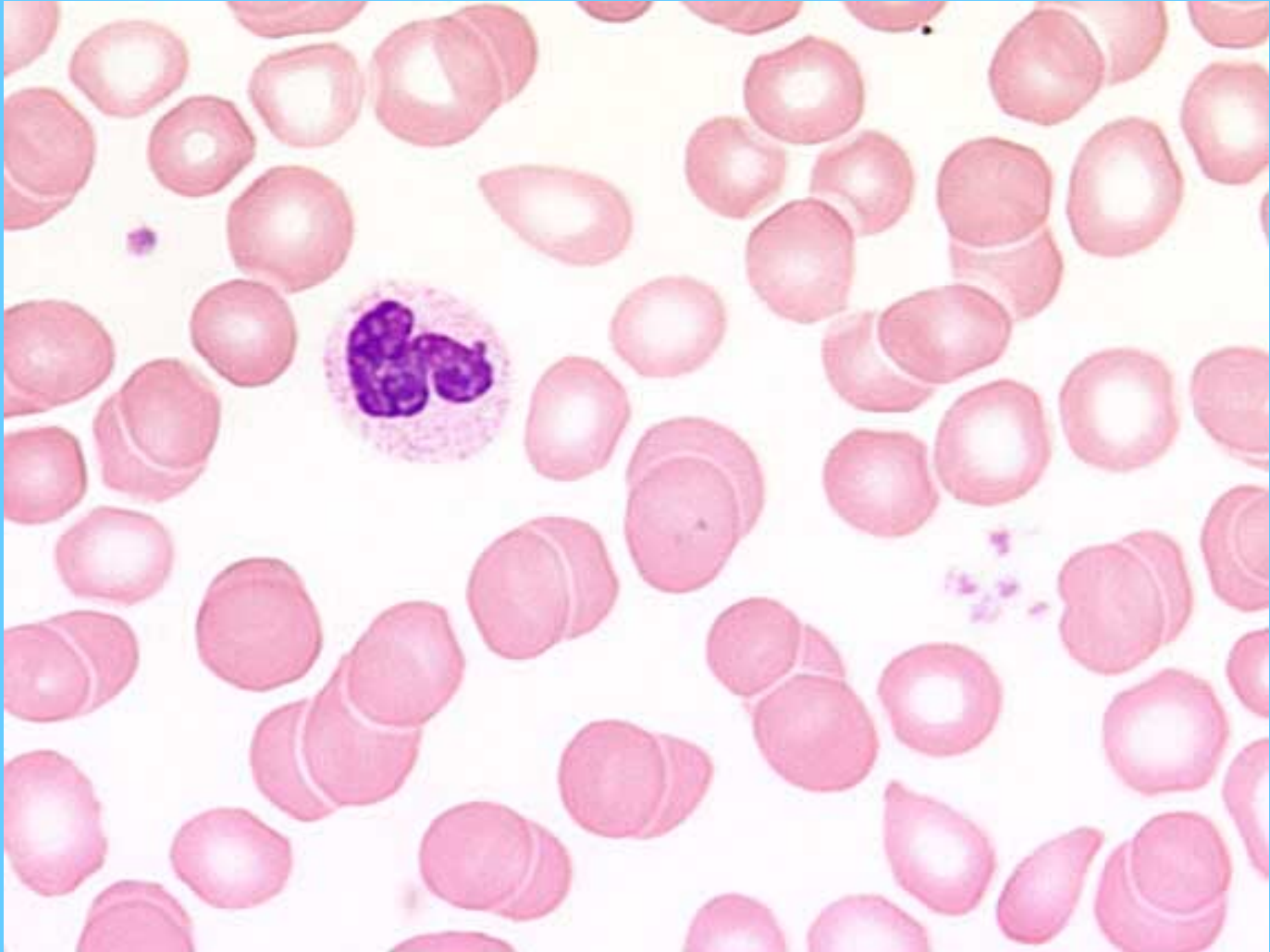
Basófilo



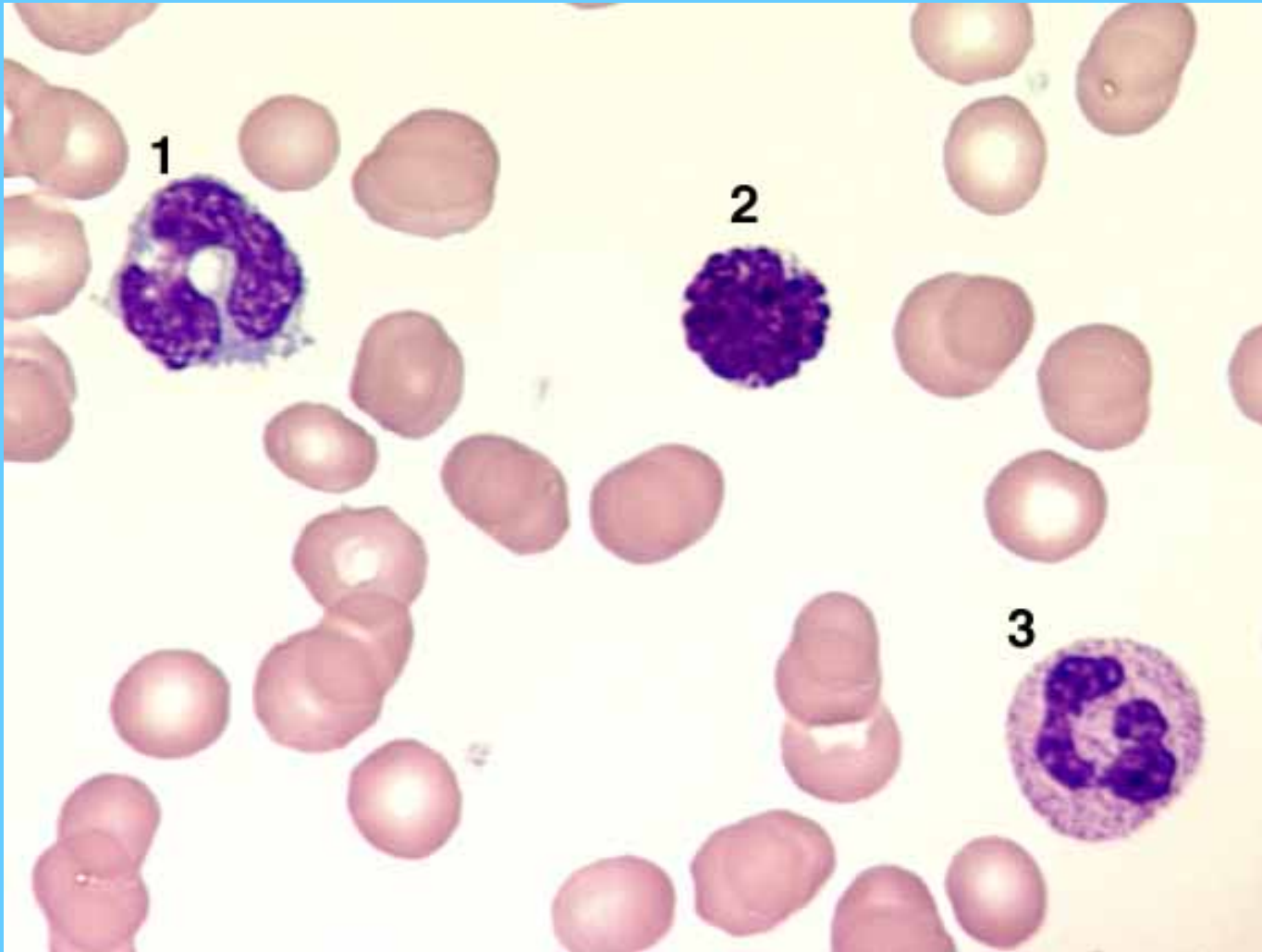
Monocito



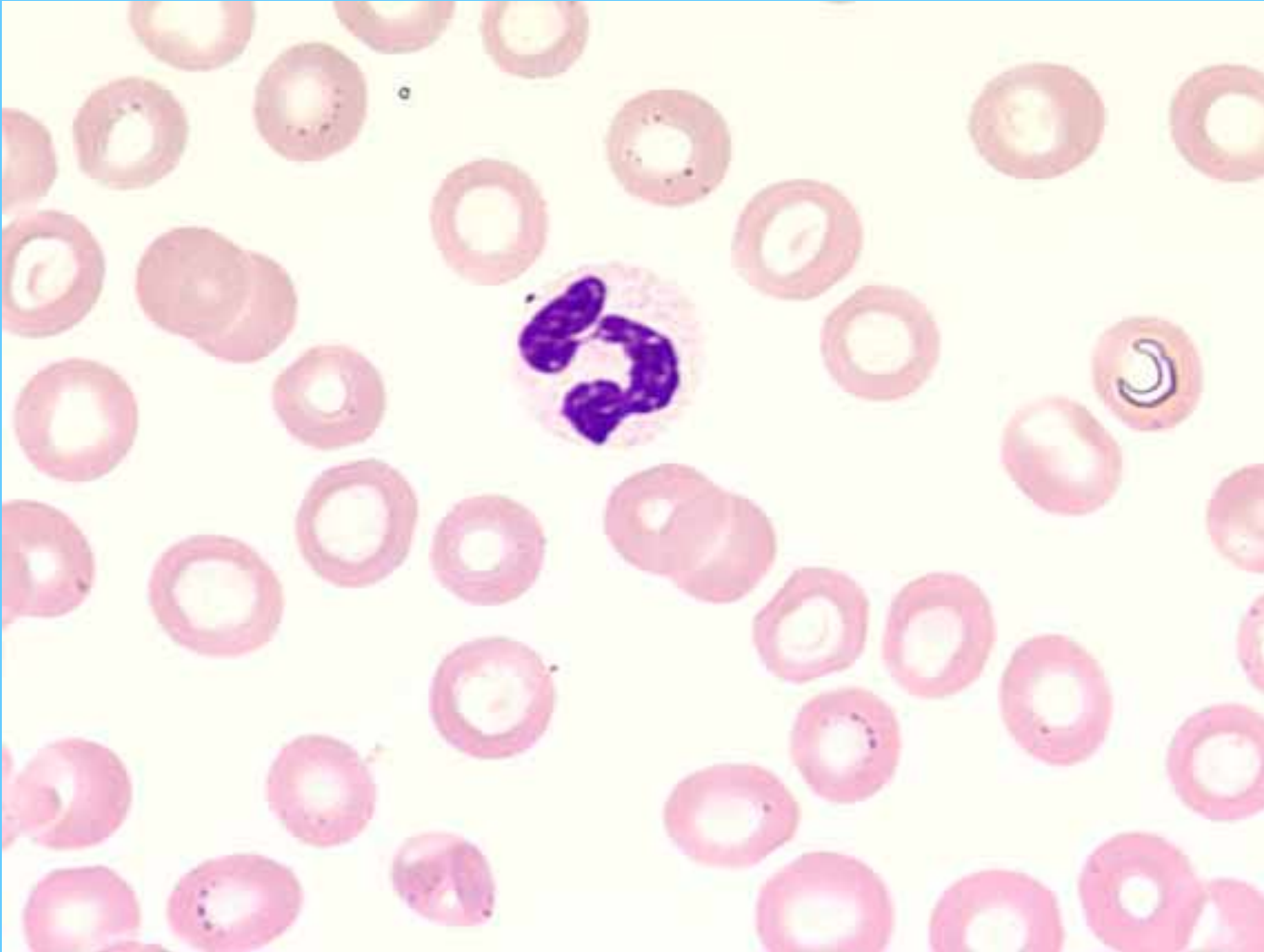
Banda



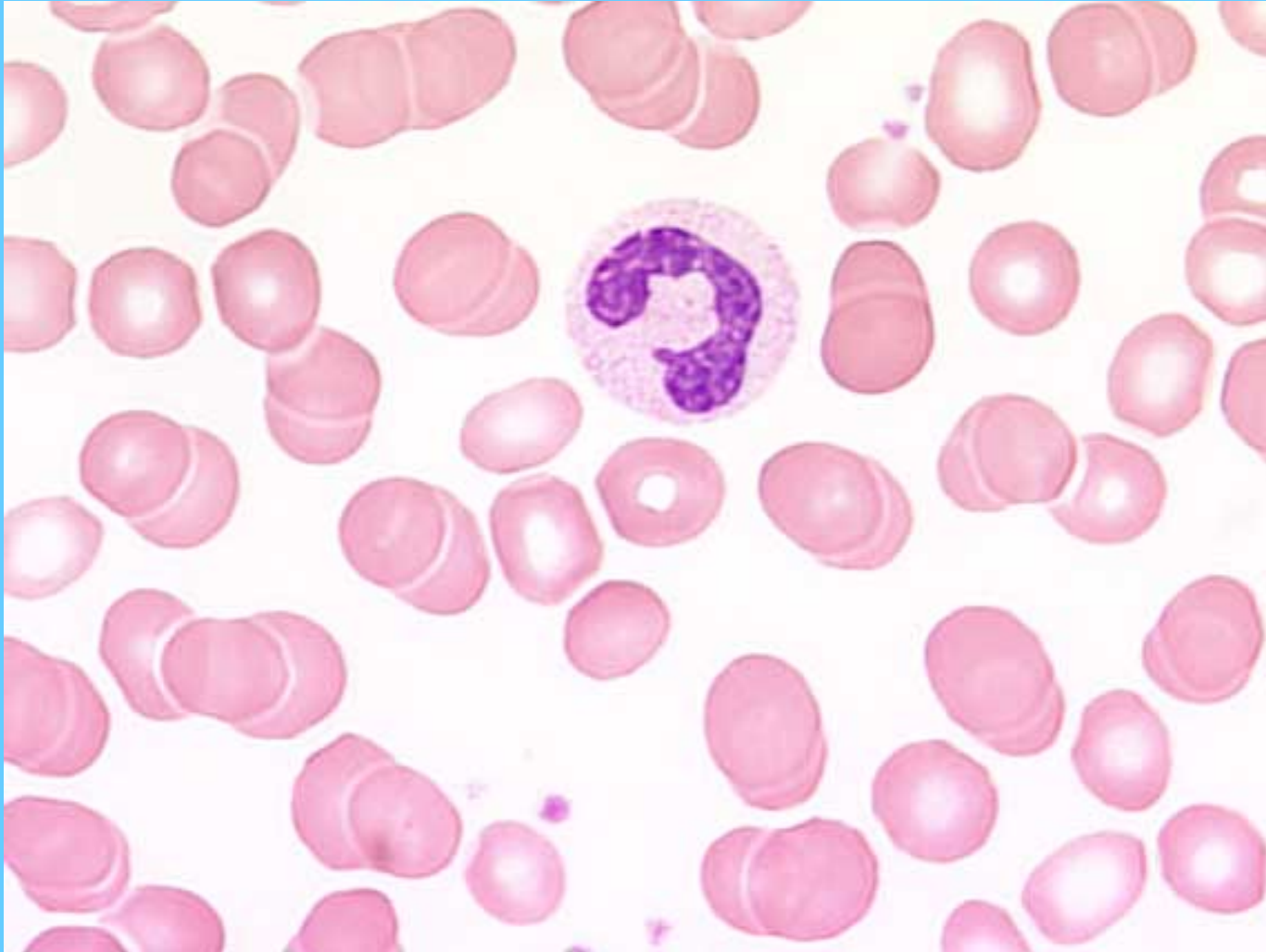
Monocito (1)- Basófilo (2)- N. segmentado (3)



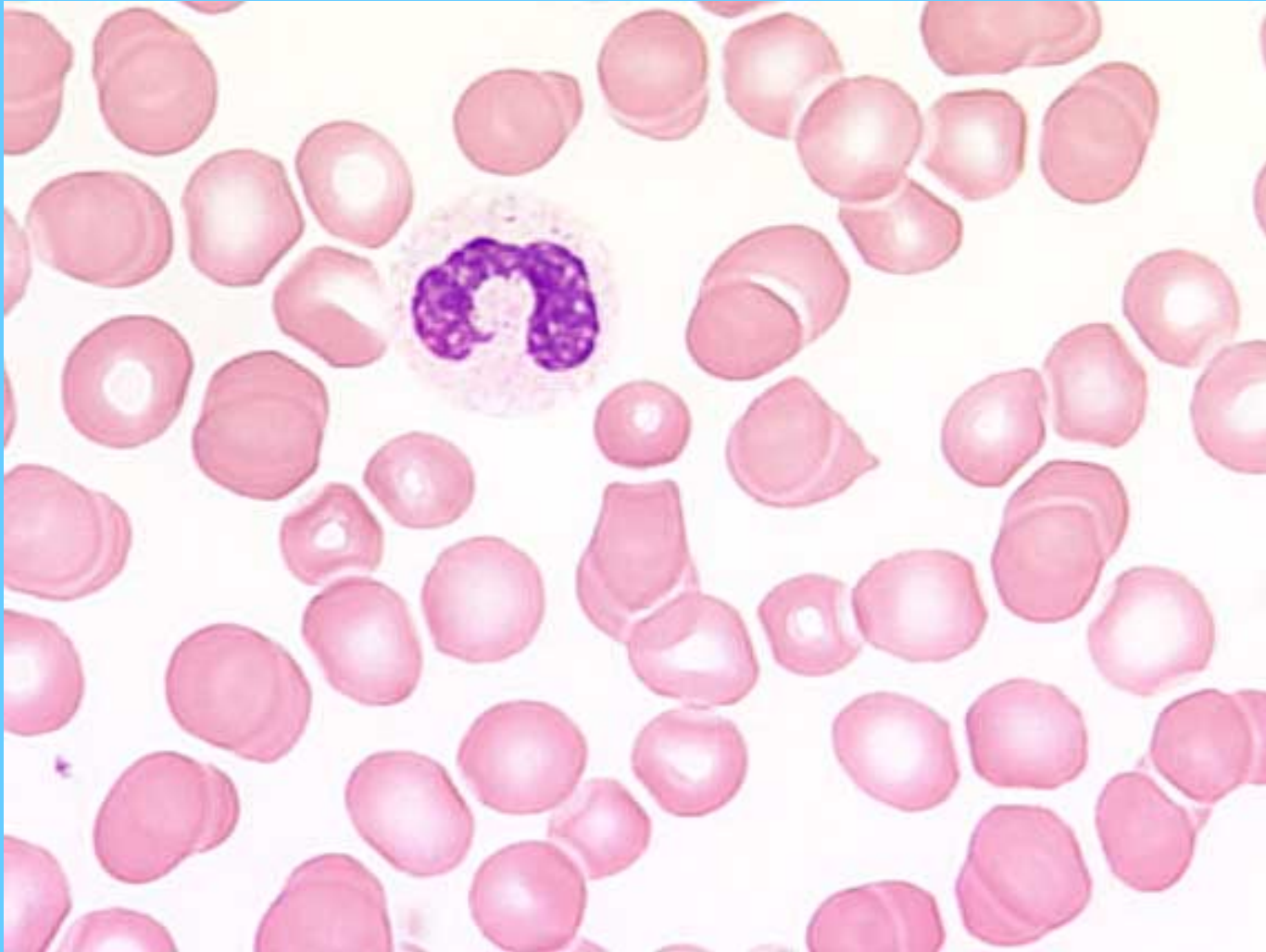
N. segmentado



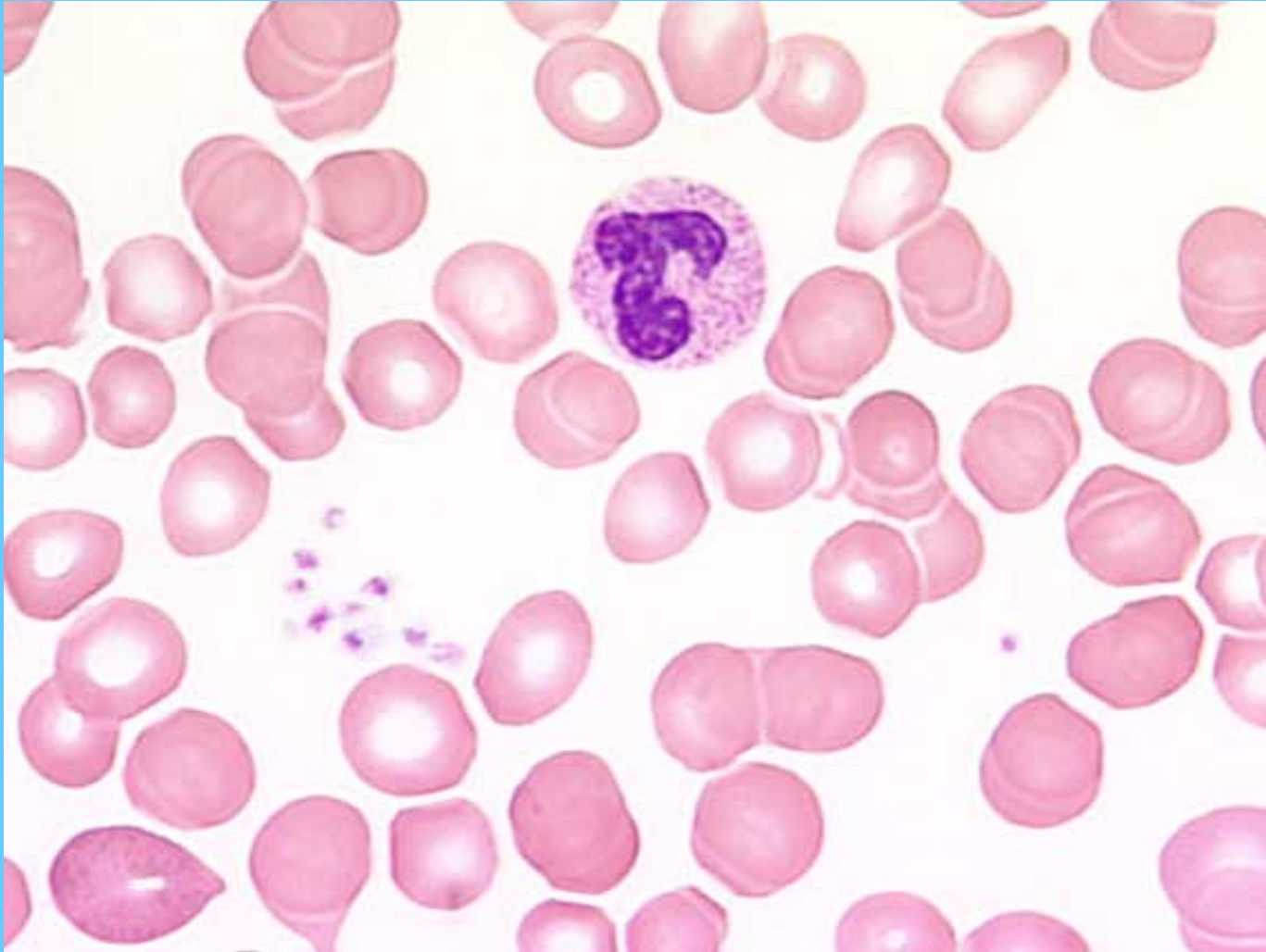
Banda



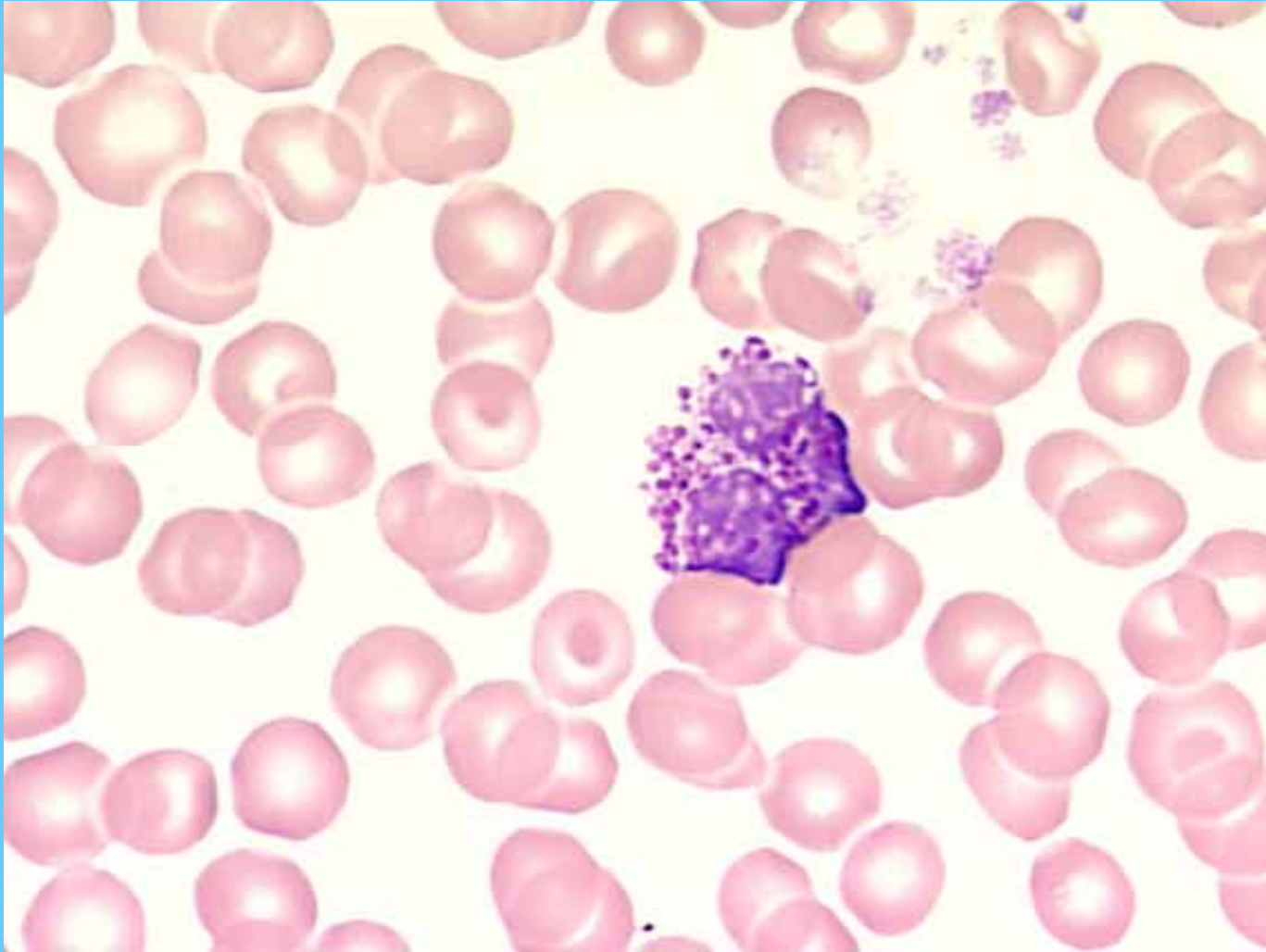
Banda



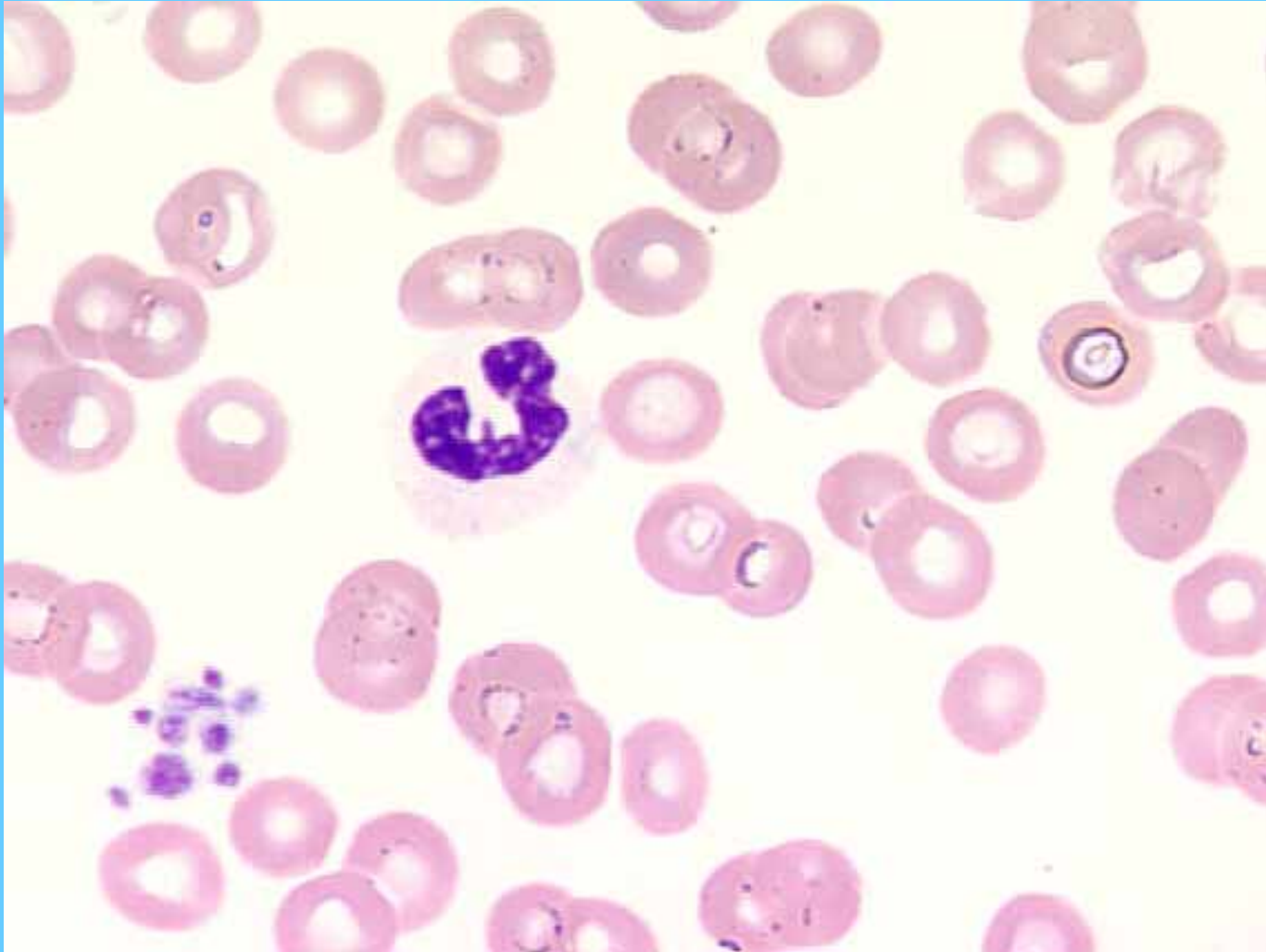
Banda



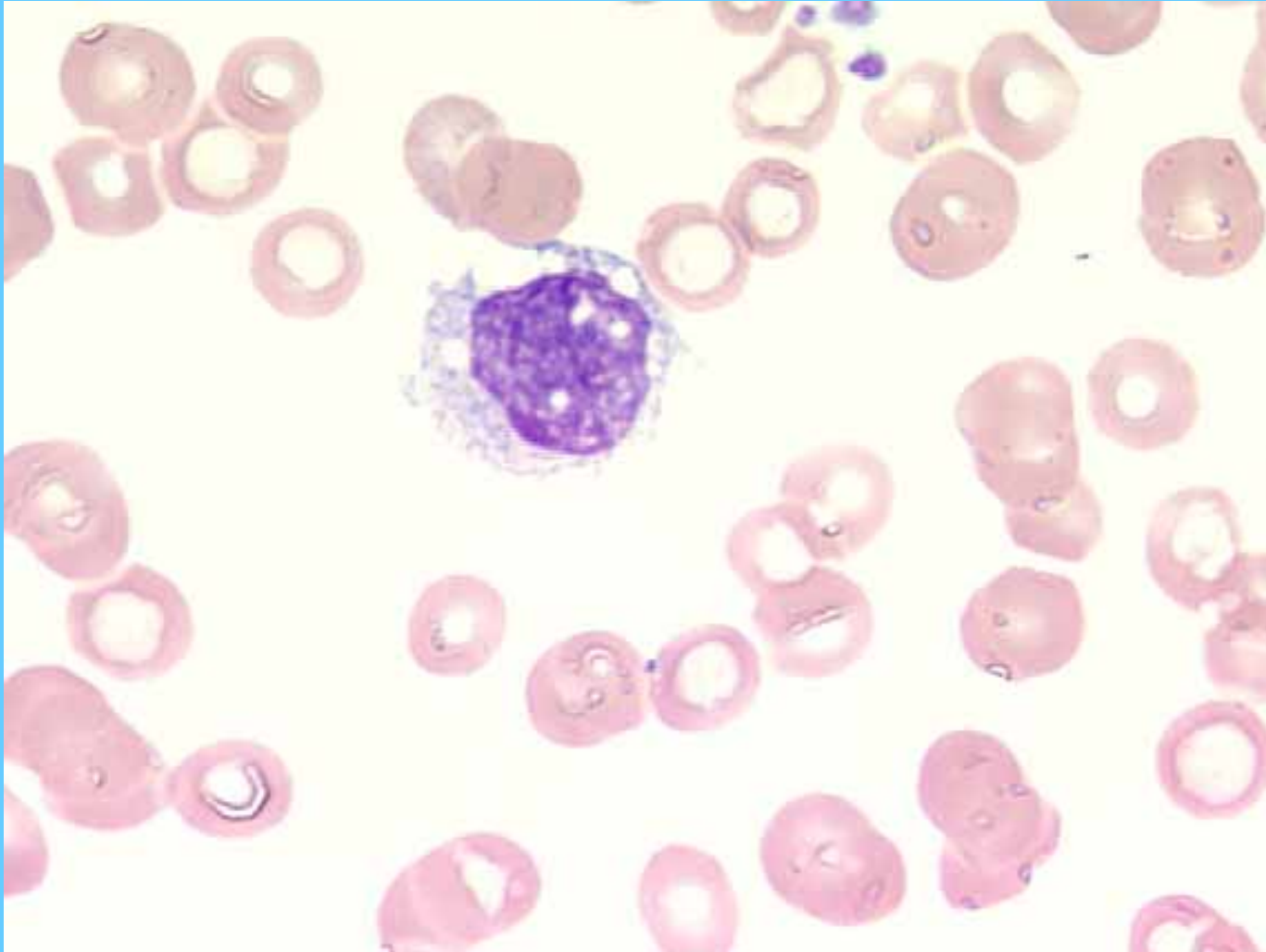
Basófilo

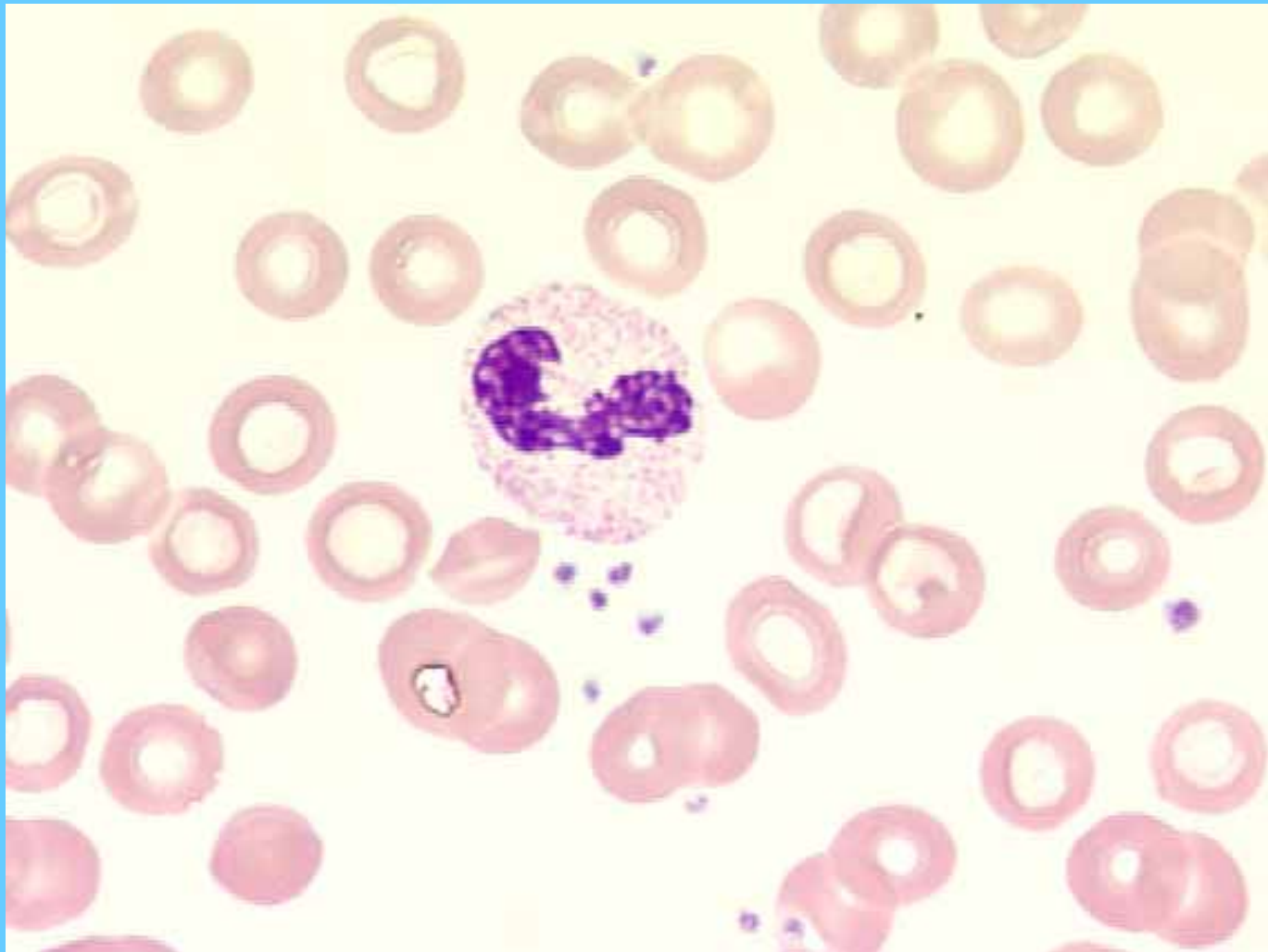


Banda

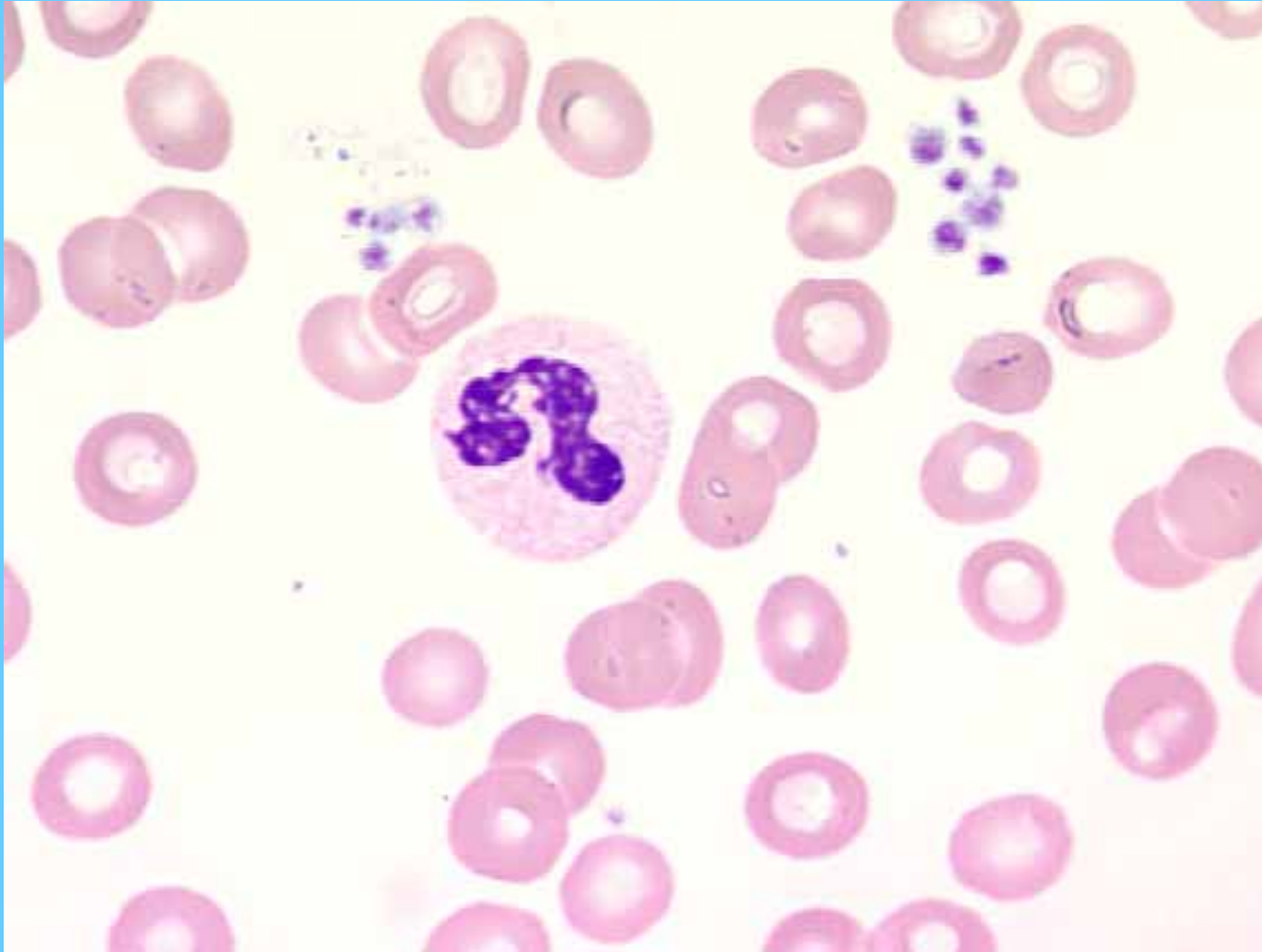


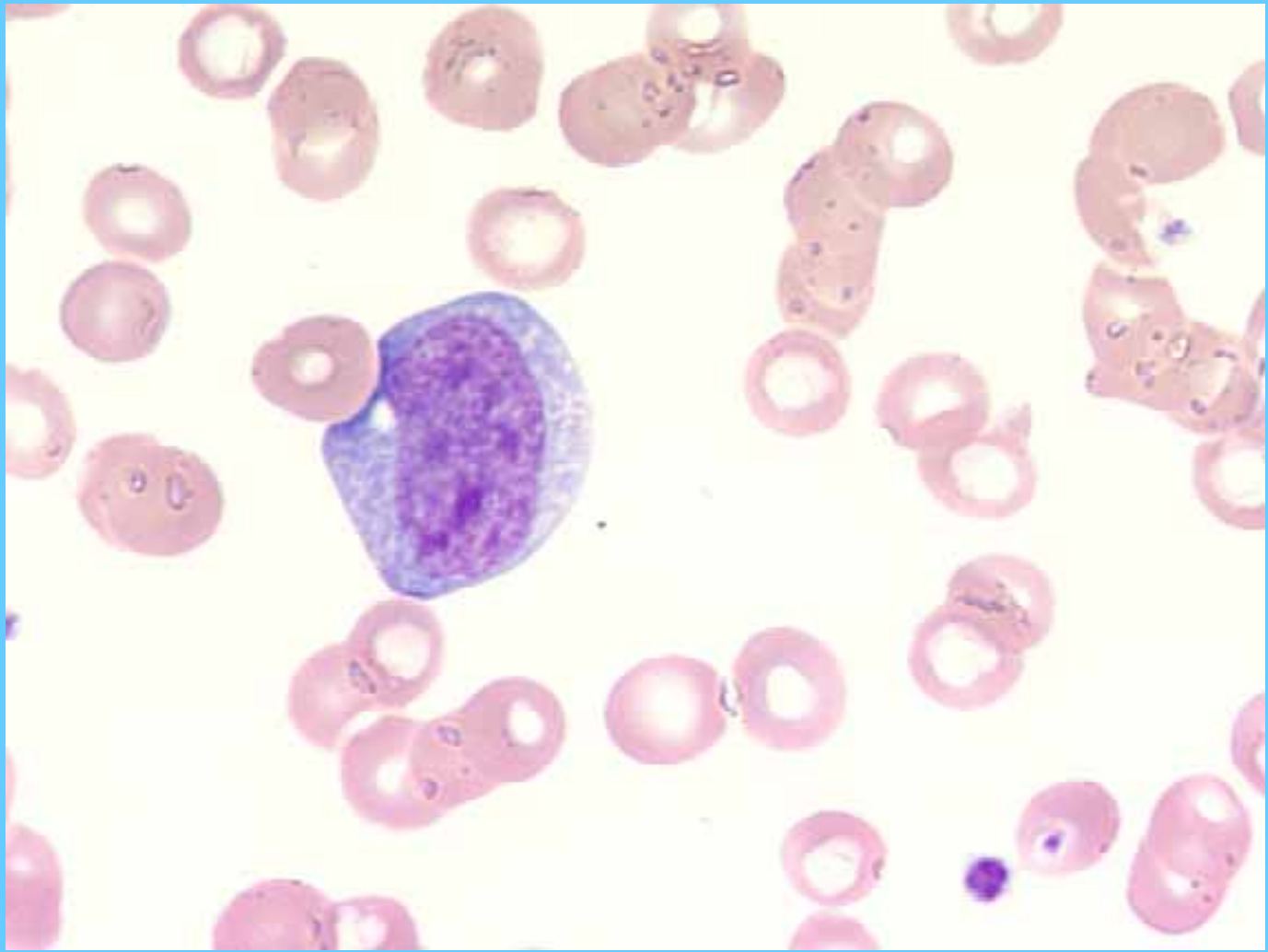
Monocito



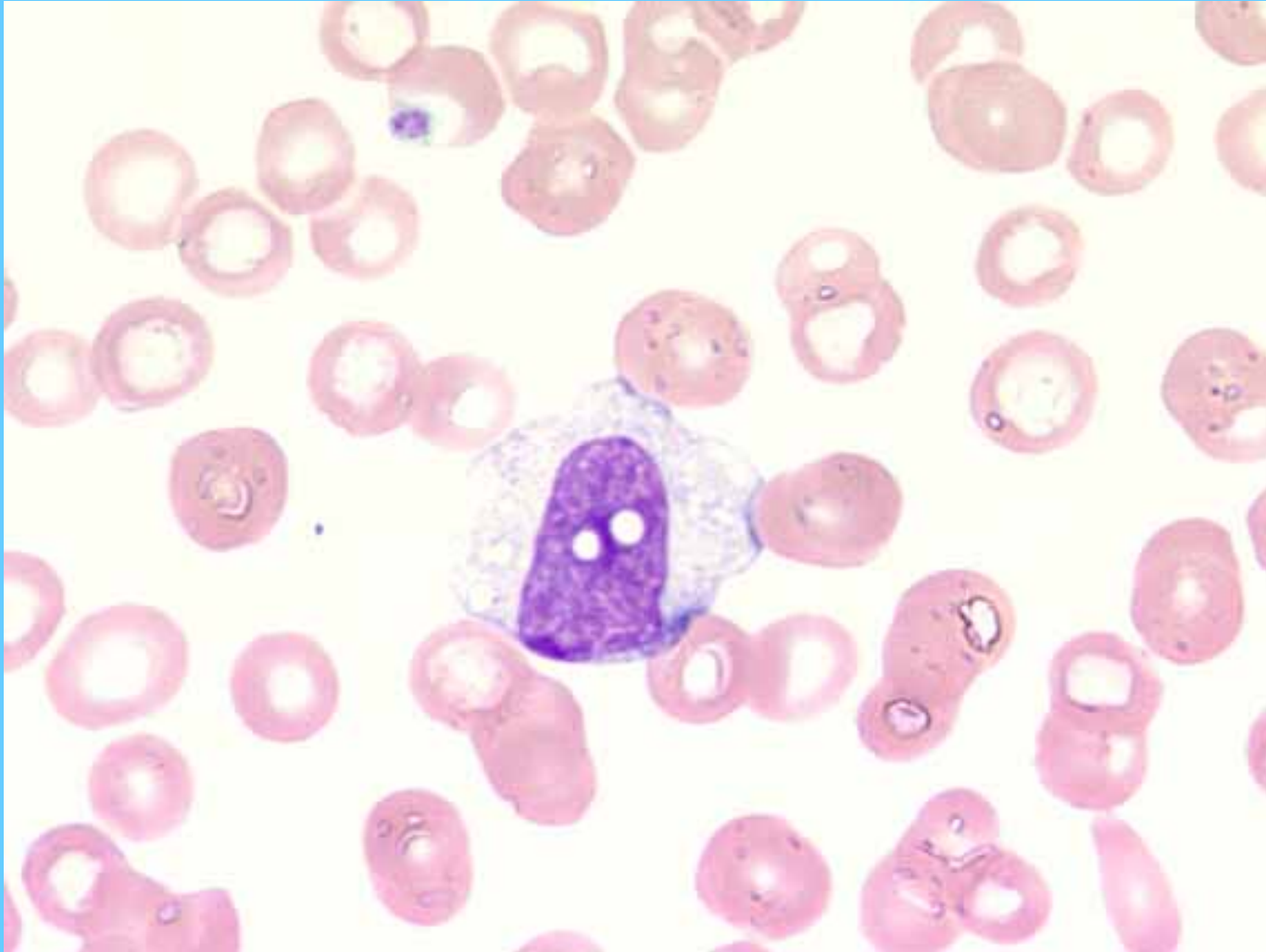


Neutrófilo segmentado

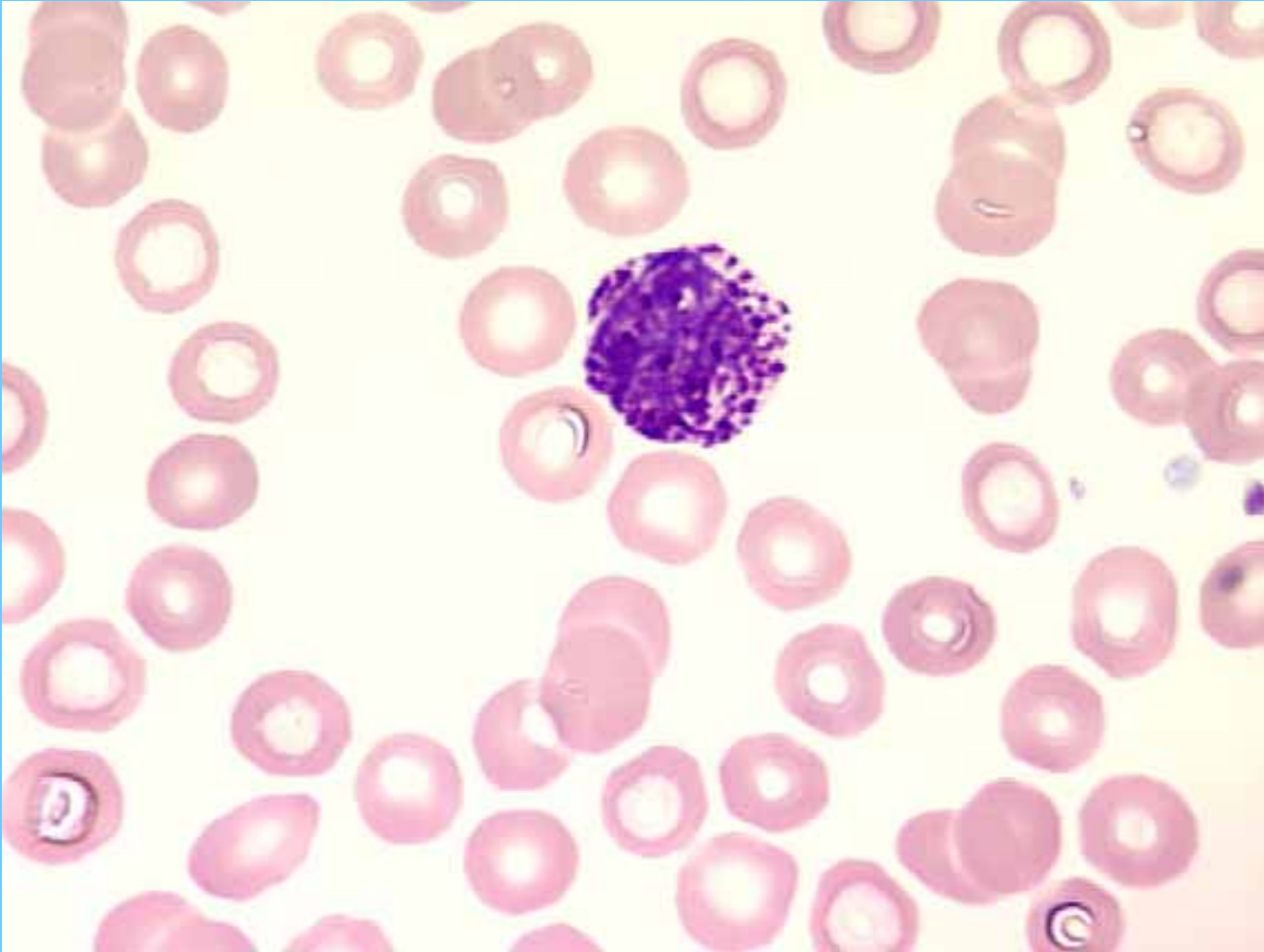




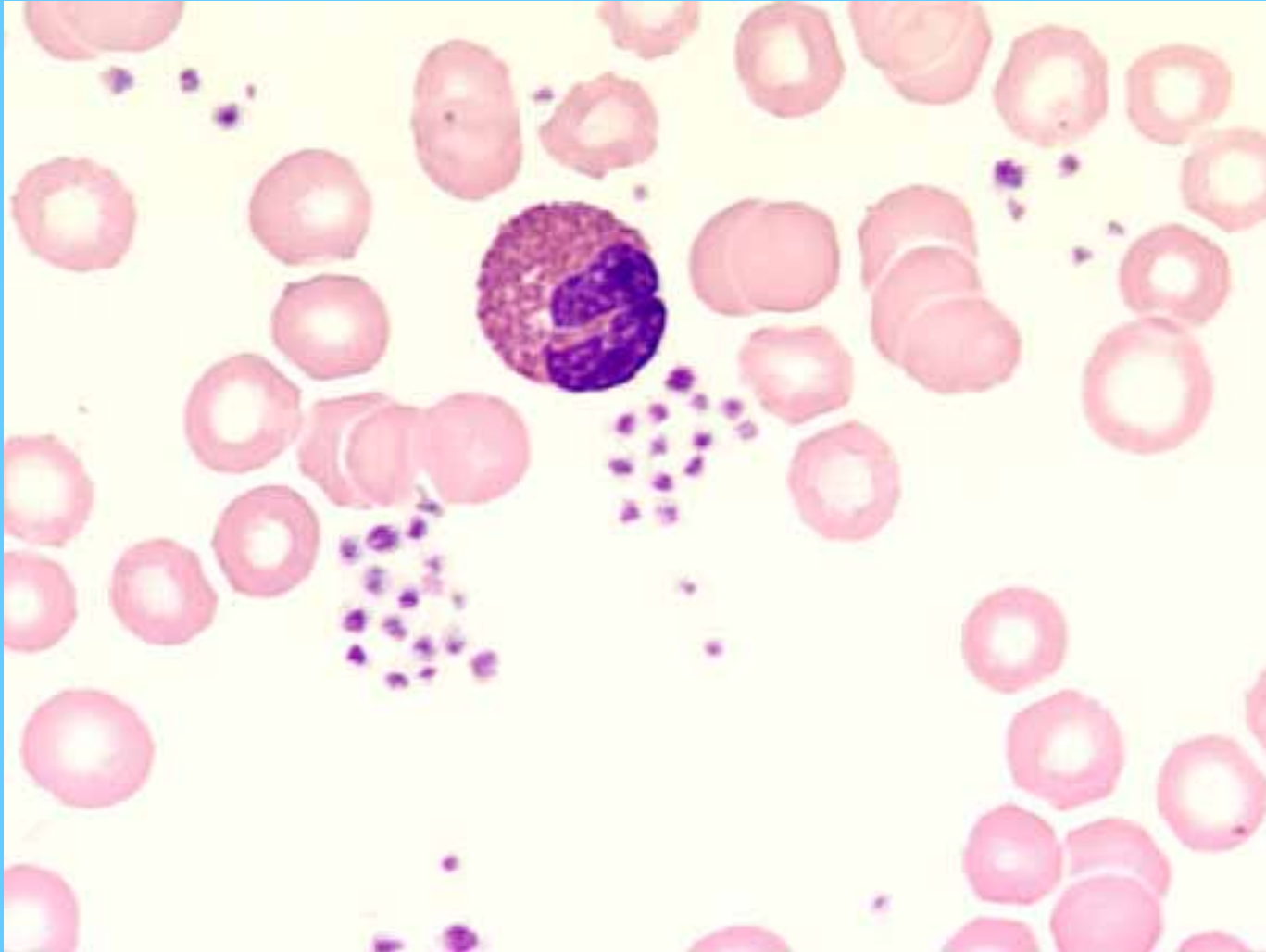
Monocito



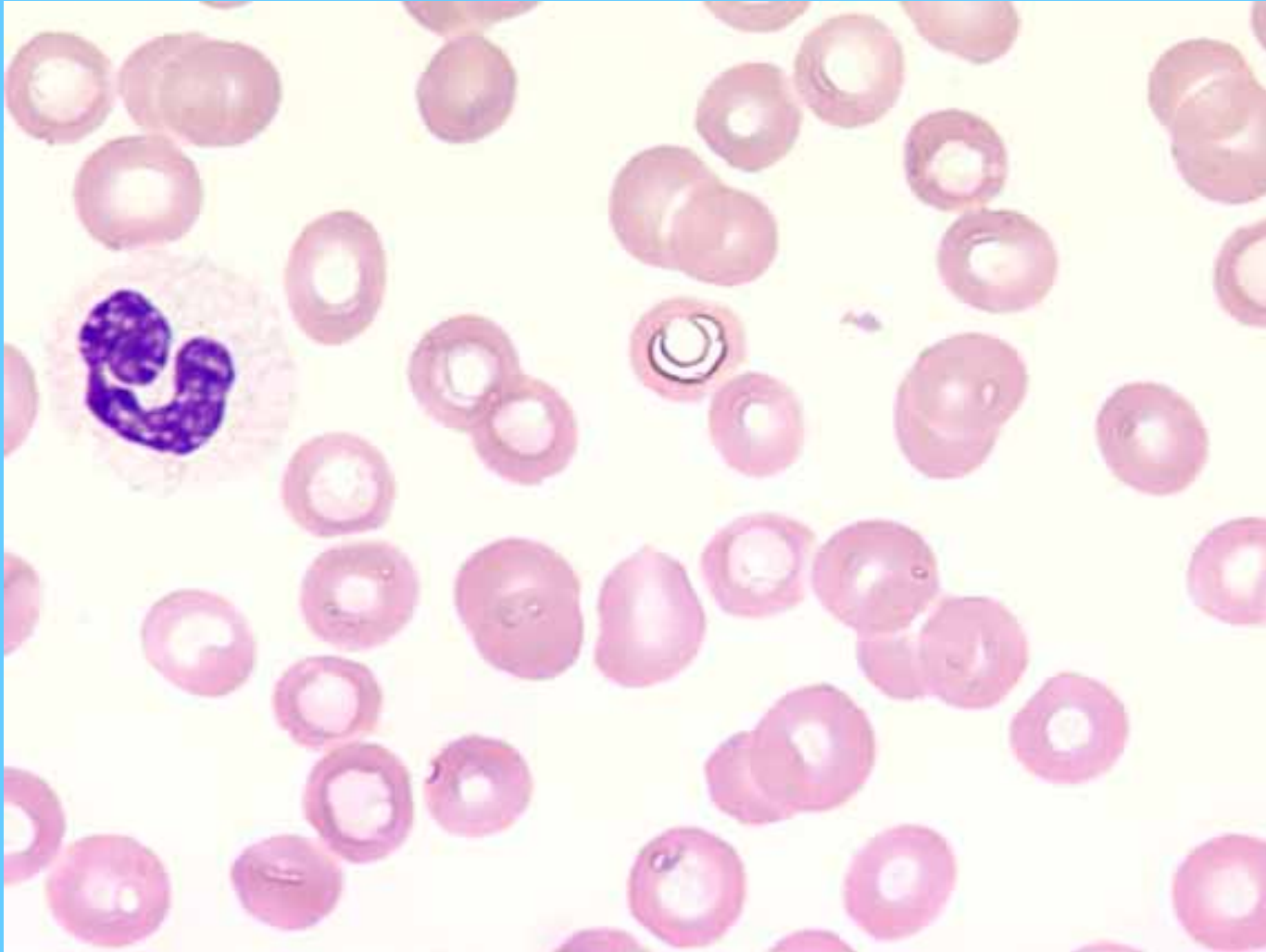
Basófilo



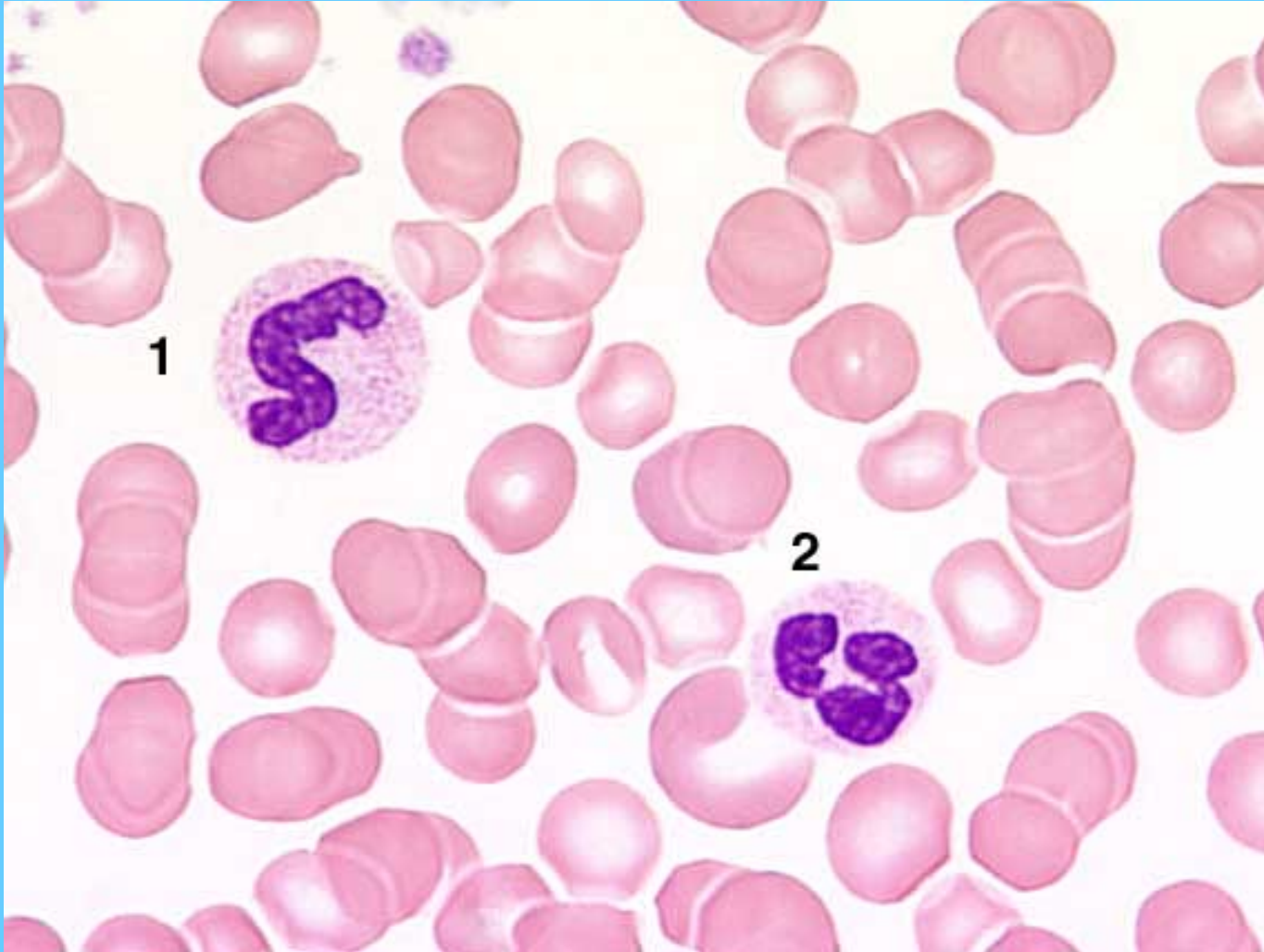
Eosinófilo



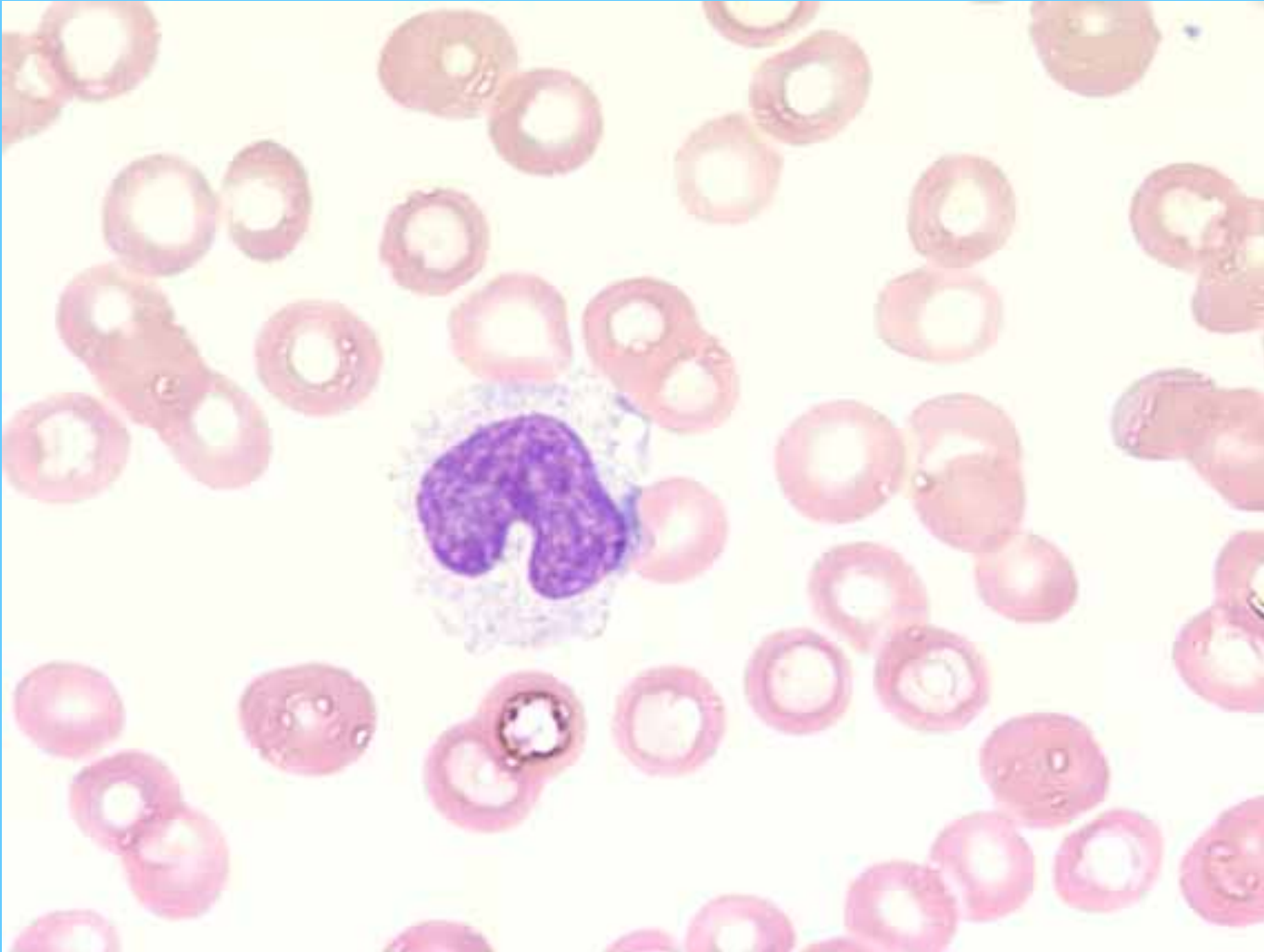
N. Segmentado



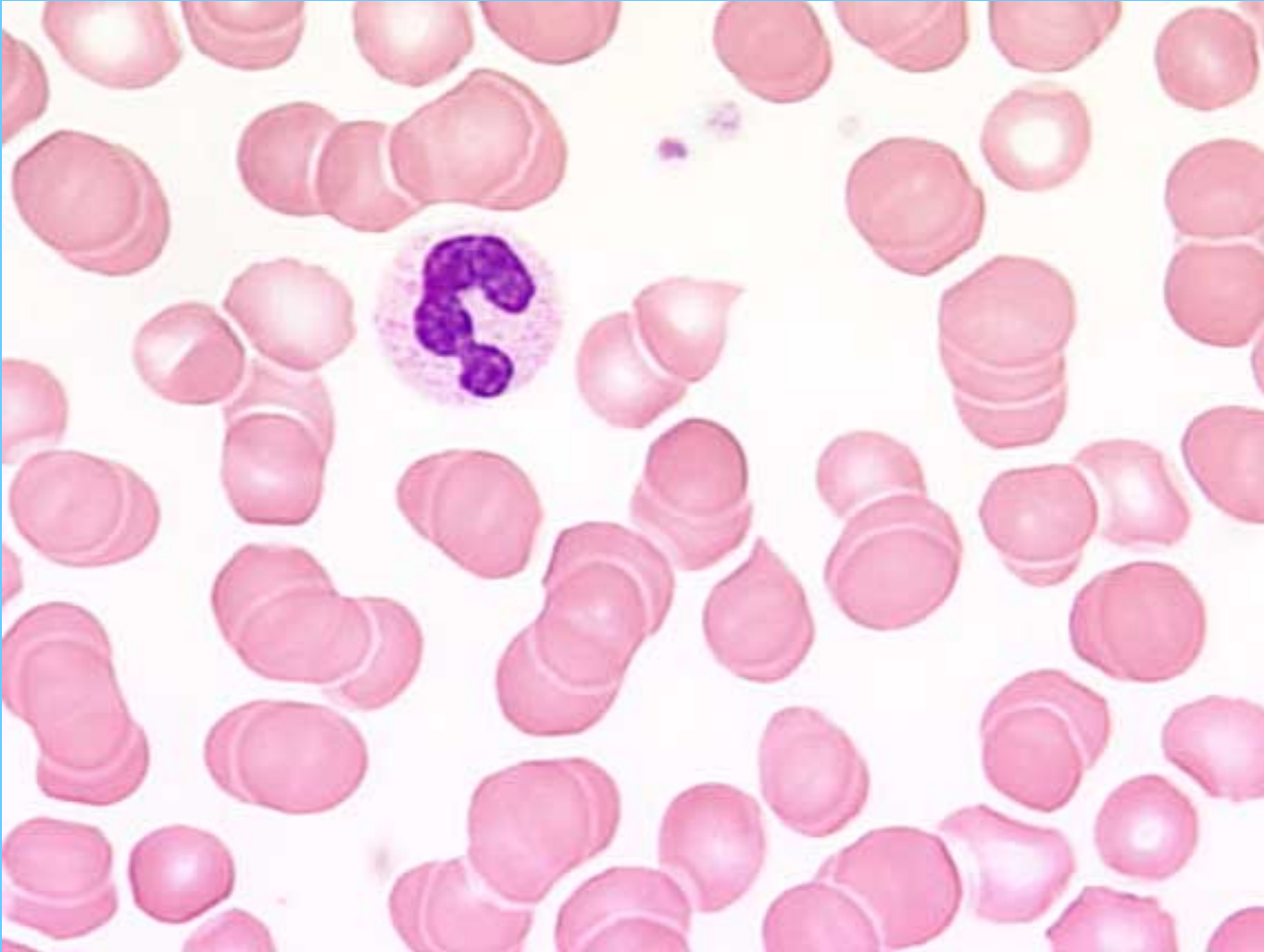
N. En banda (1)- N. segmentado (2)



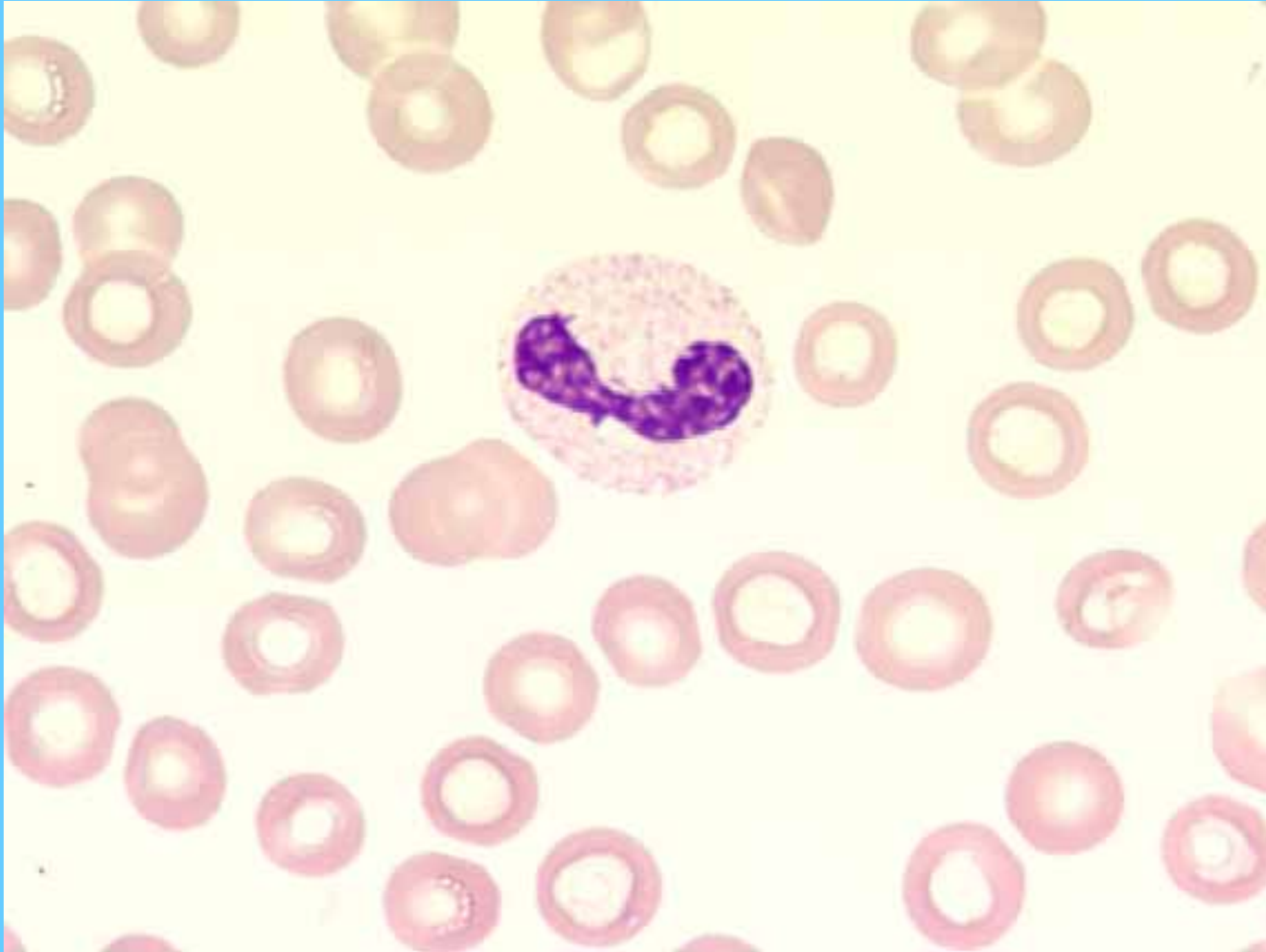
Monocito



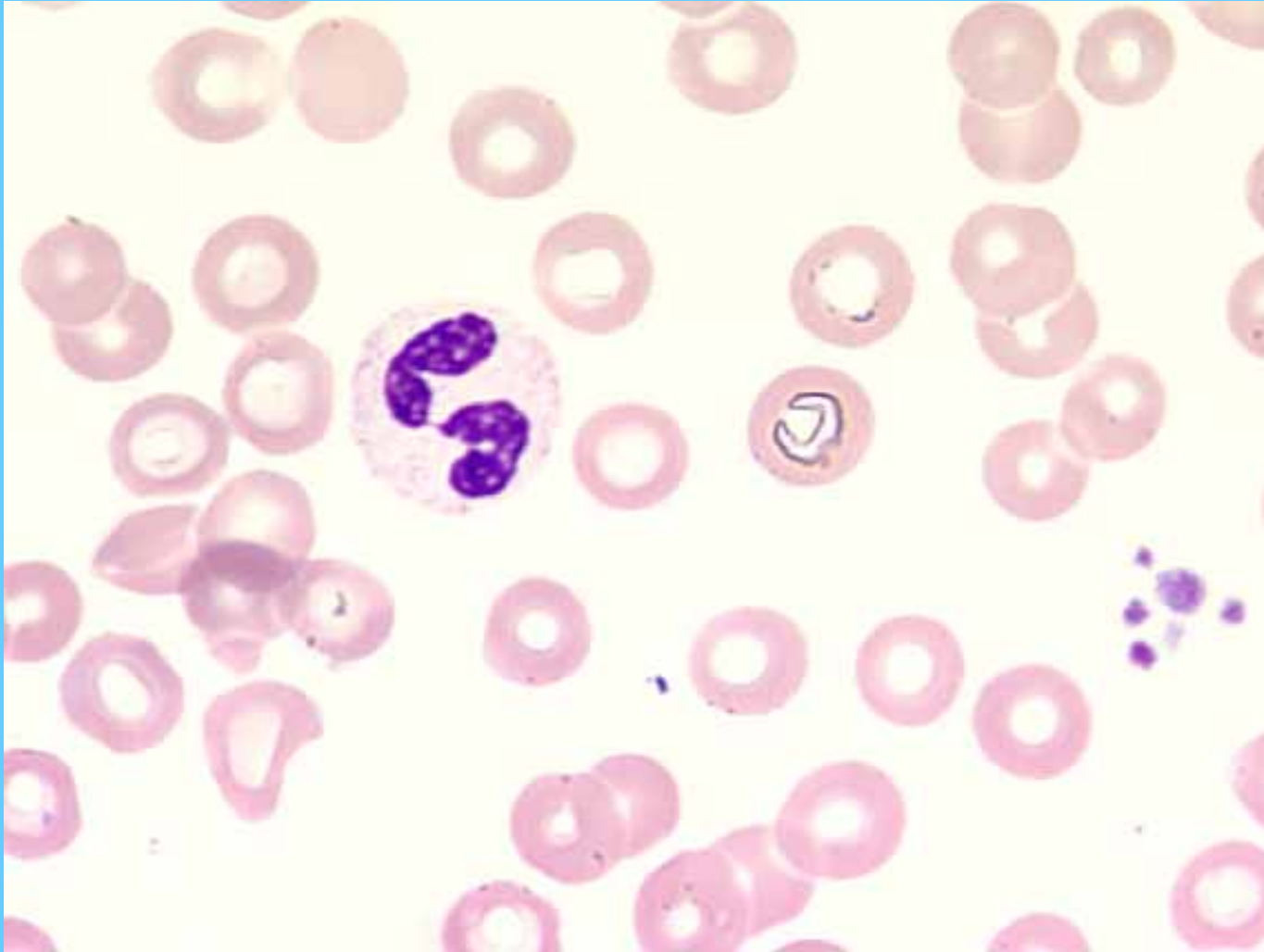
Banda



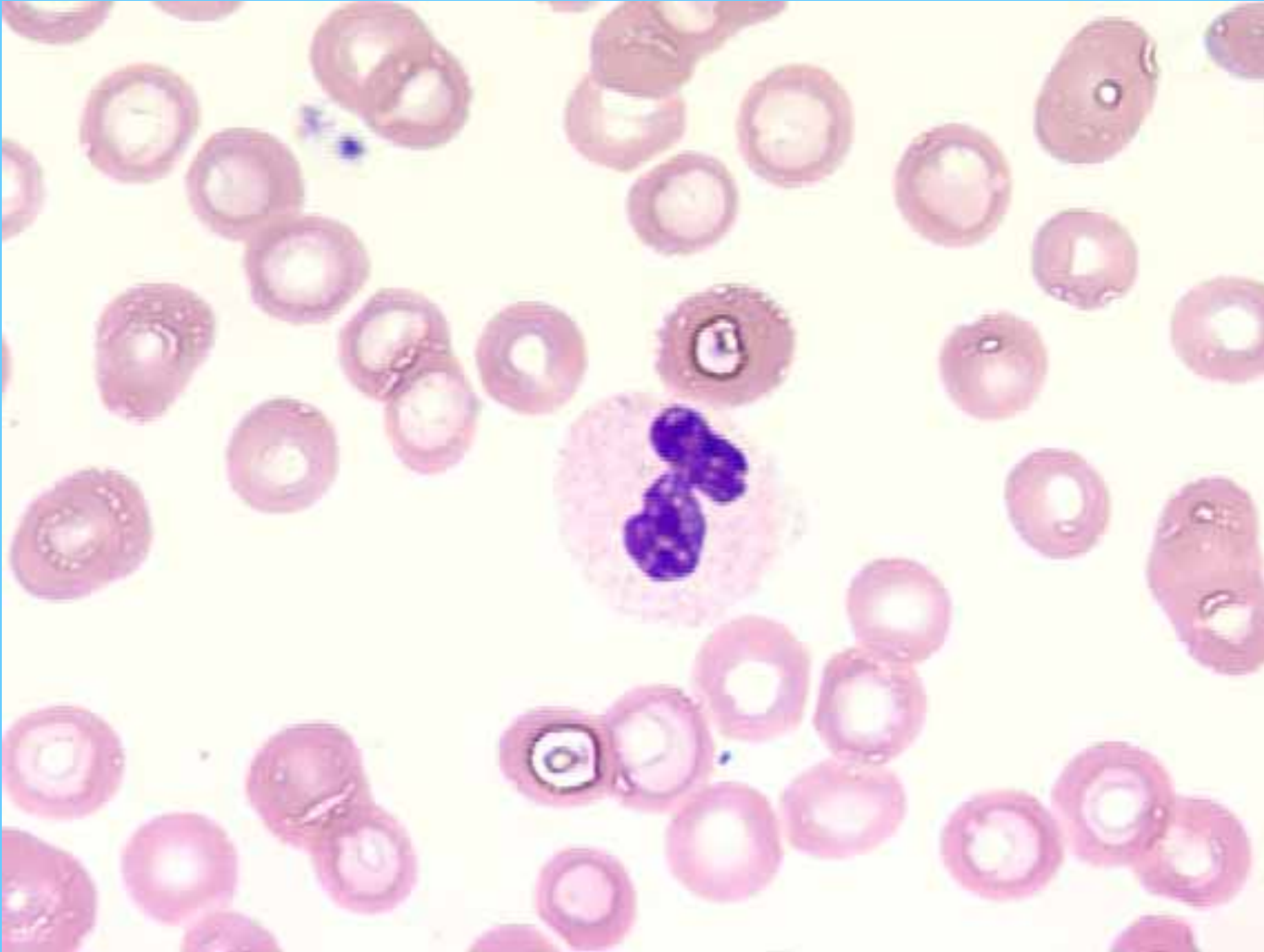
Banda



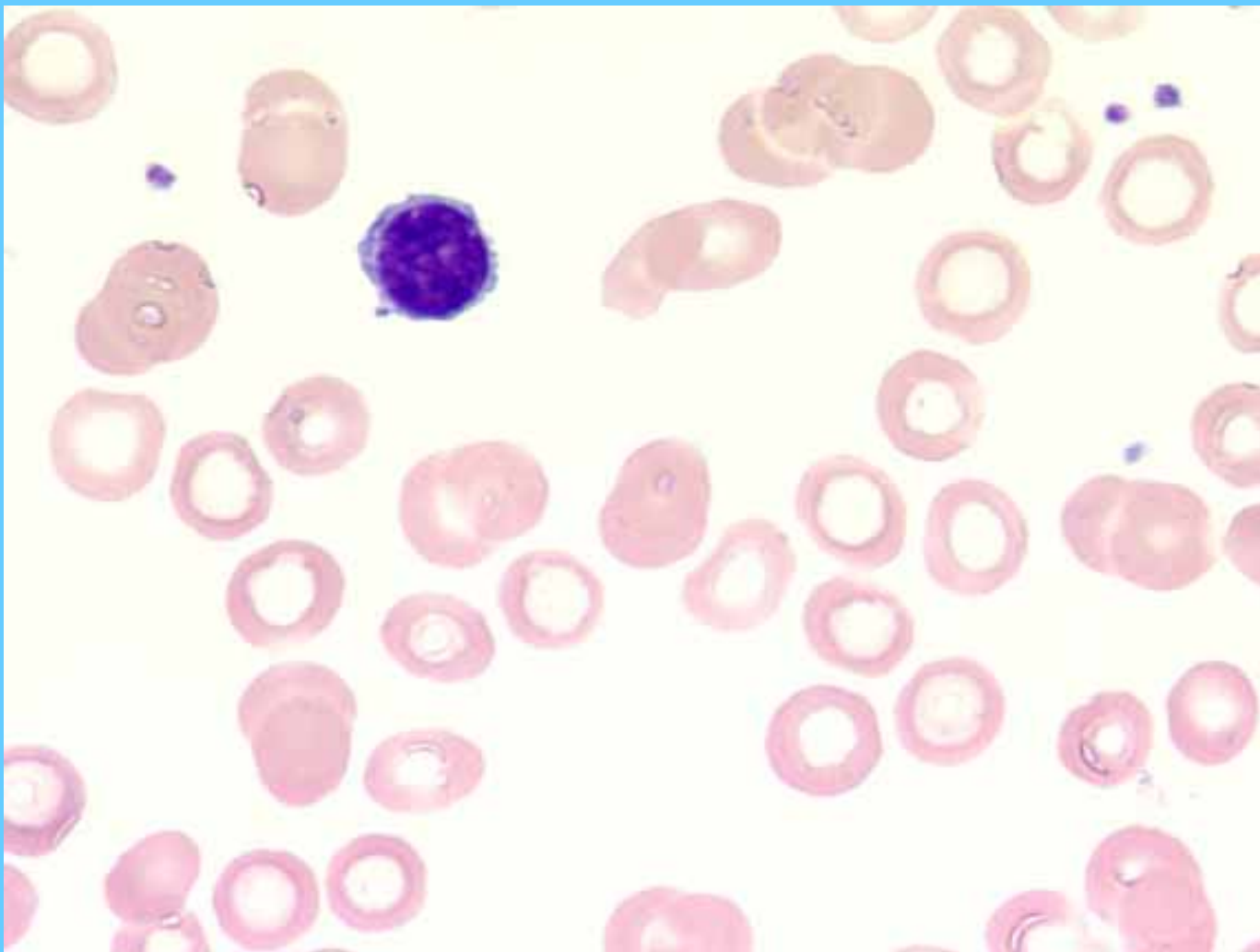
N. Segmentado



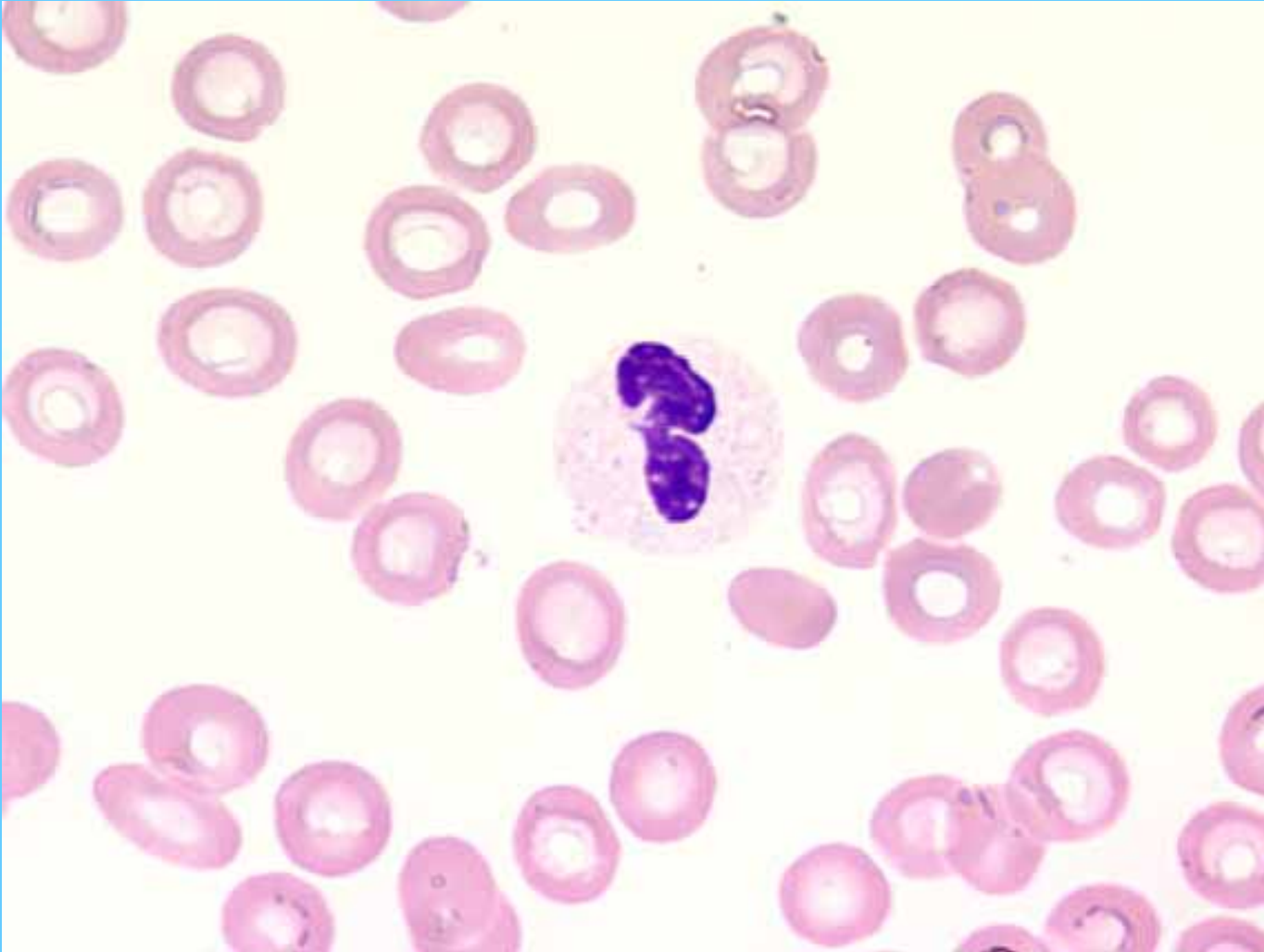
N. Segmentado



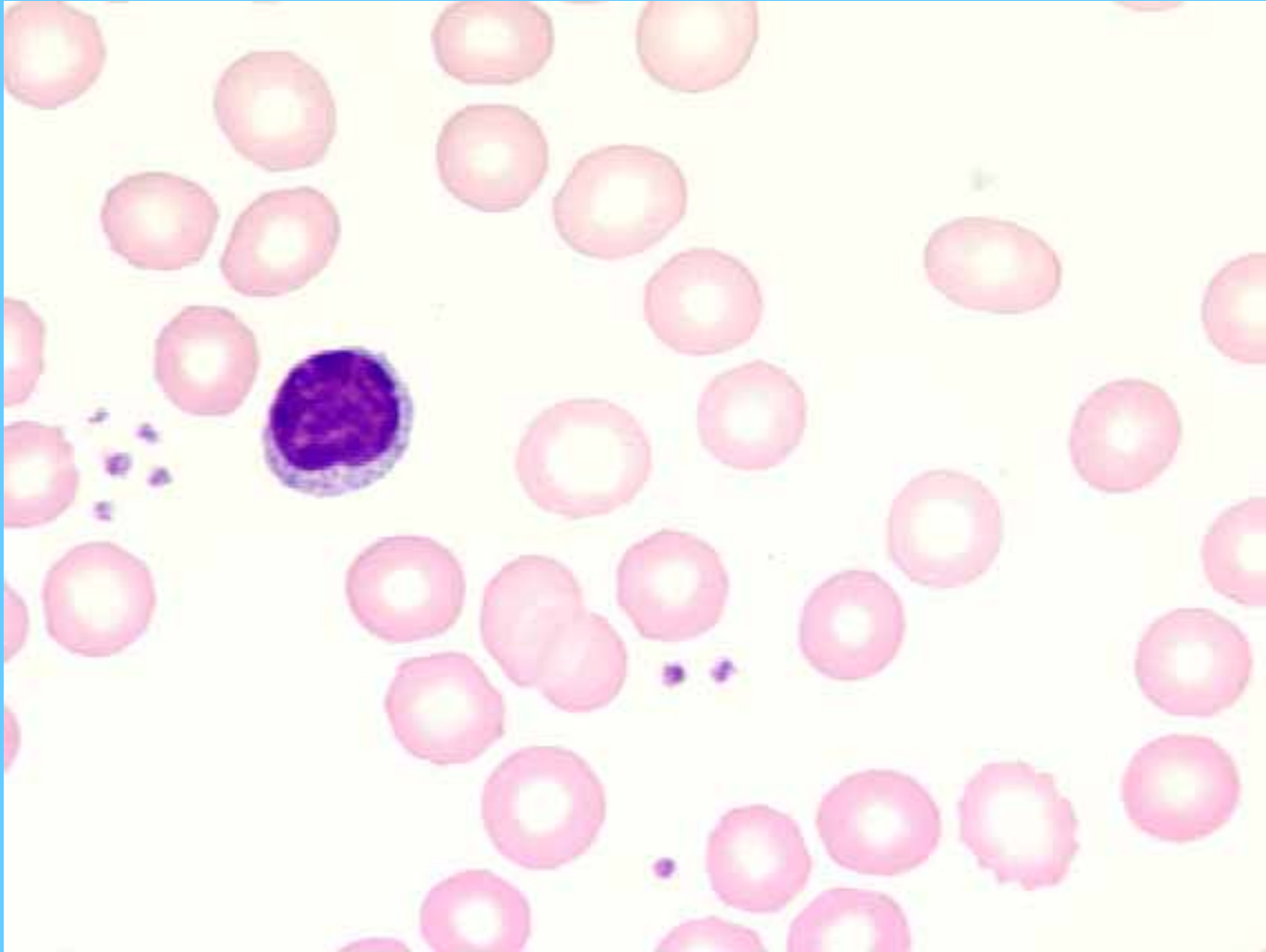
Linfocito



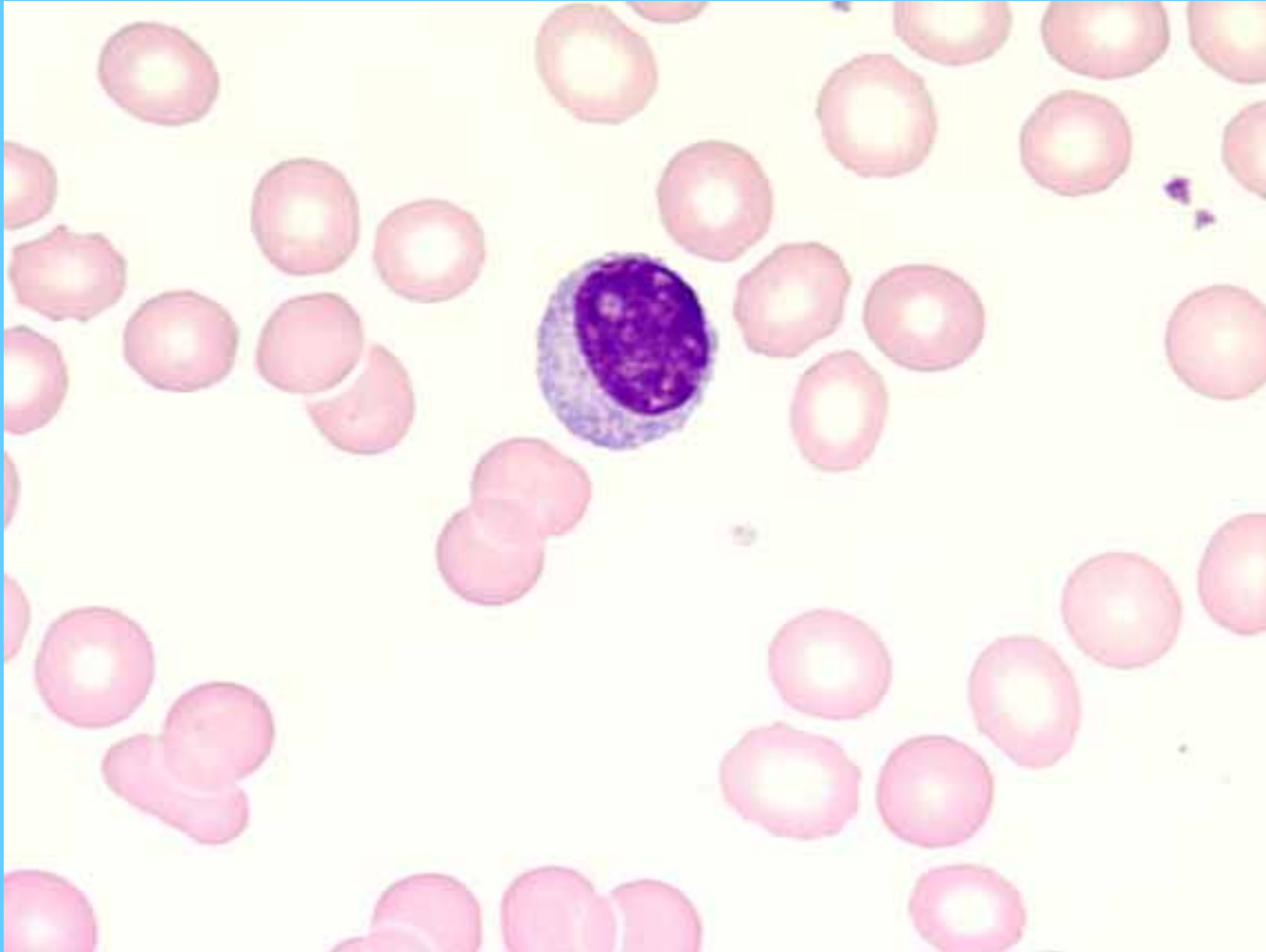
N. Segmentado



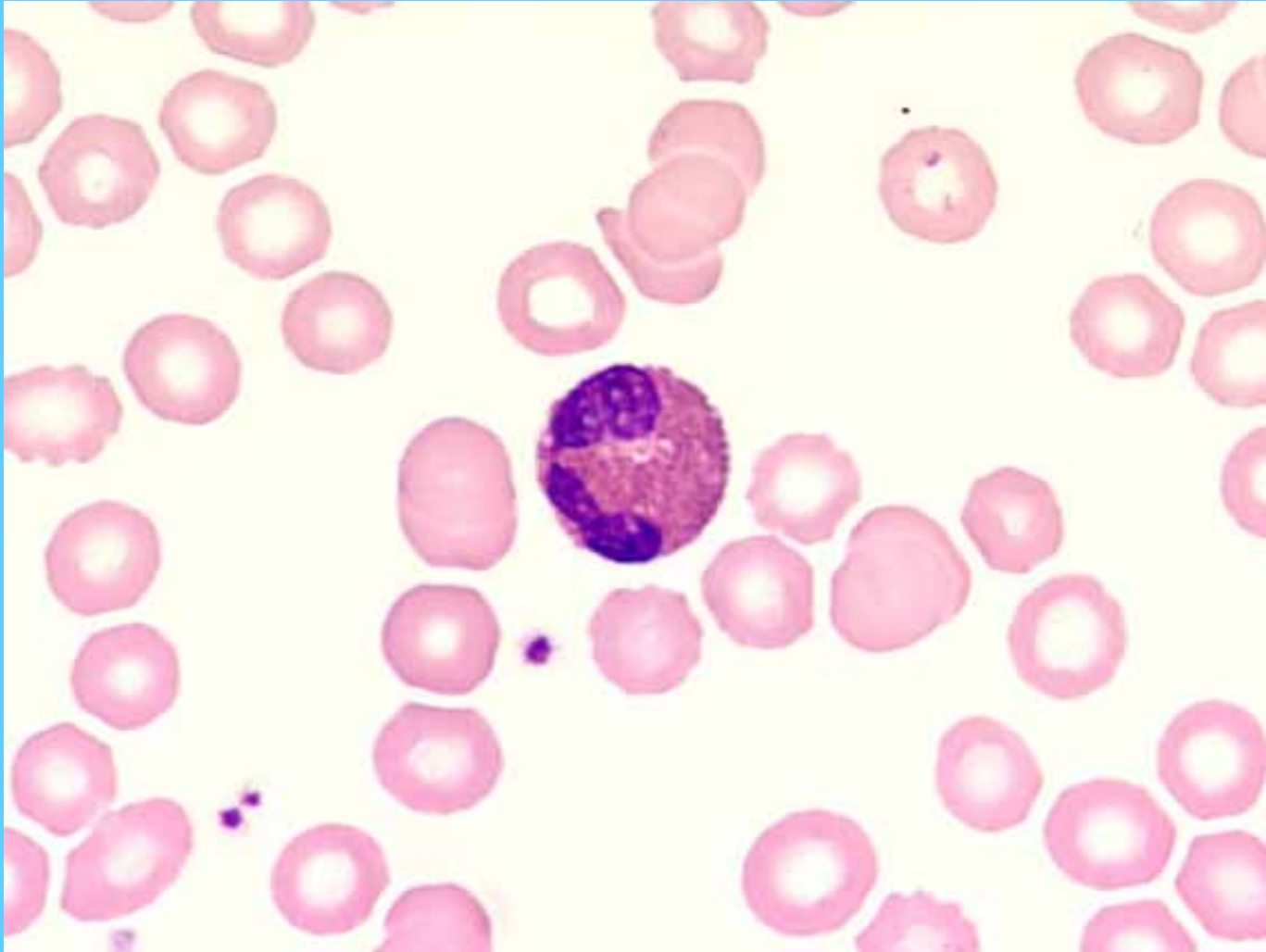
Linfocito



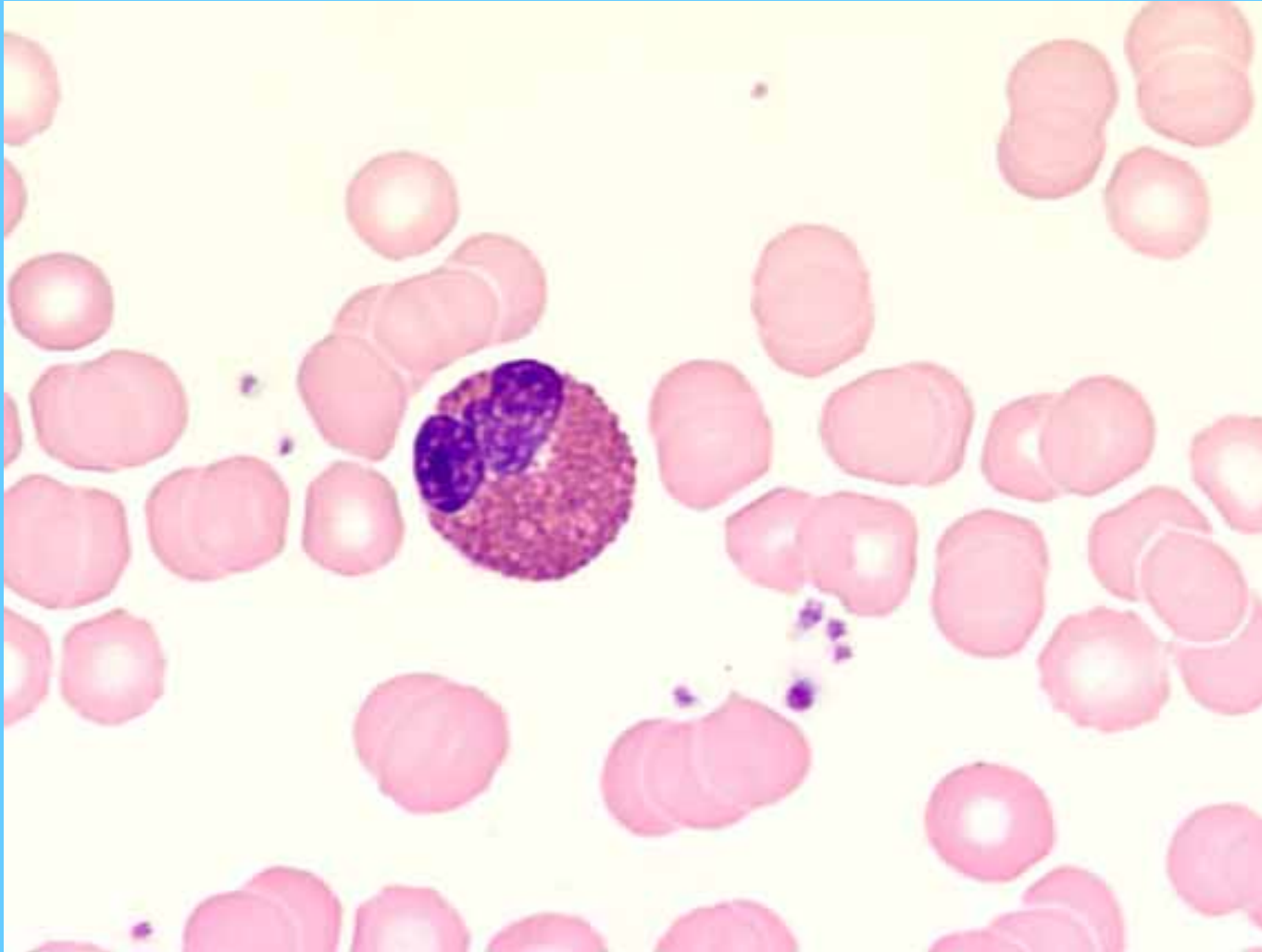
Linfocito



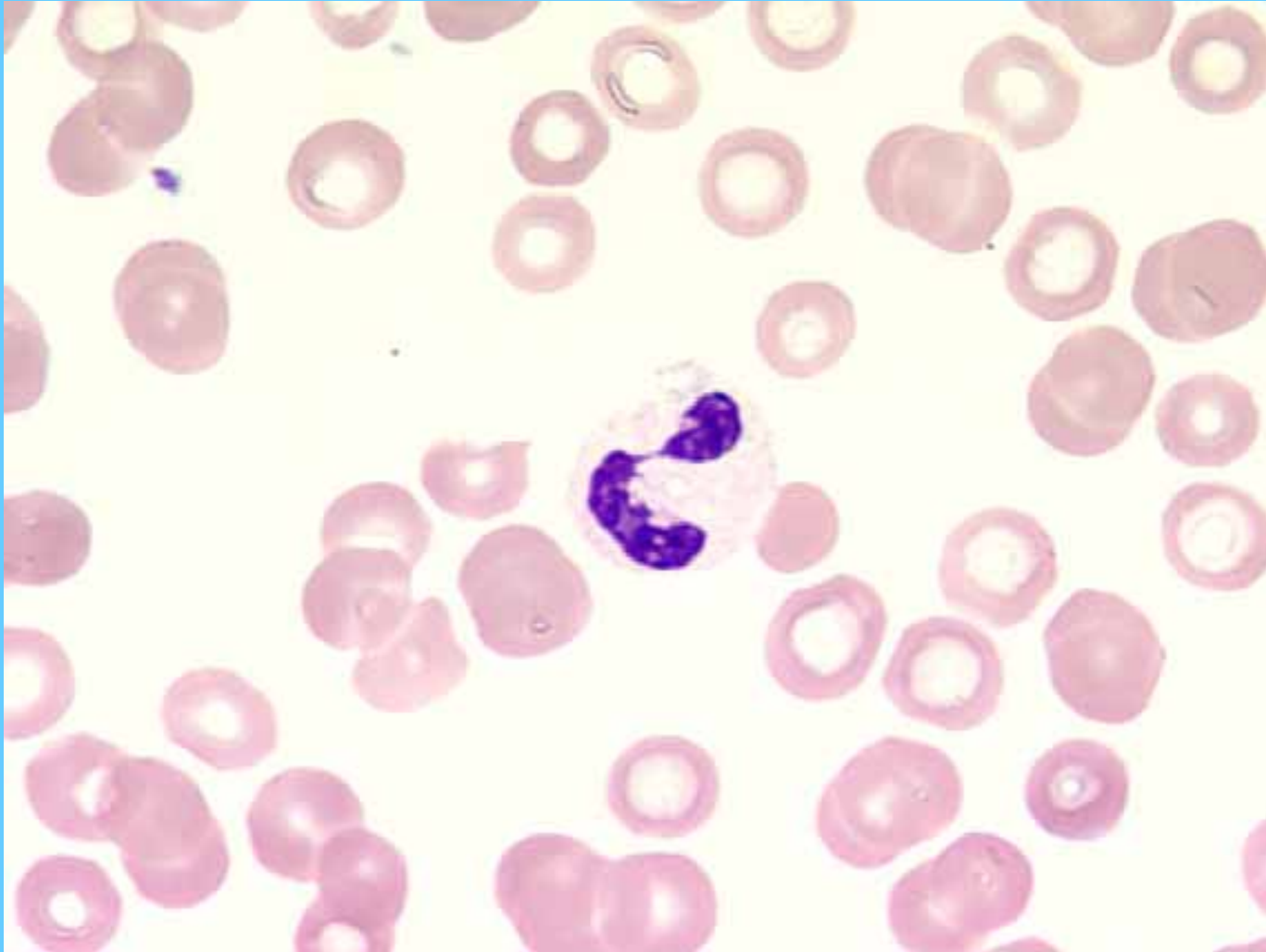Eosinófilo



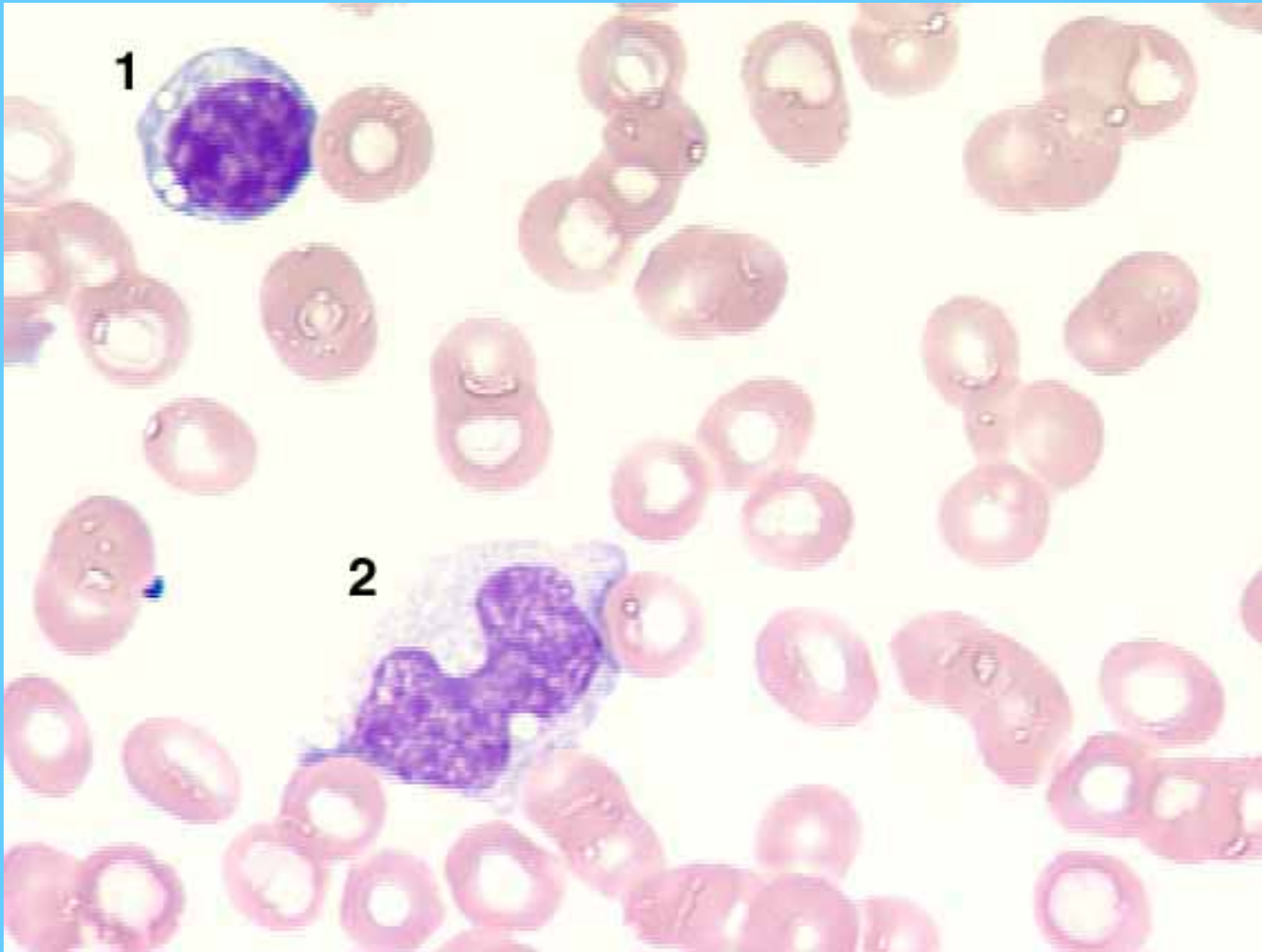
Eosinófilo



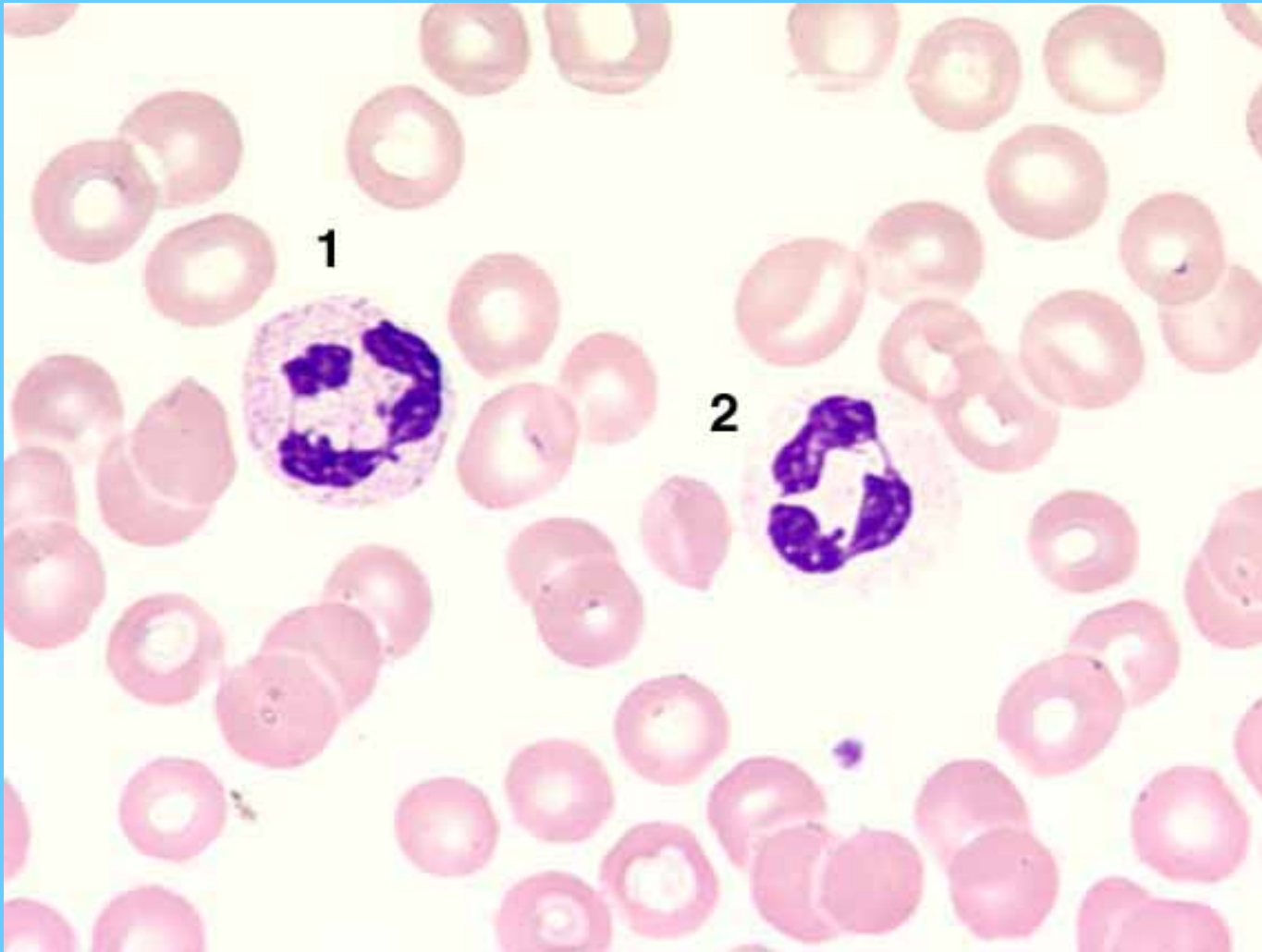
N. segmentado



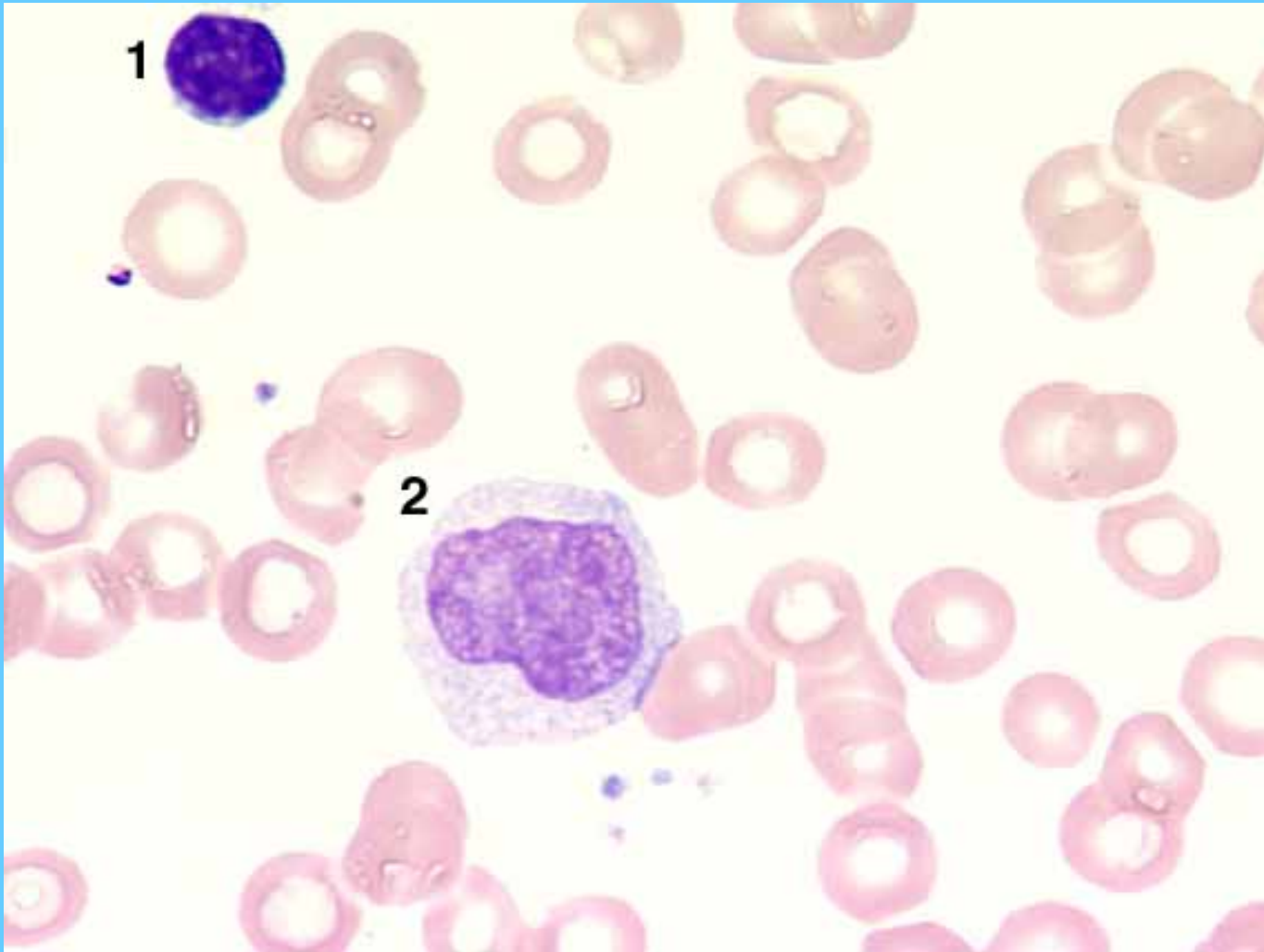
Linfocito (1) – Monocito (2)



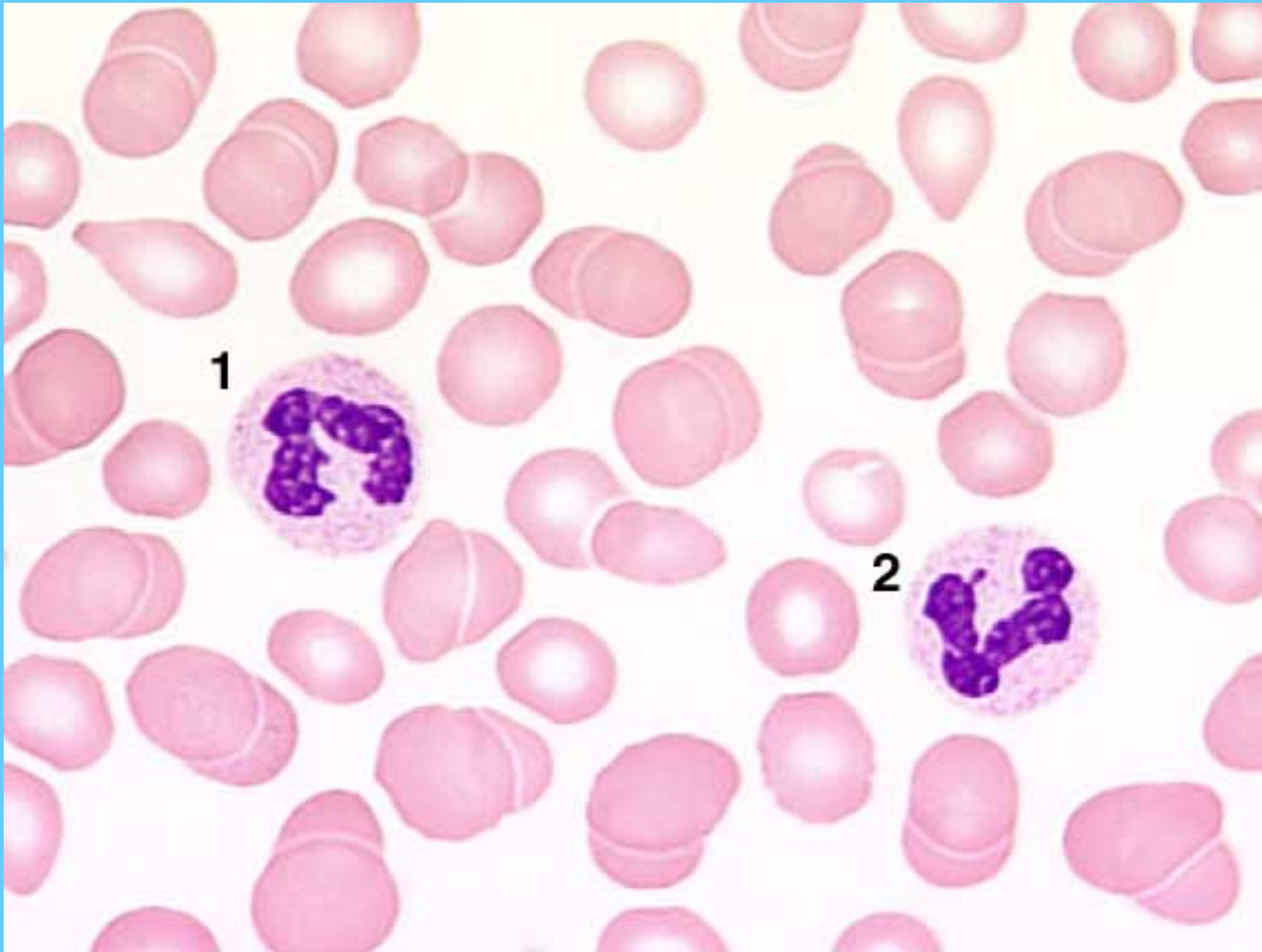
Neutrófilos segmentados



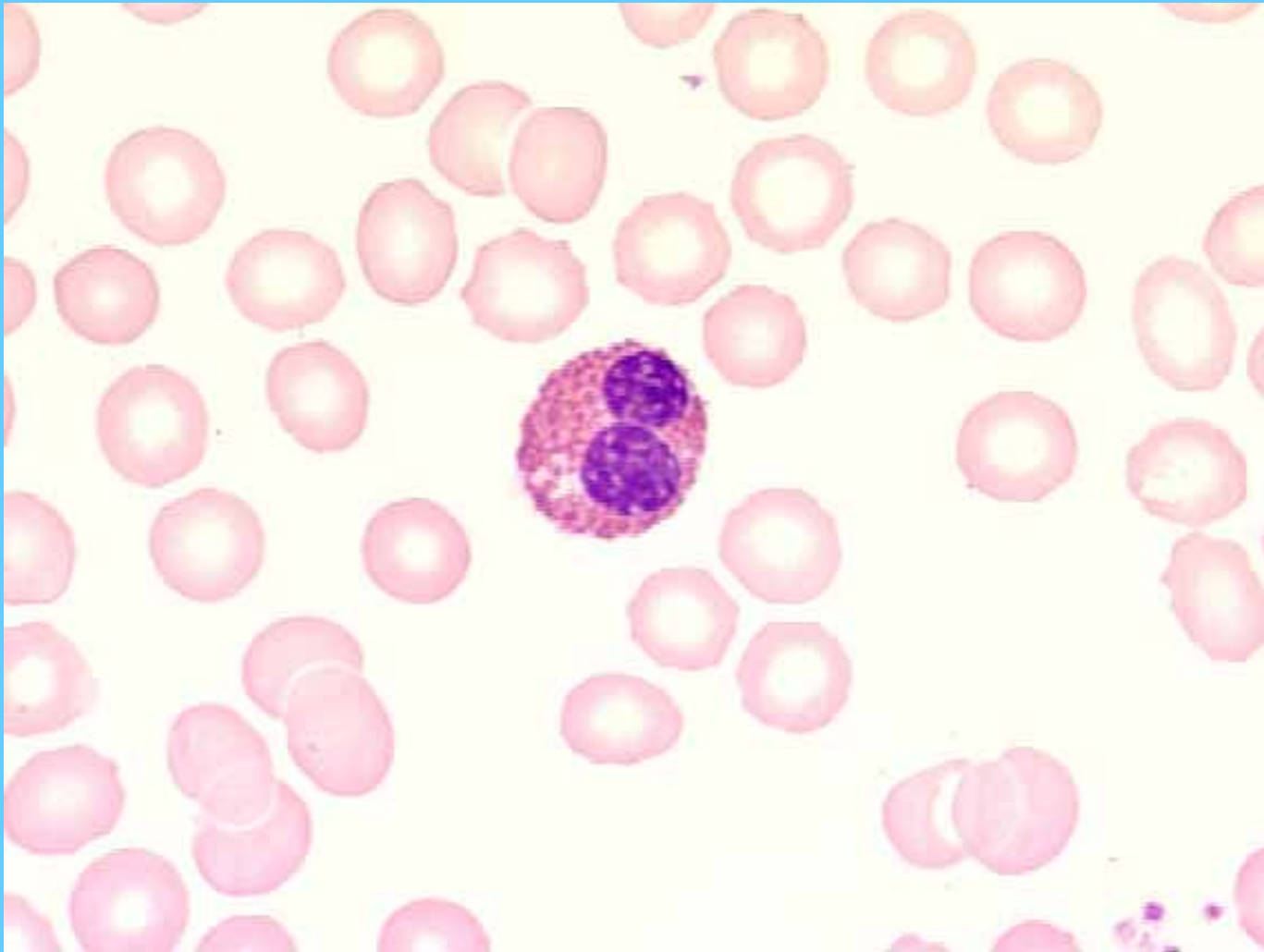
Linfocito (1) – Monocito (2)

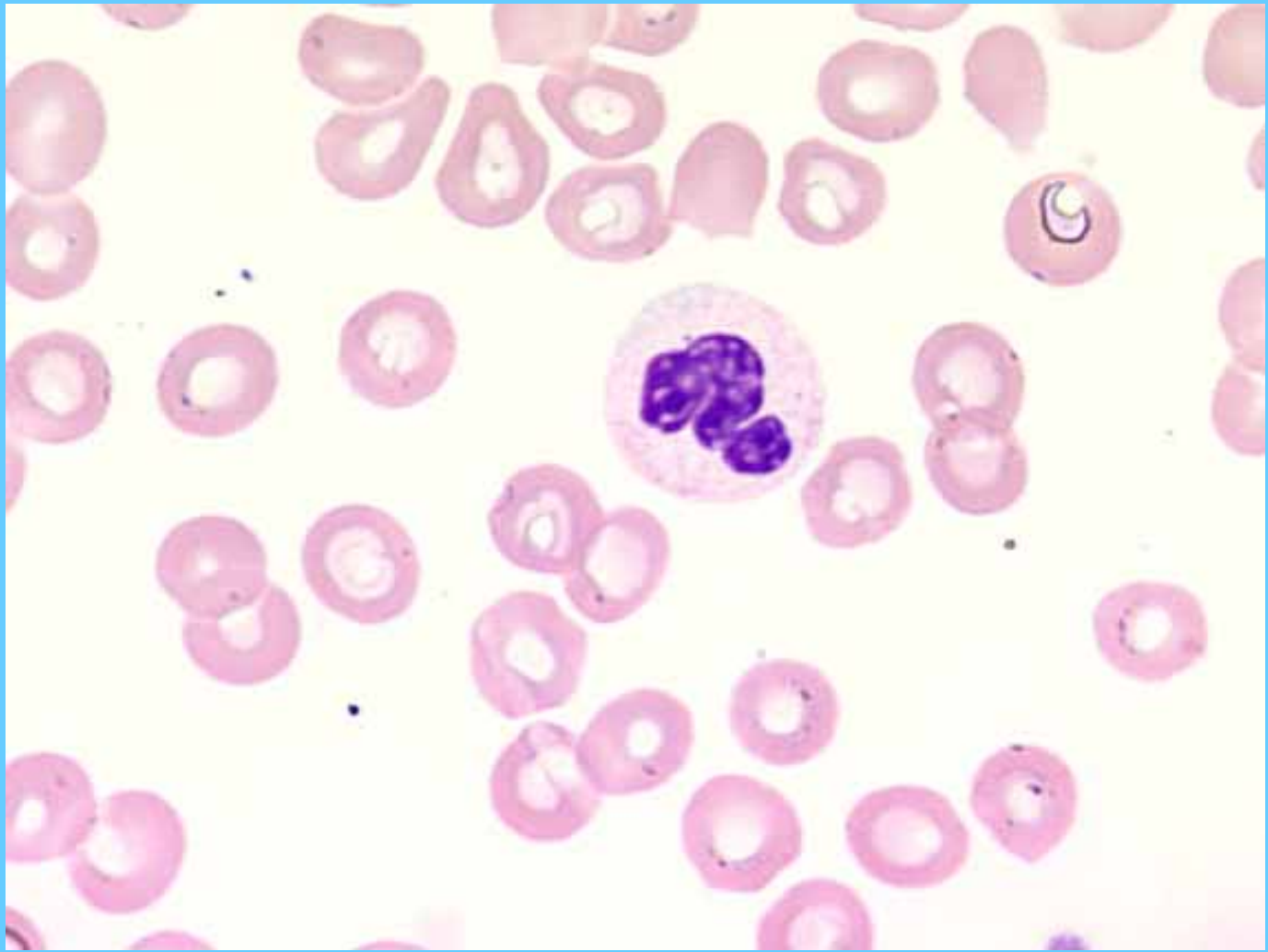


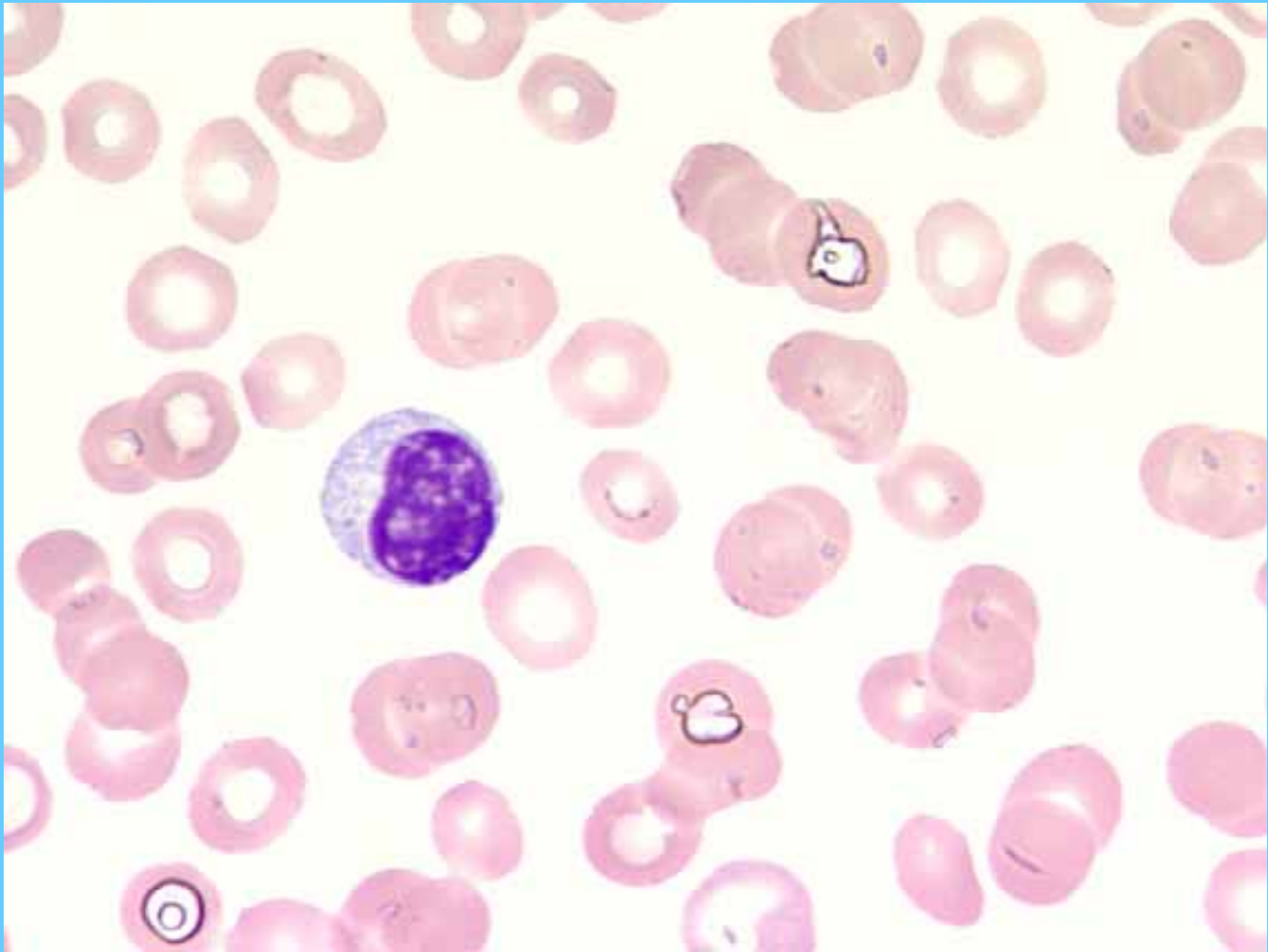
N. Segmentado (2) – N. en banda (1)

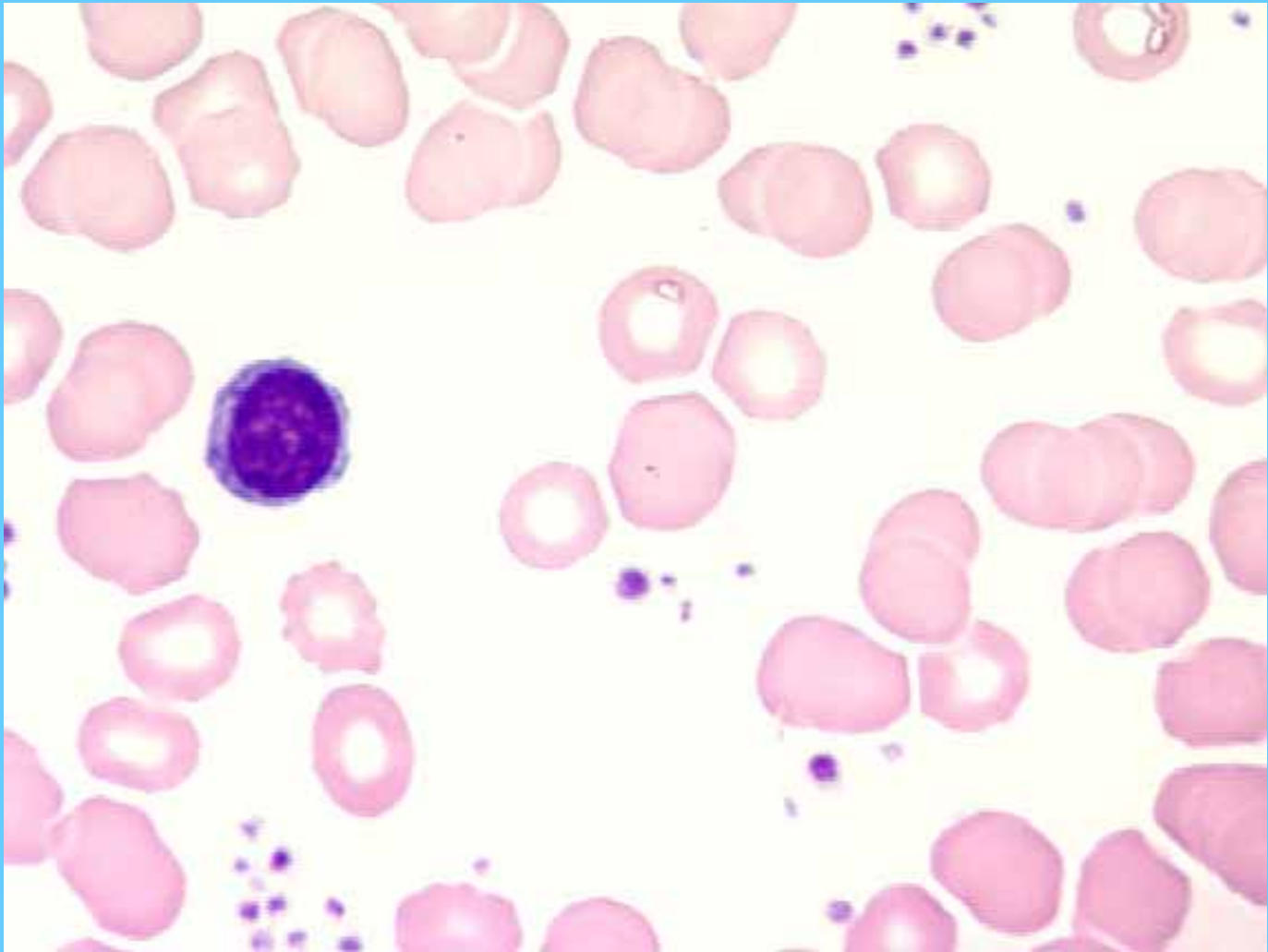


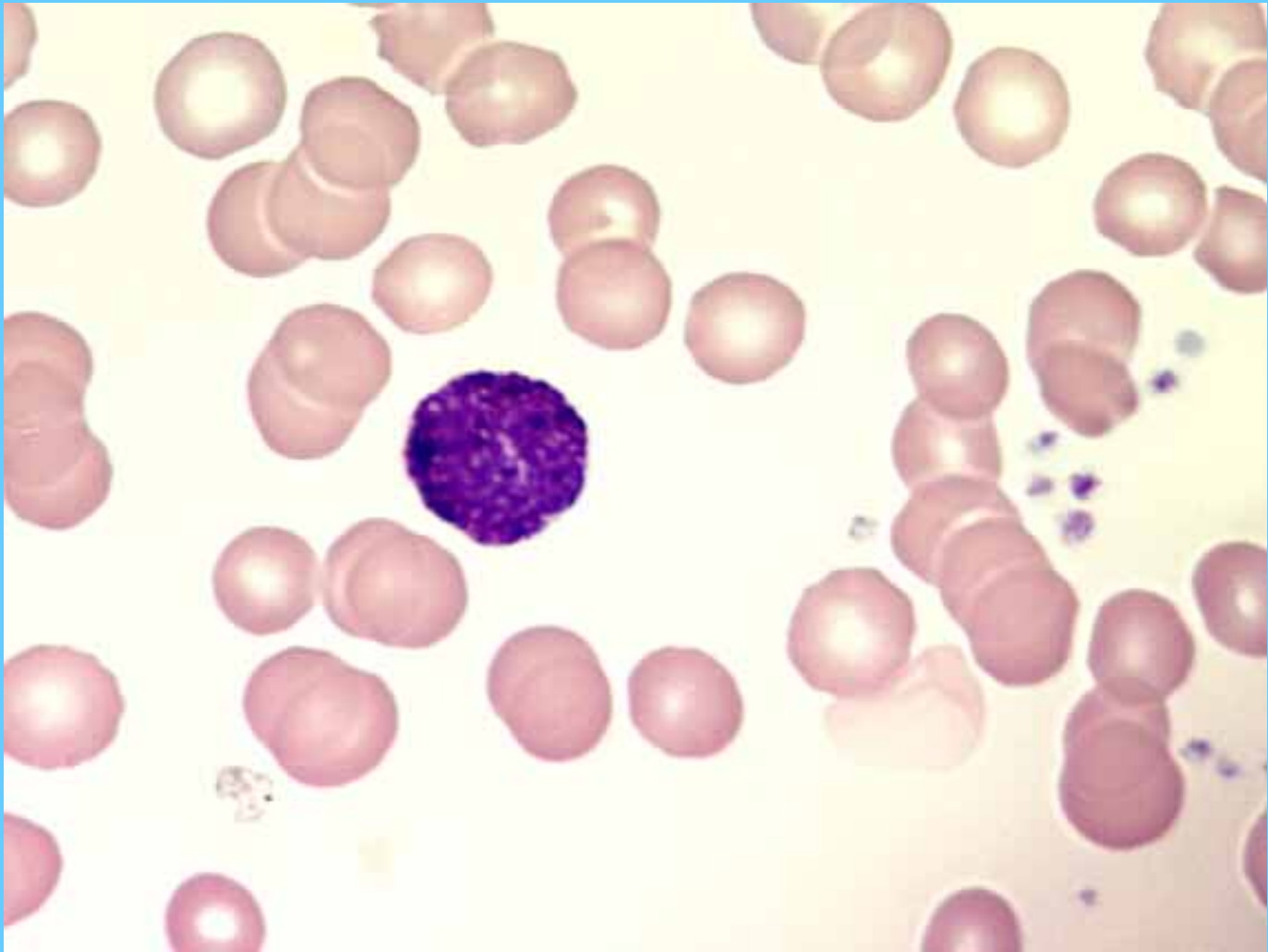
Eosinófilo

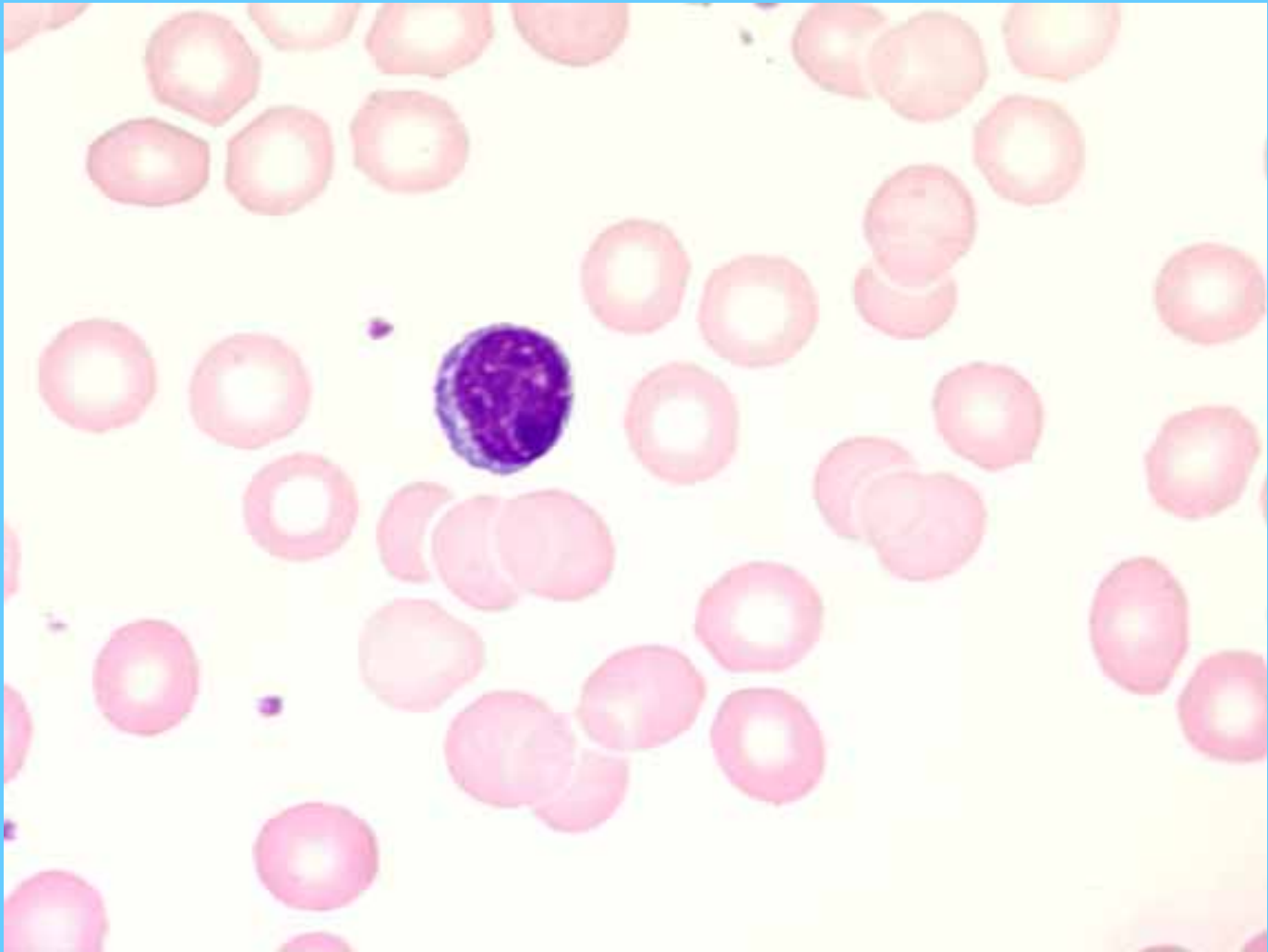

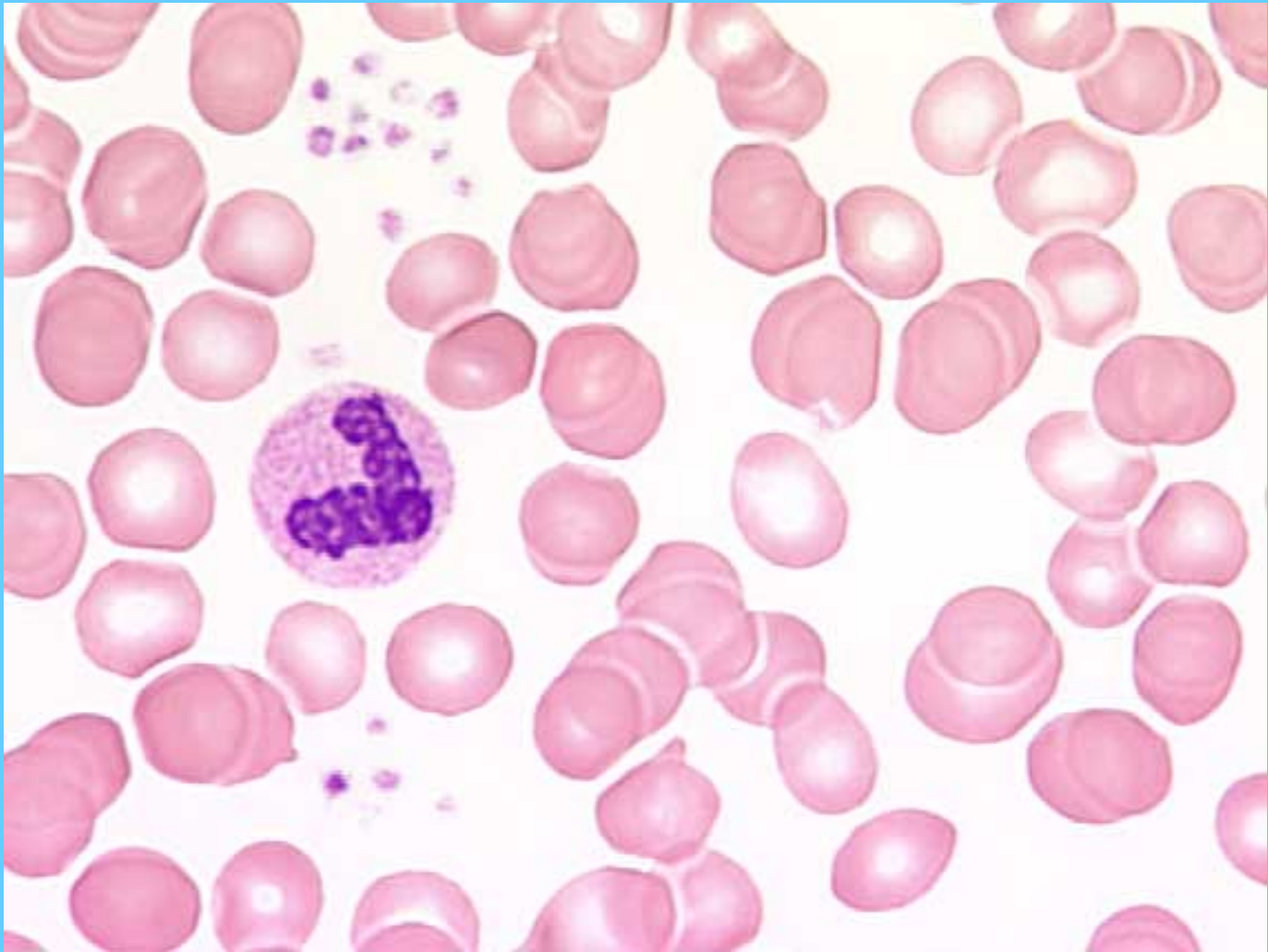


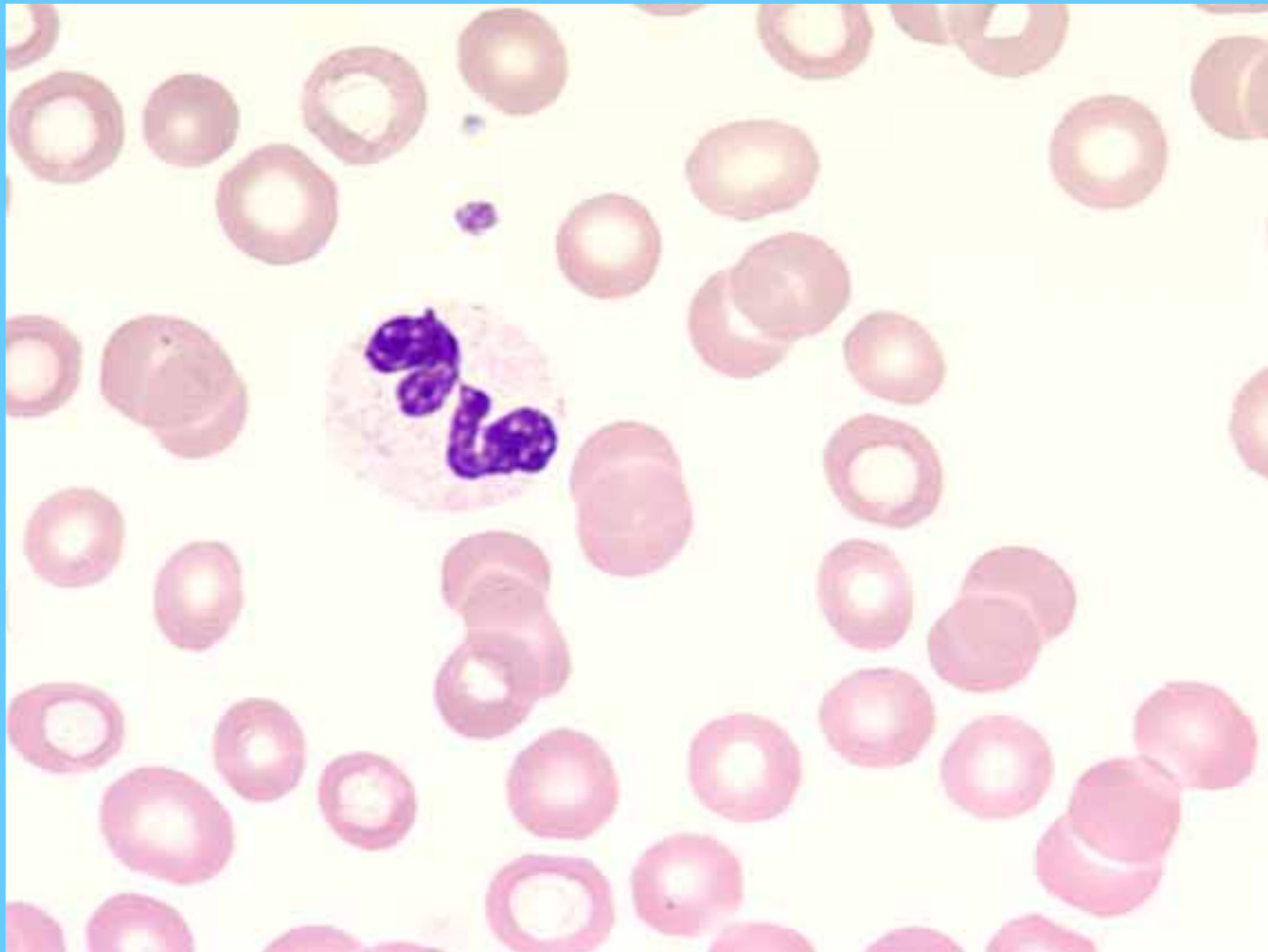


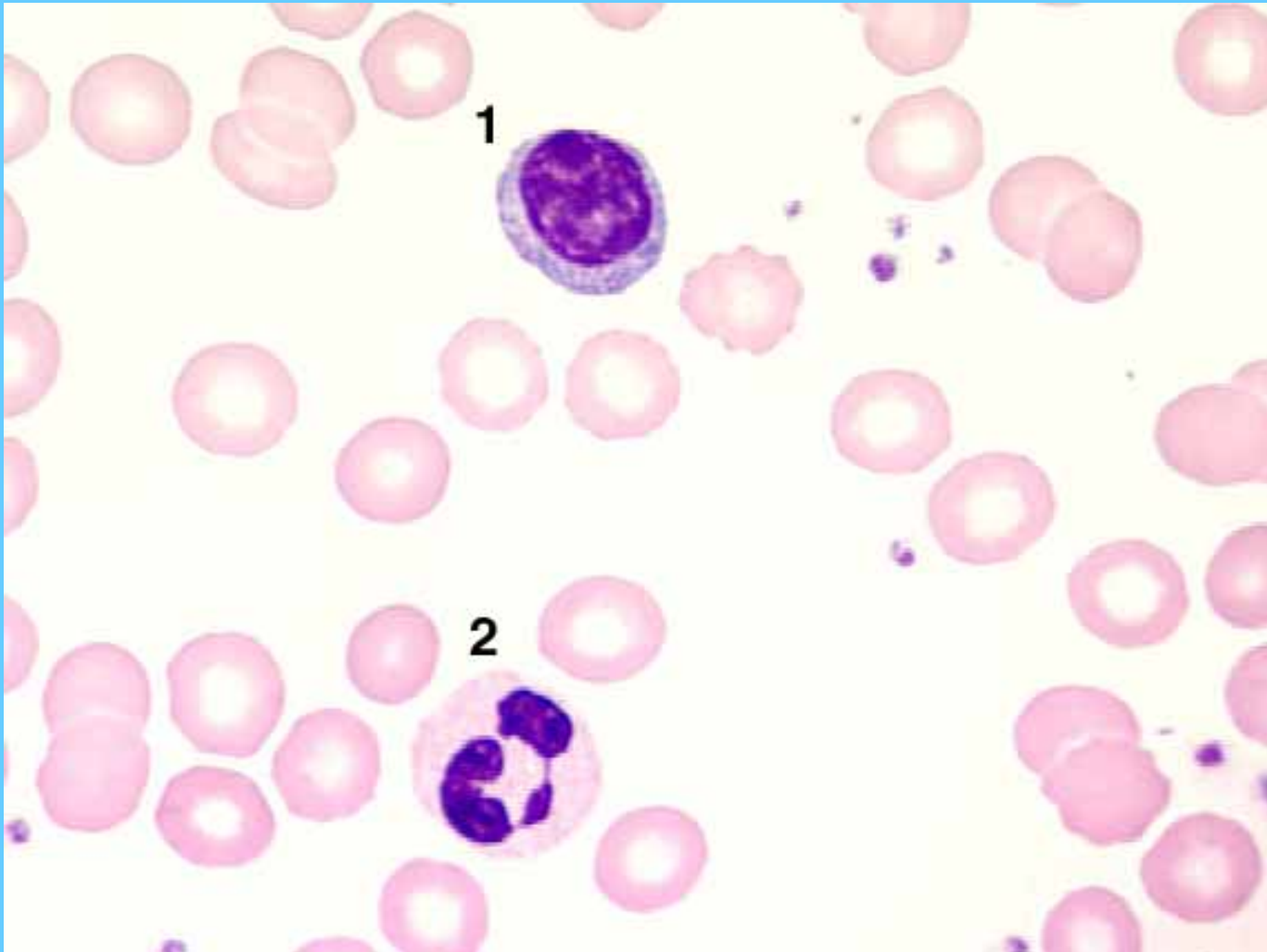



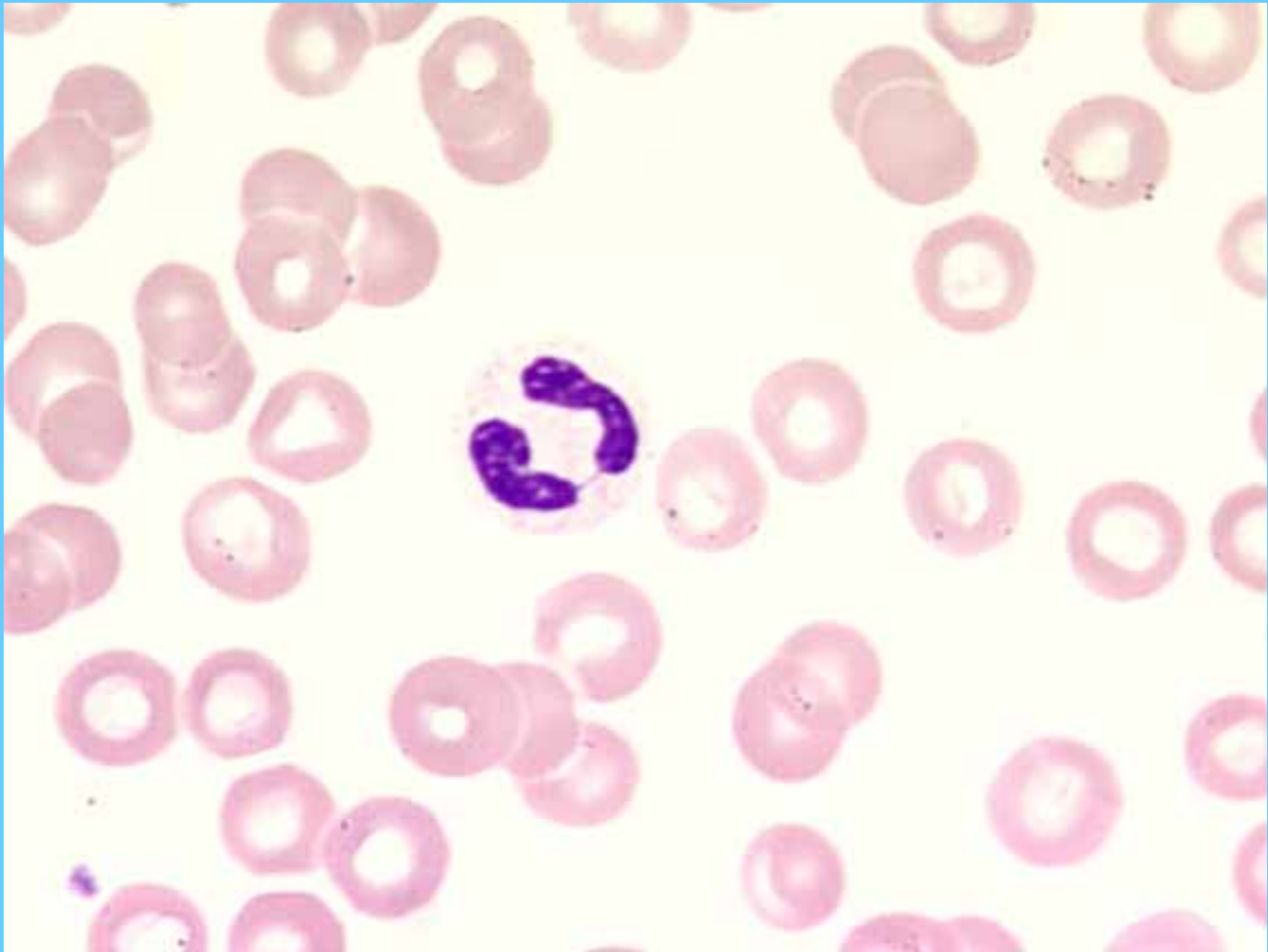


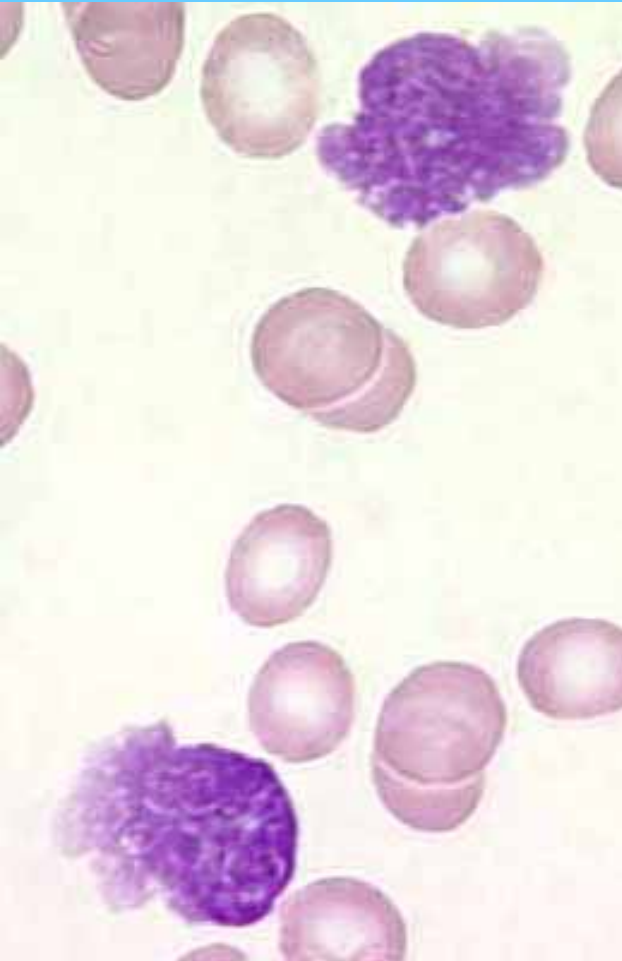

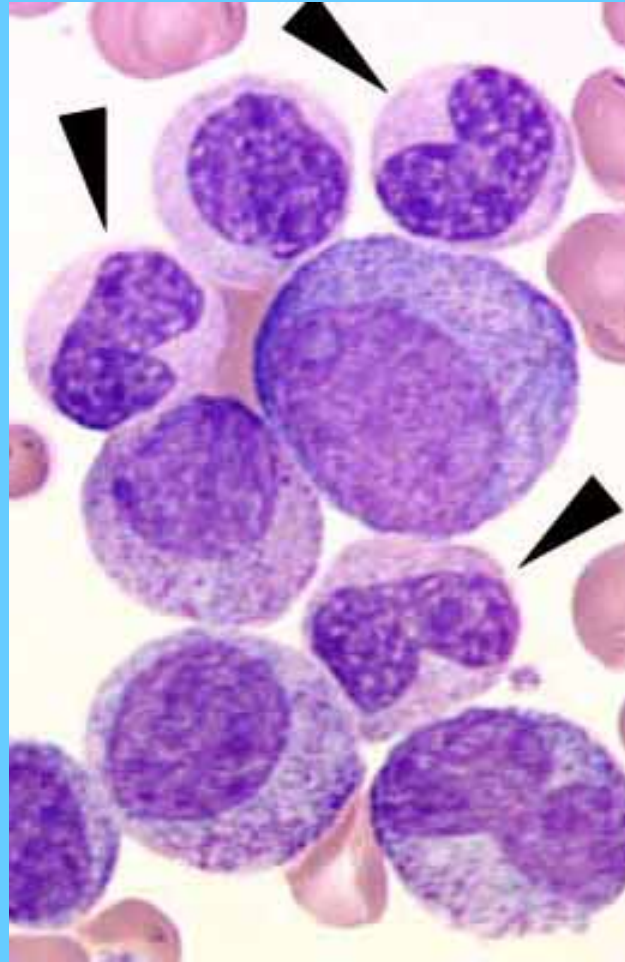




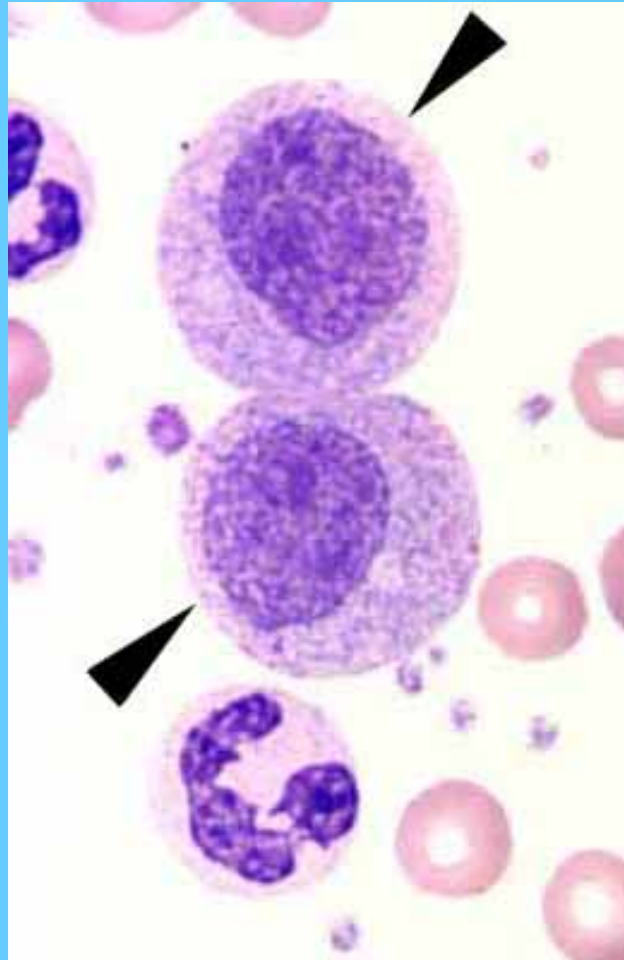




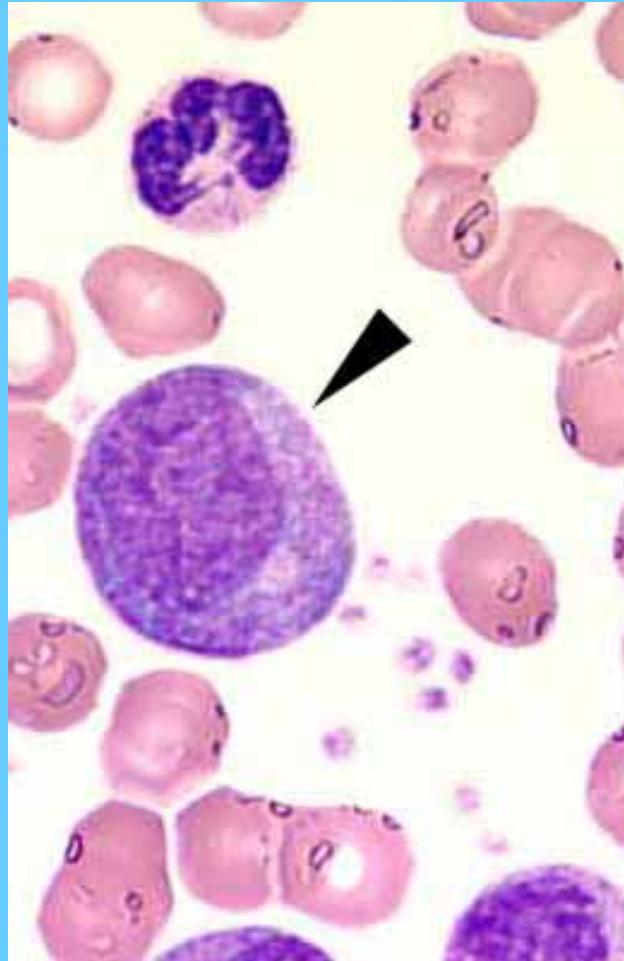
Precursores neutrófilos: promielocito, mielocitos, metamielocitos y bandas.

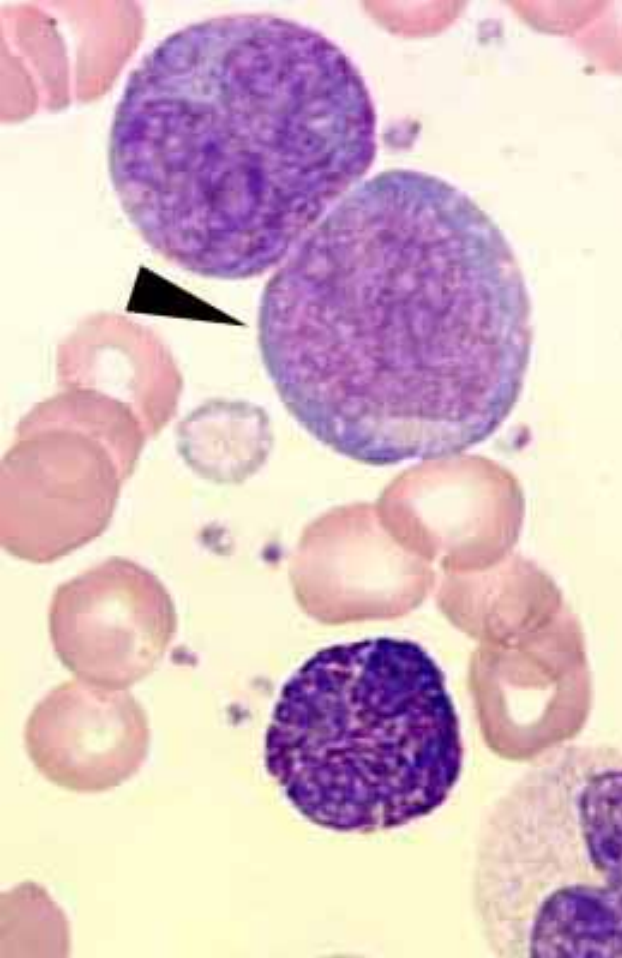


Mielocitos

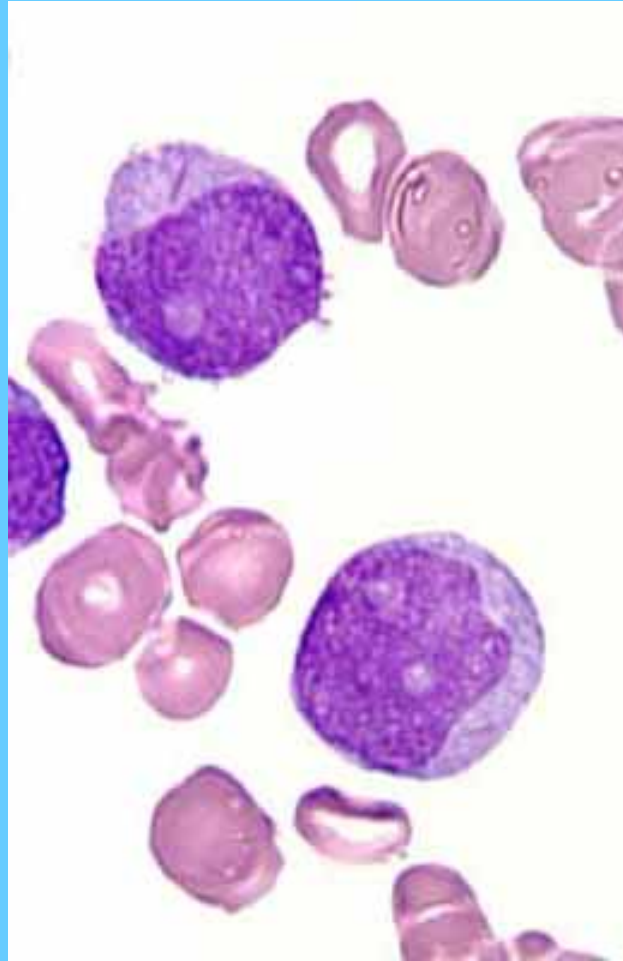


Promielocito

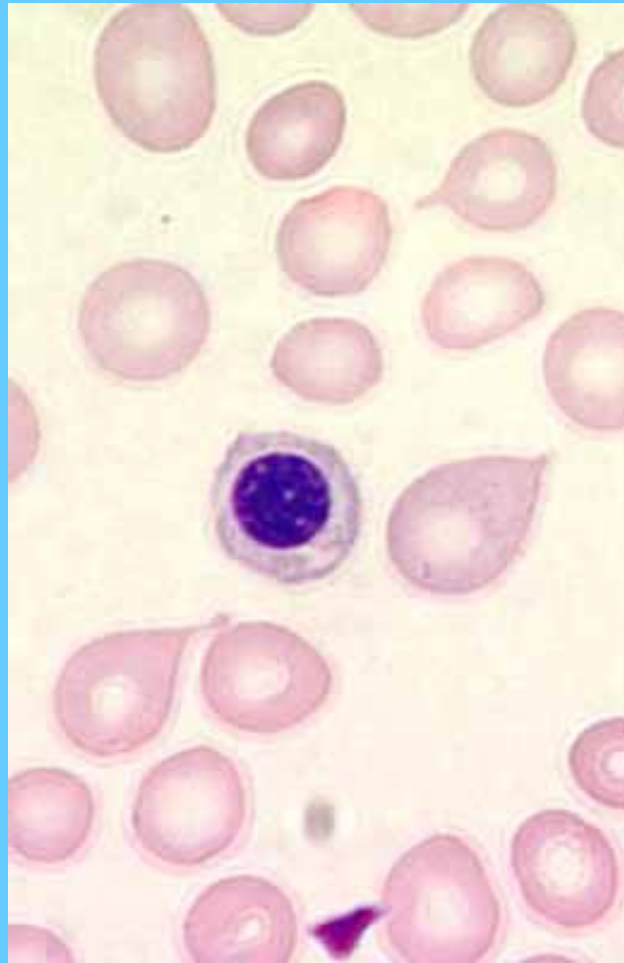




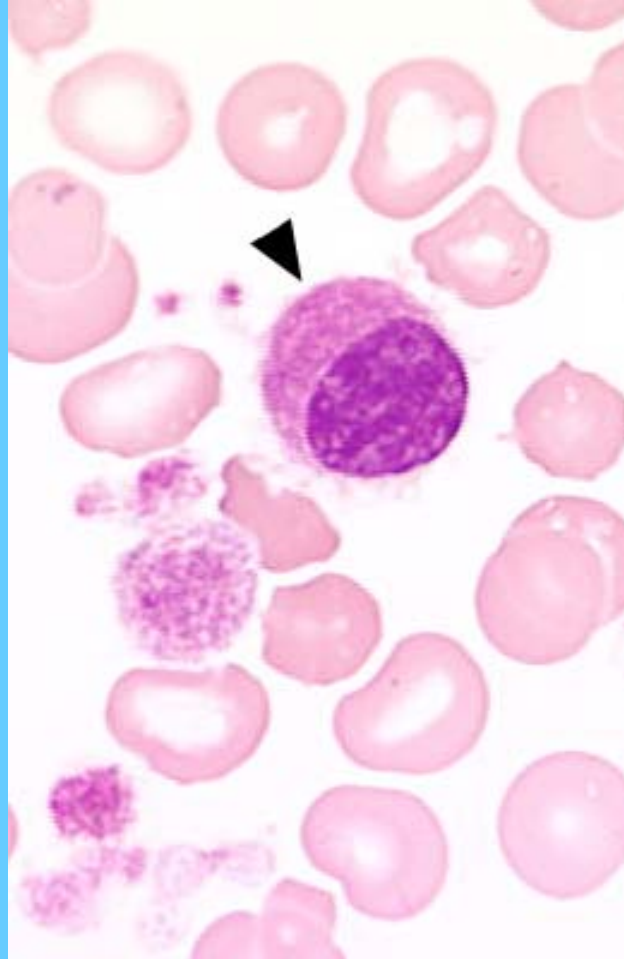
Mieloblastos, note los bastones de Auer



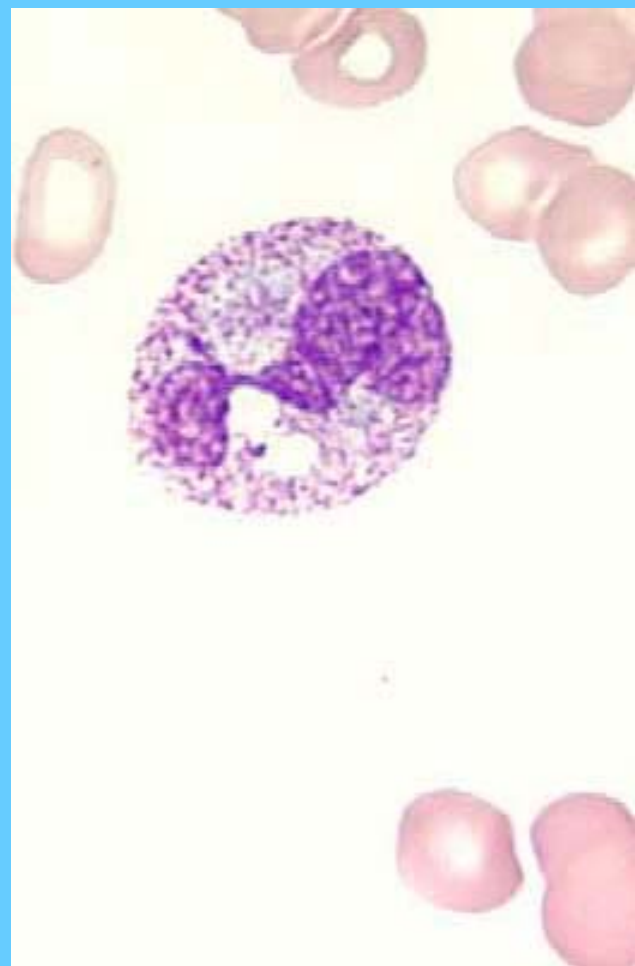
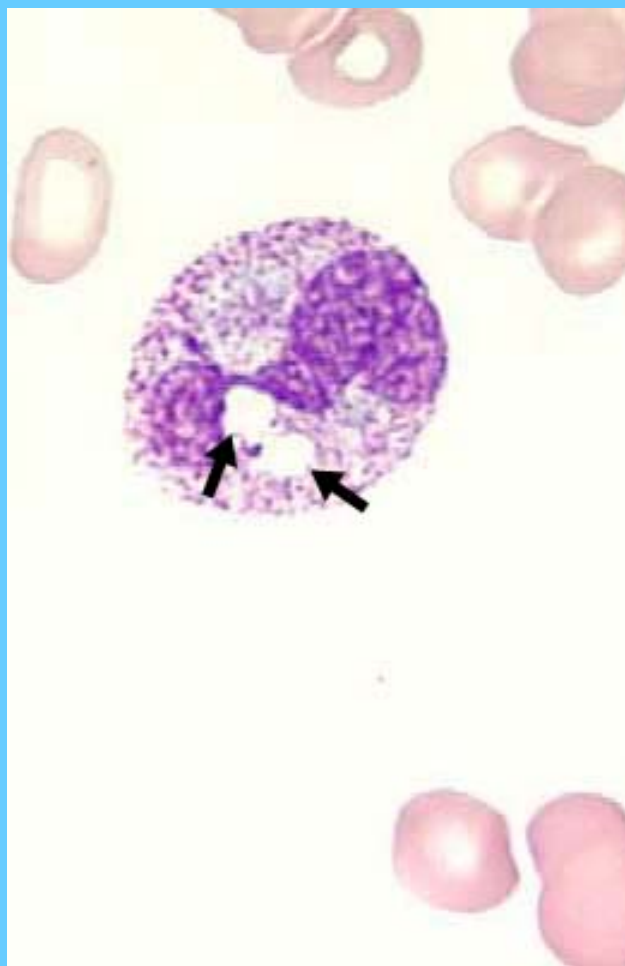
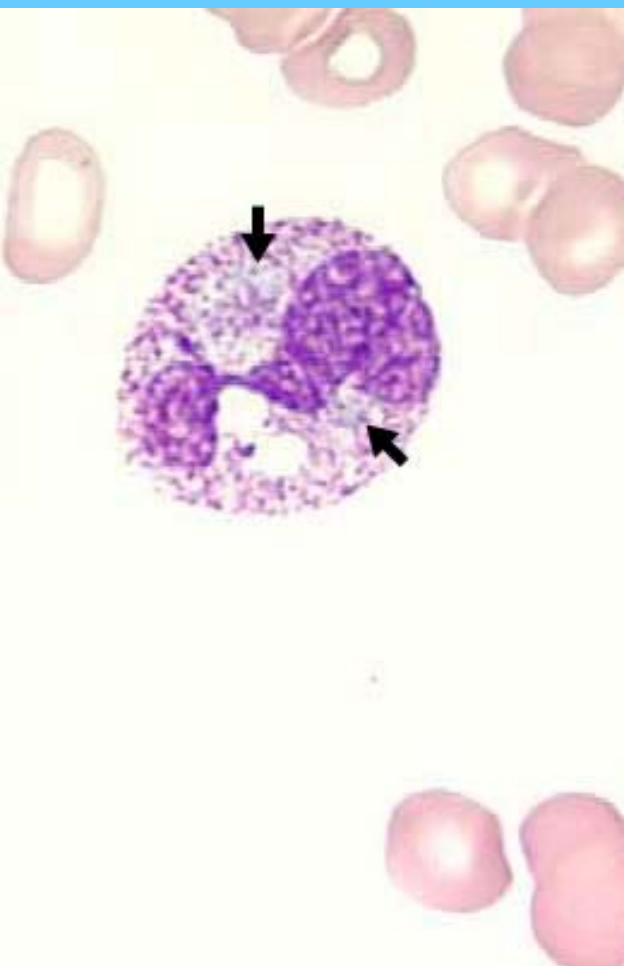
Eritroblasto

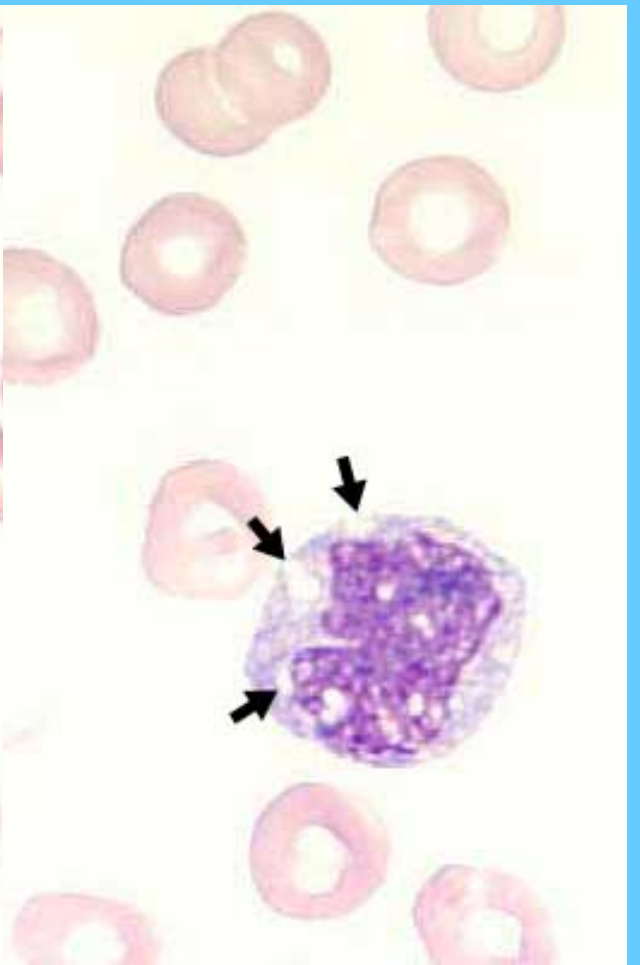
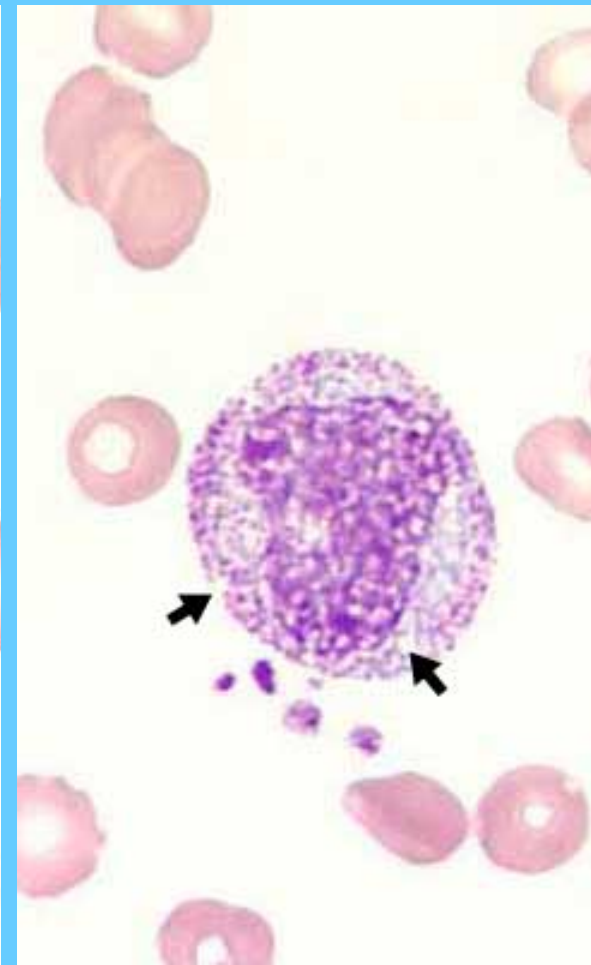
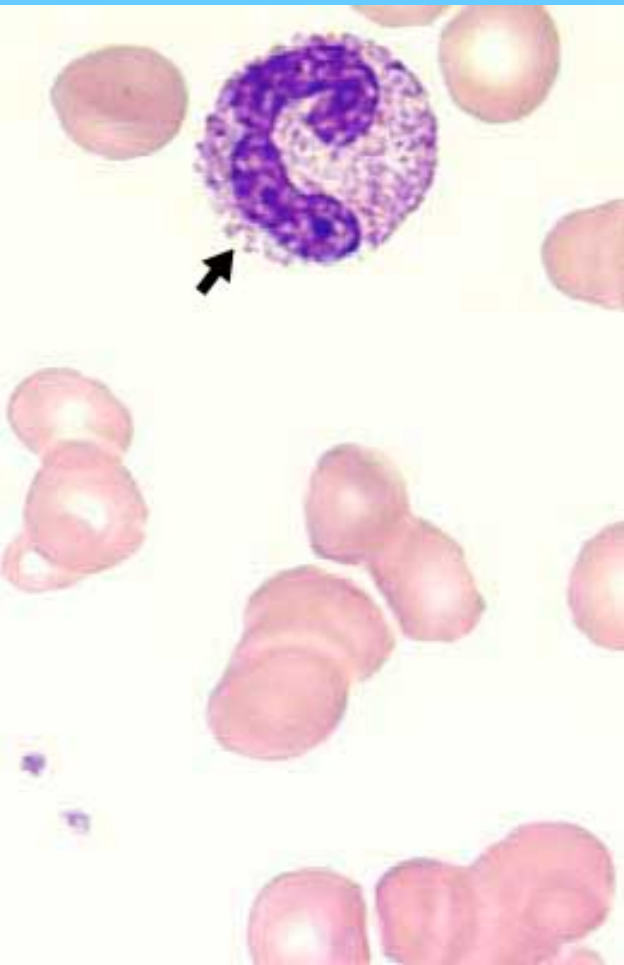

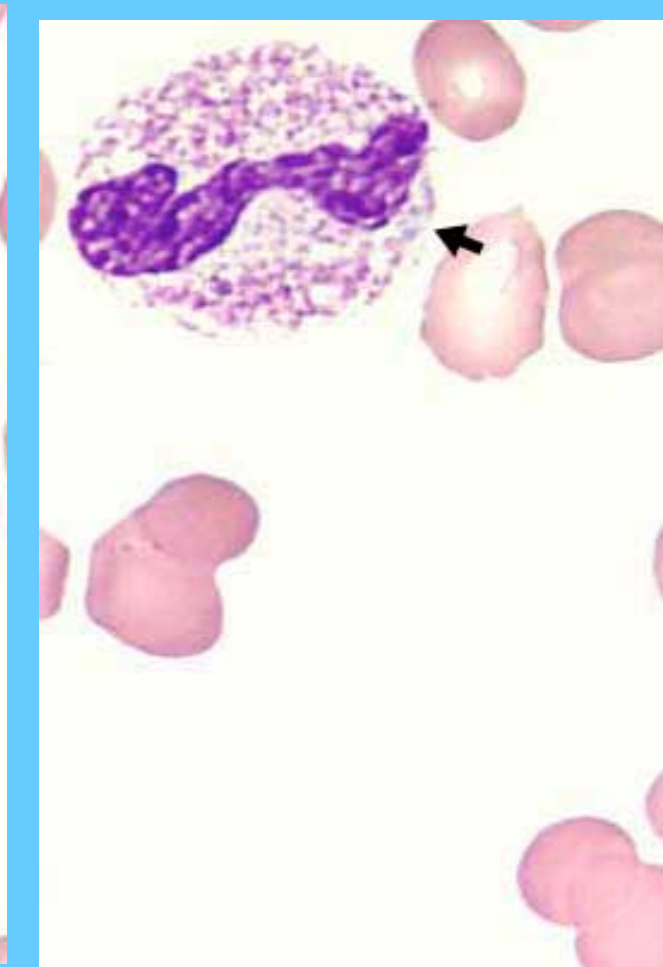
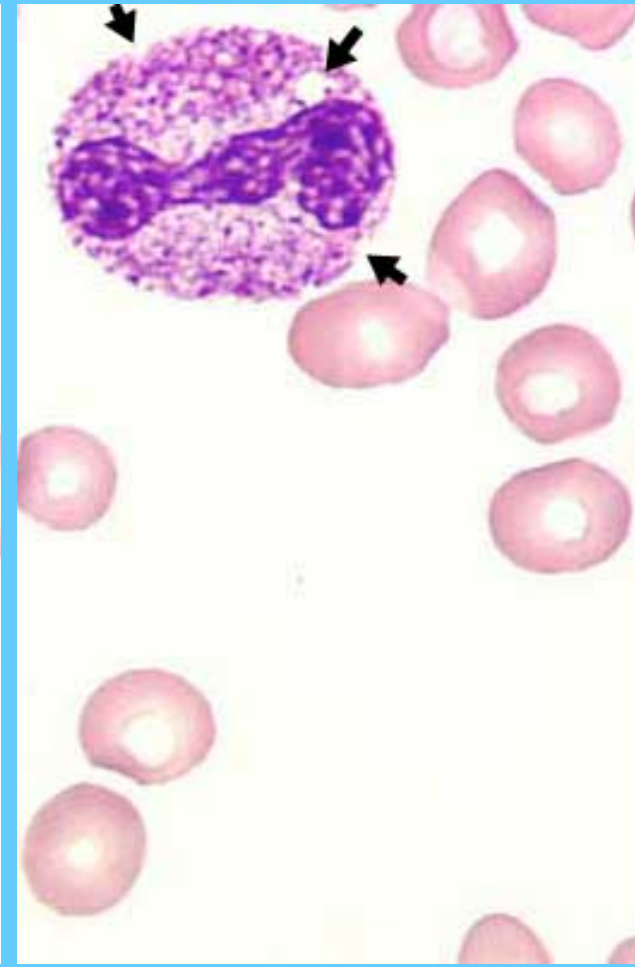
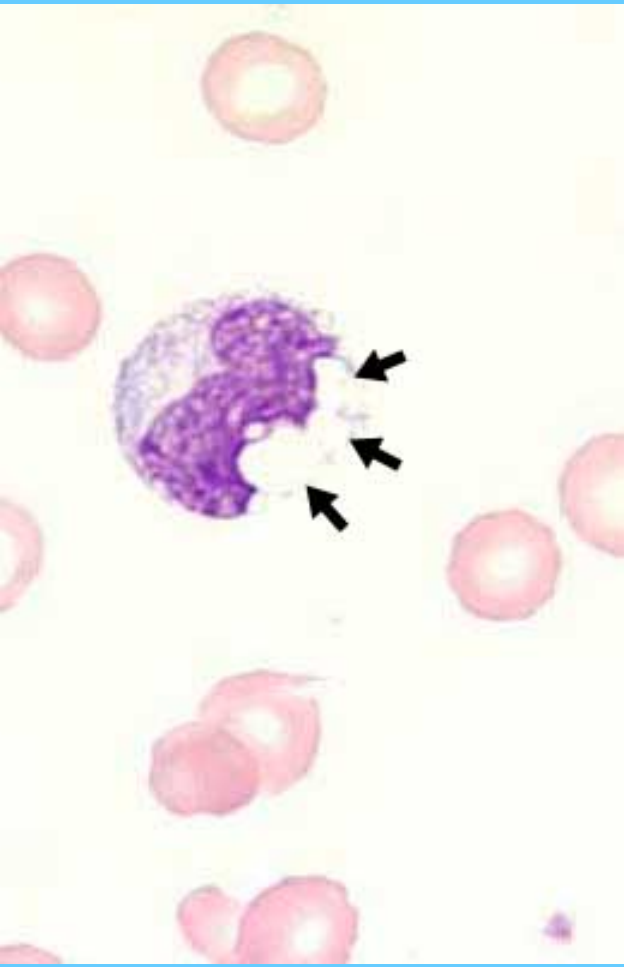
Remanente nuclear de un megacariocito

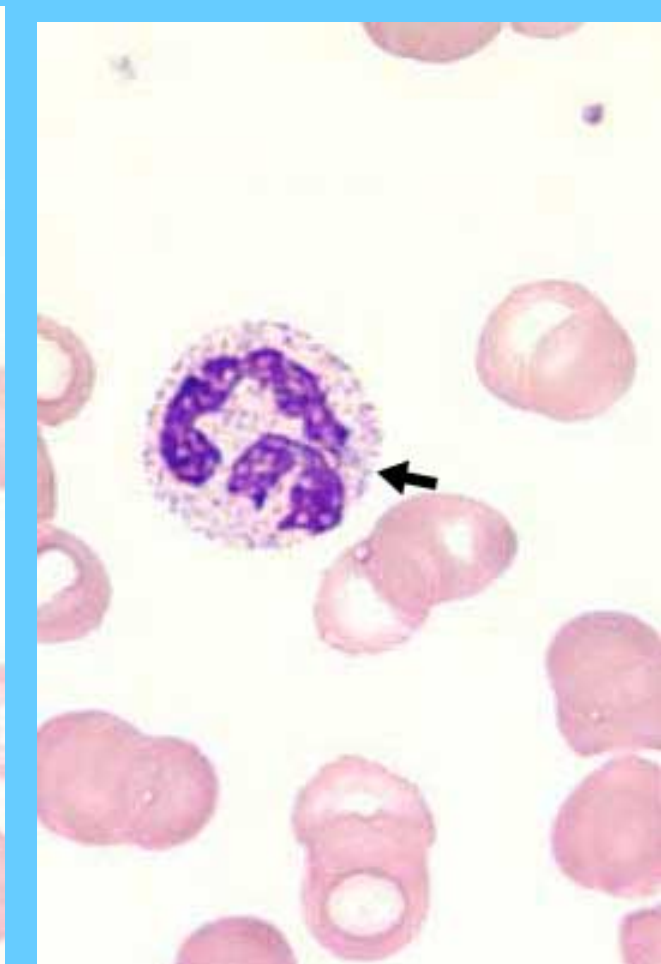
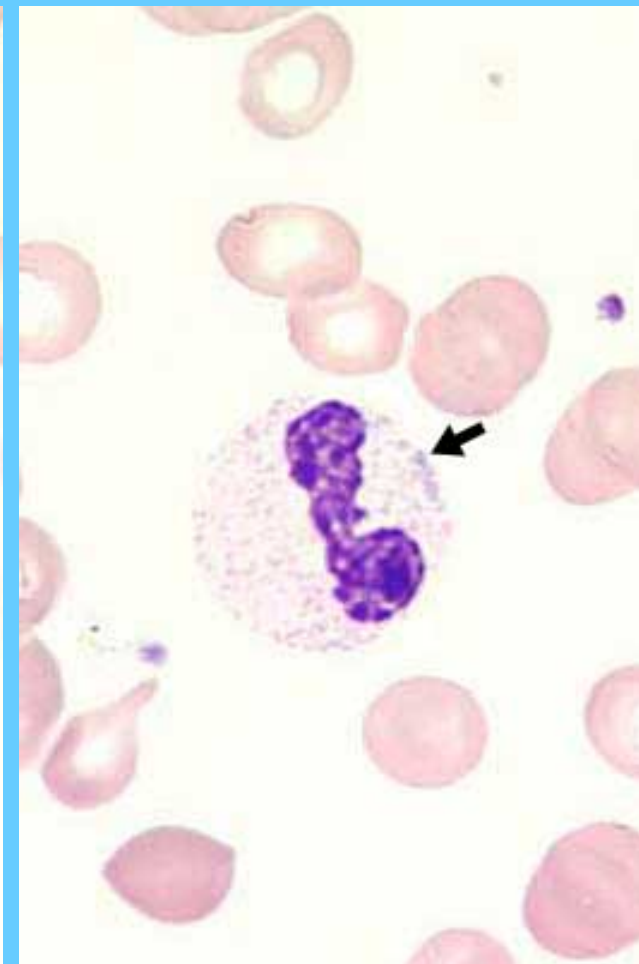
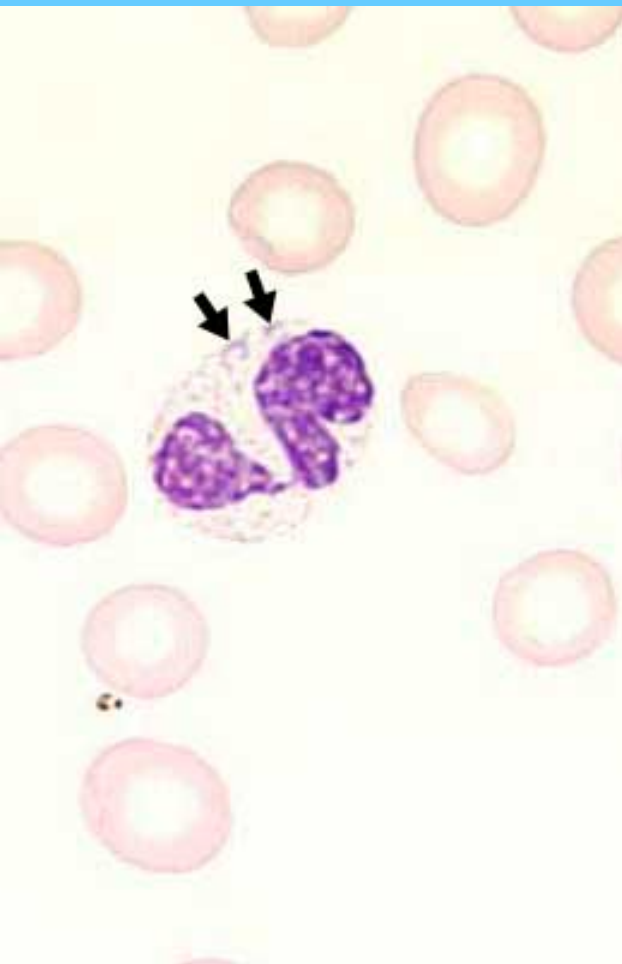

NEUTRÓFILO SEGMENTADO QUE PRESENTA GRANULACIÓN TÓXICA, VACUOLAS Y CUERPOS DE DOHLE

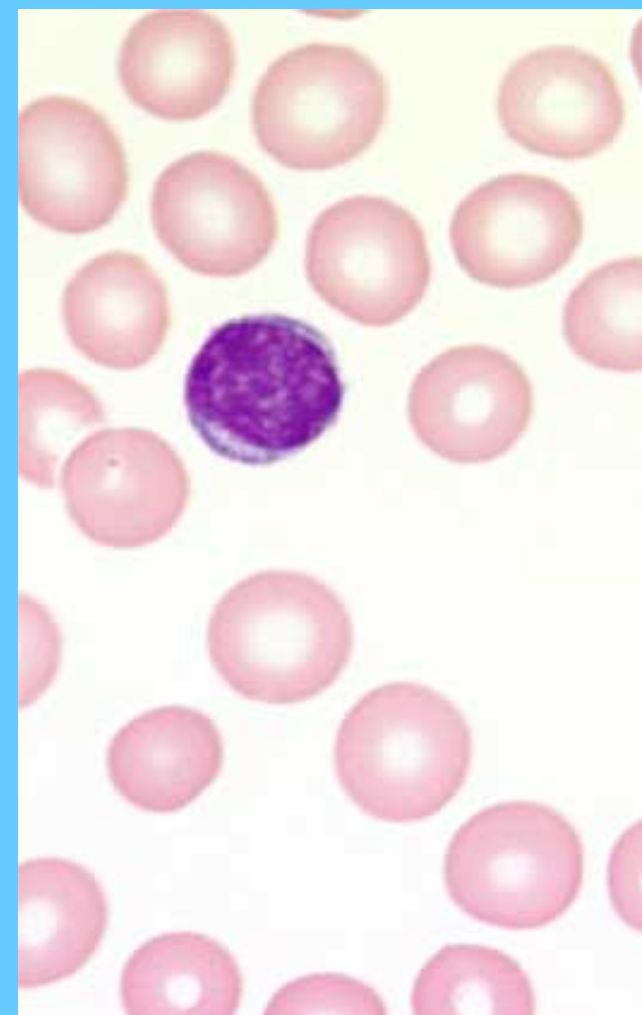
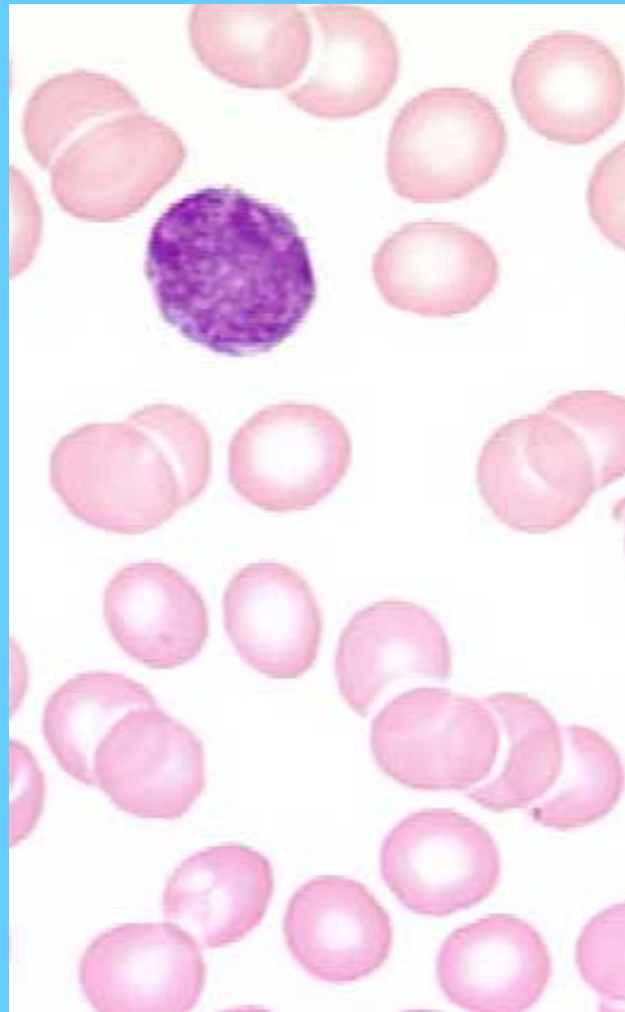
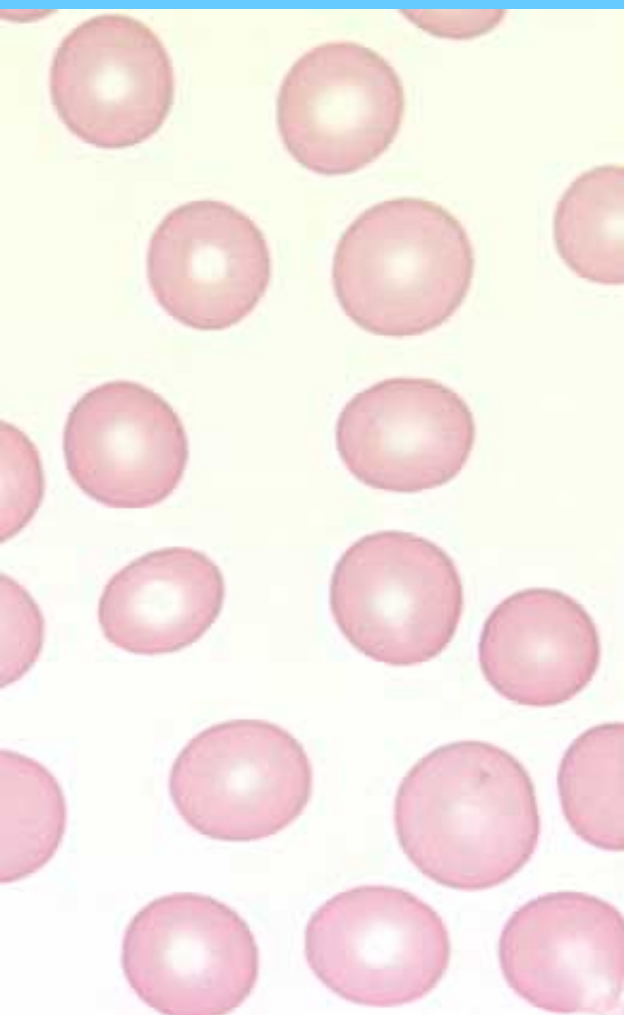




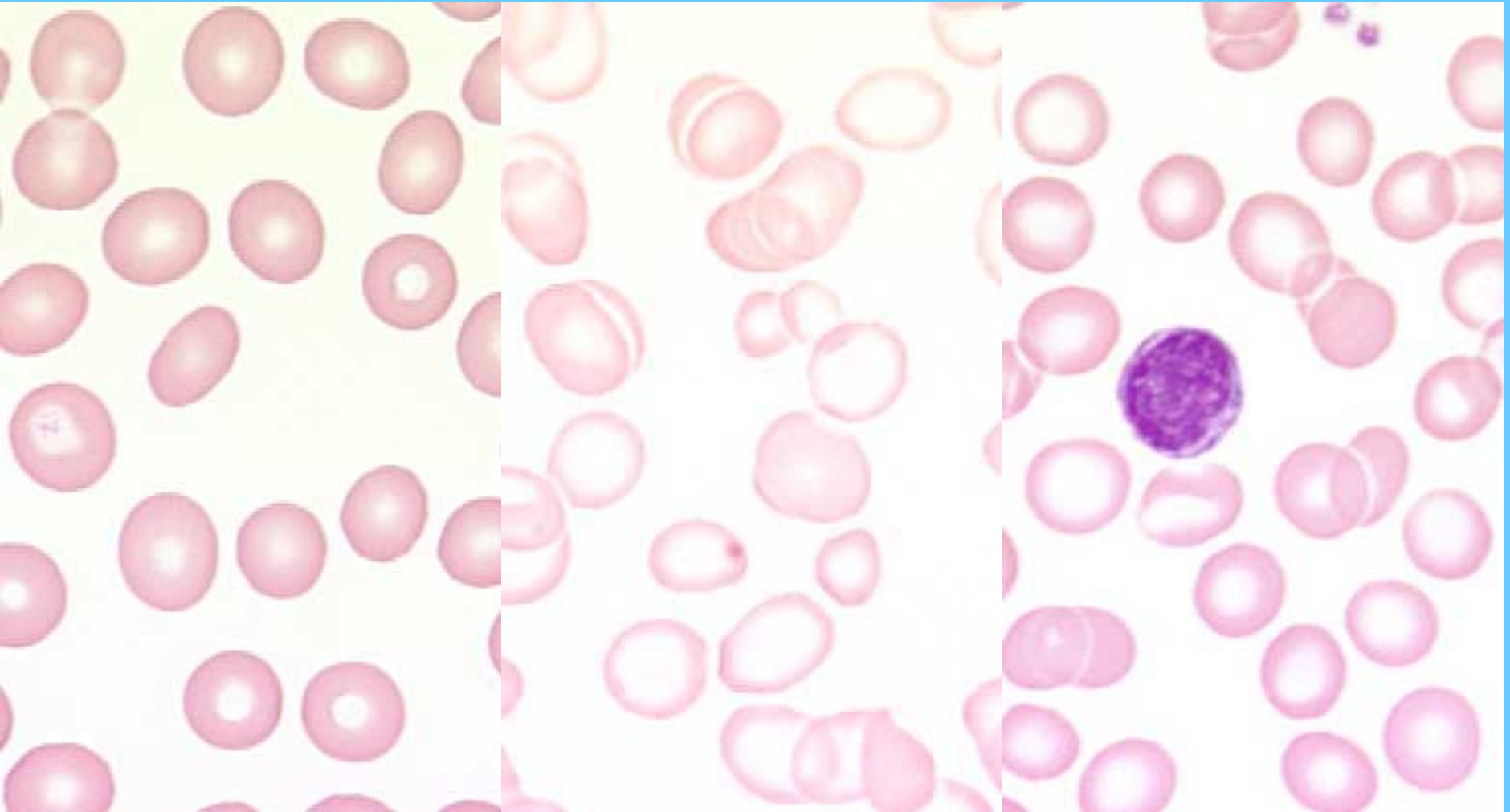




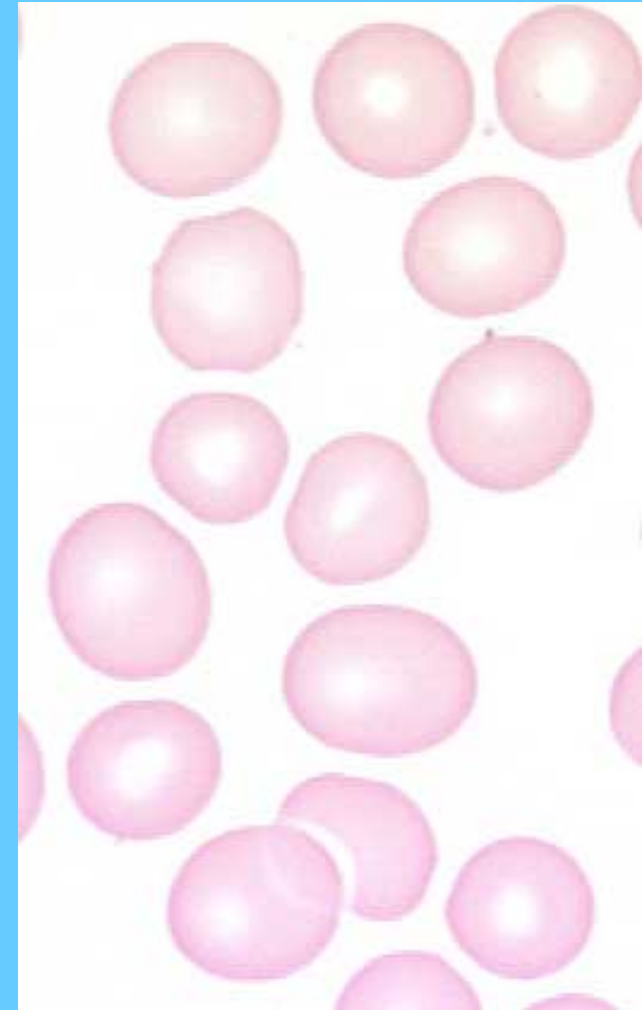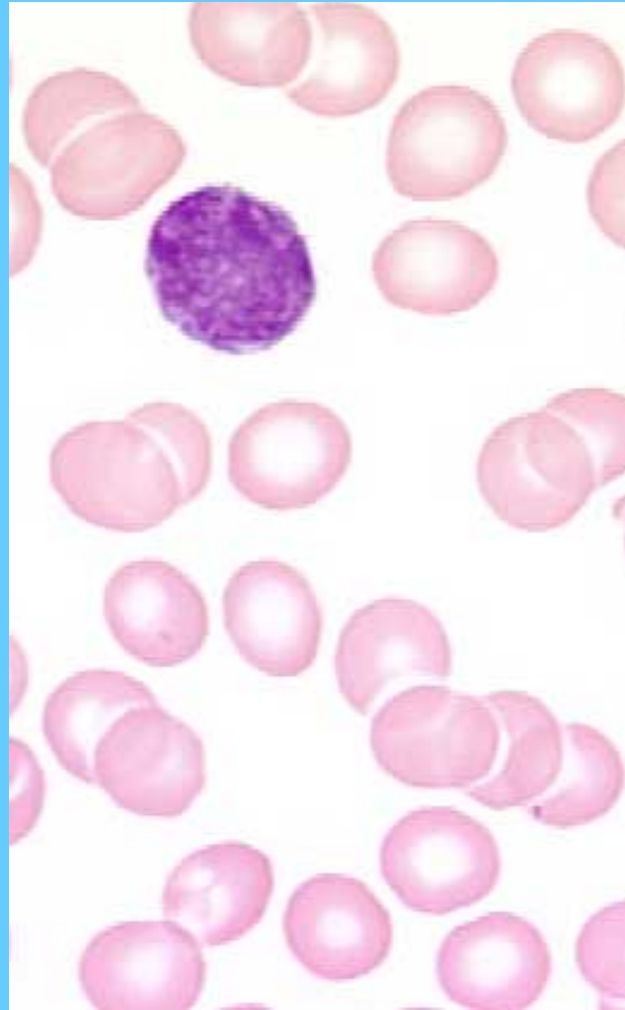
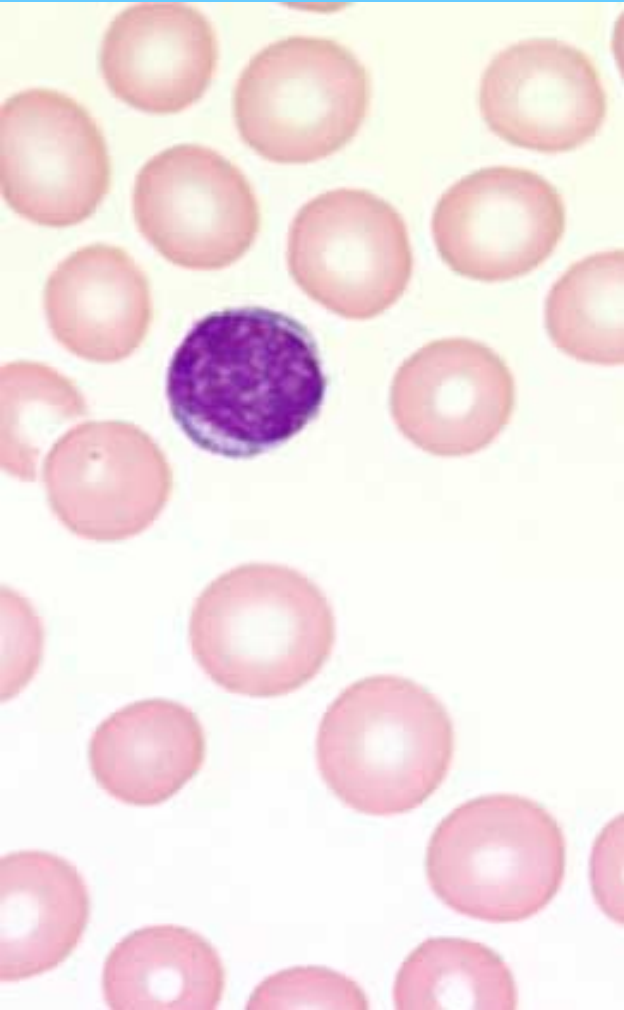Microcytosis centro



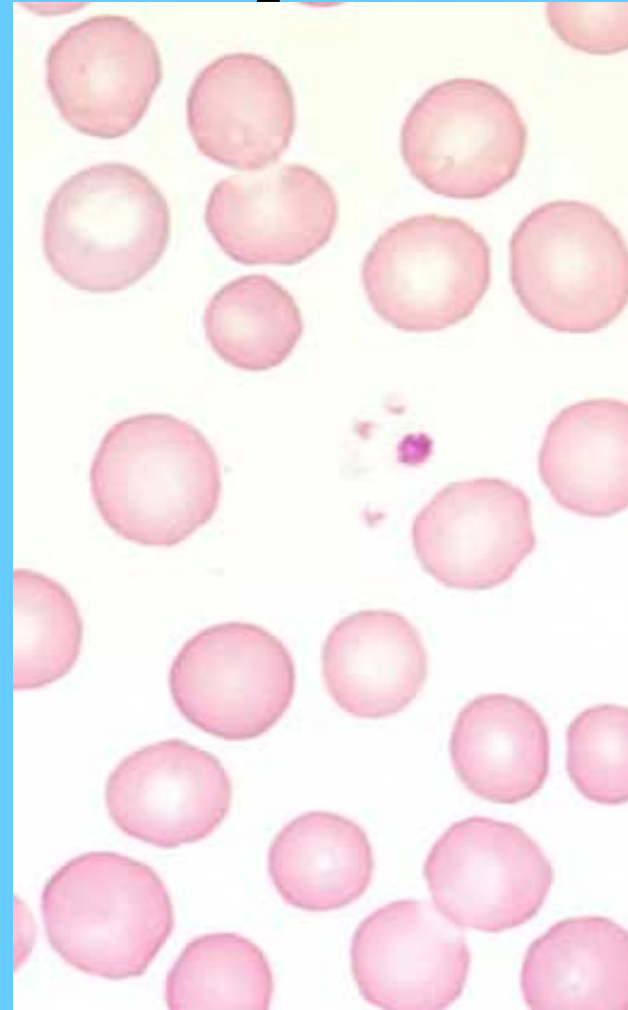
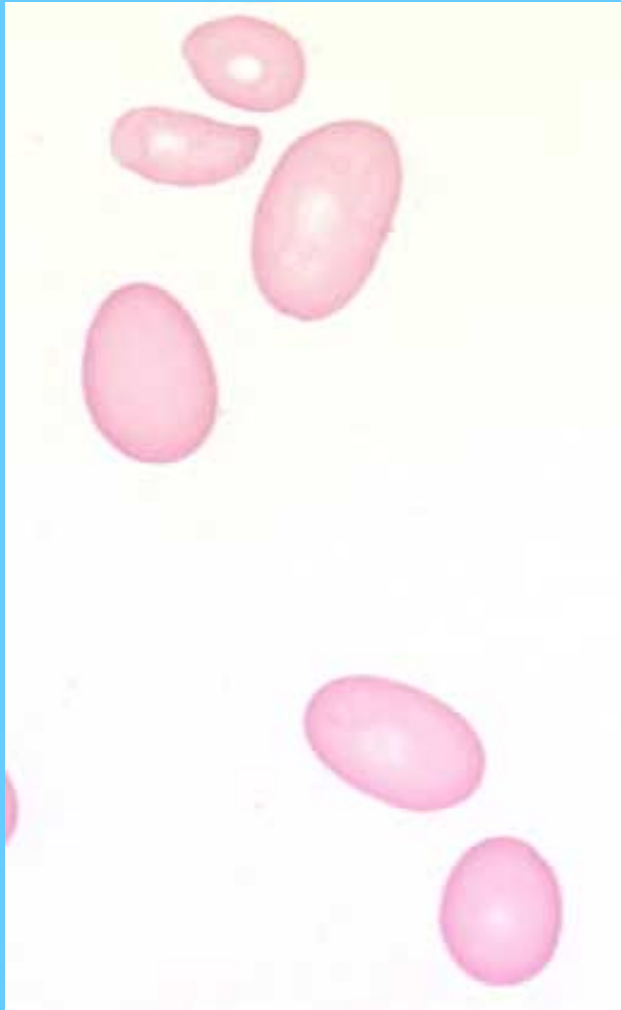Hipocromia centro y derecha



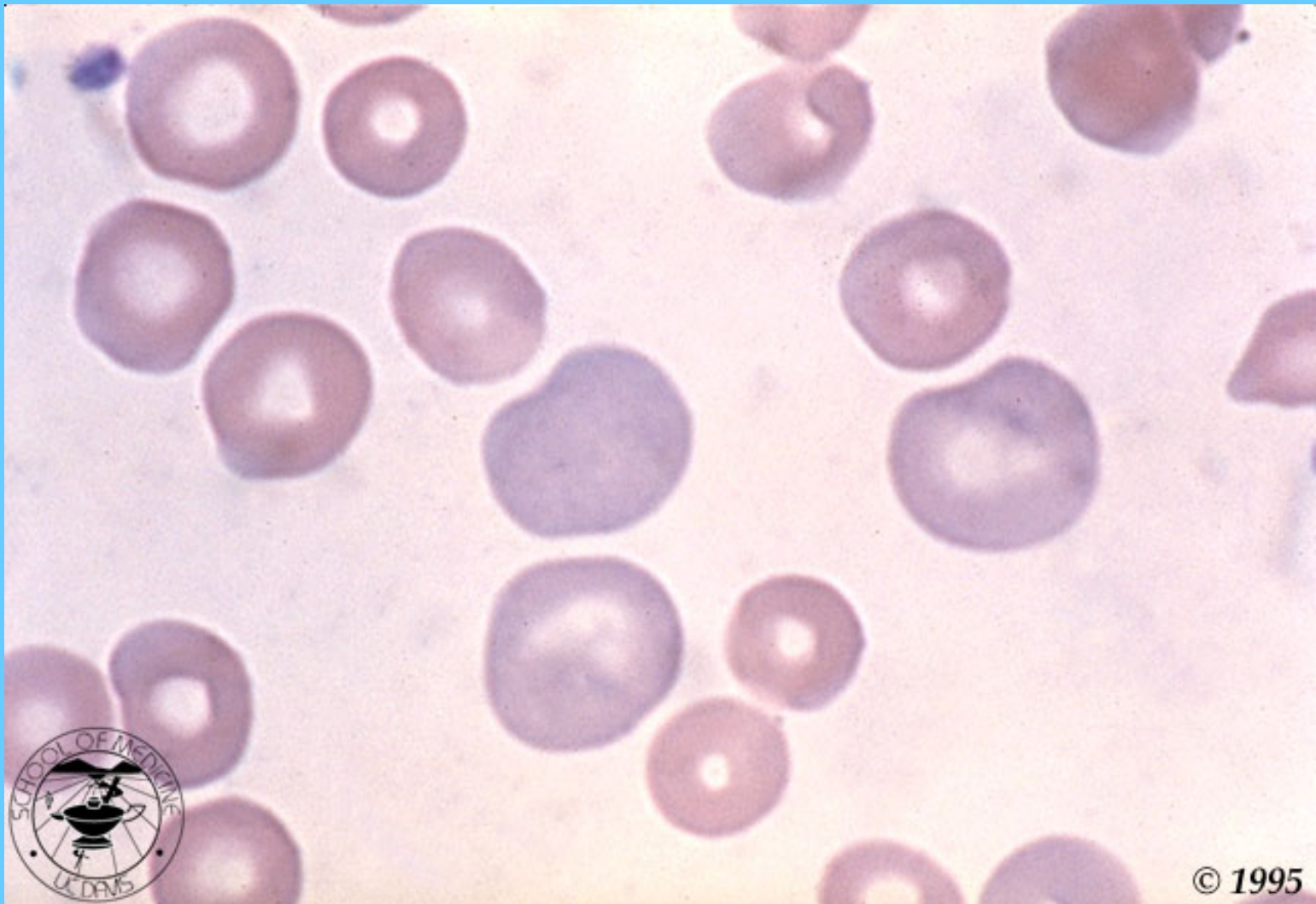
Microcitosis centro y macrocitosis derecha



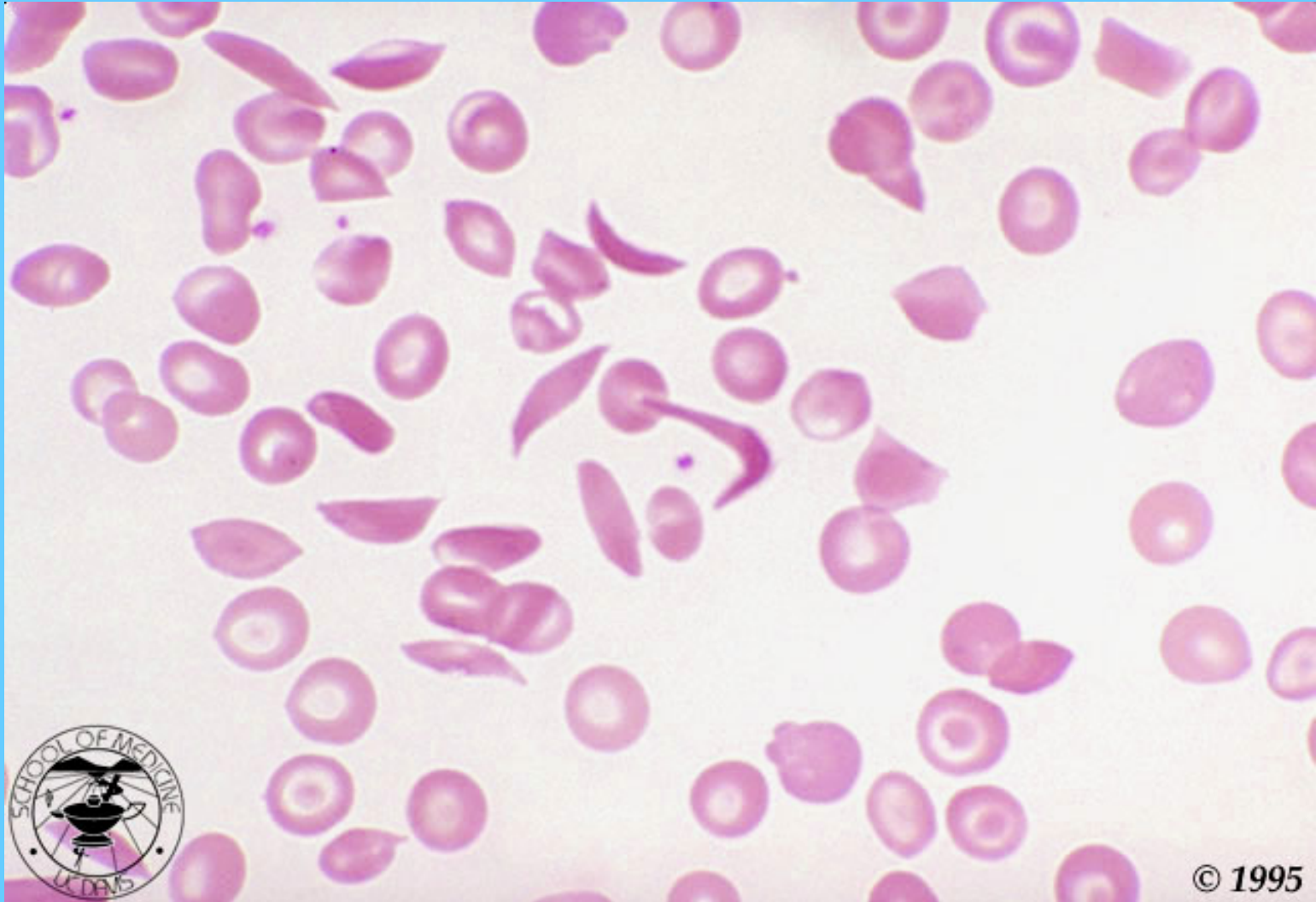
Macroovalocitos izquierda



POLICROMASIA

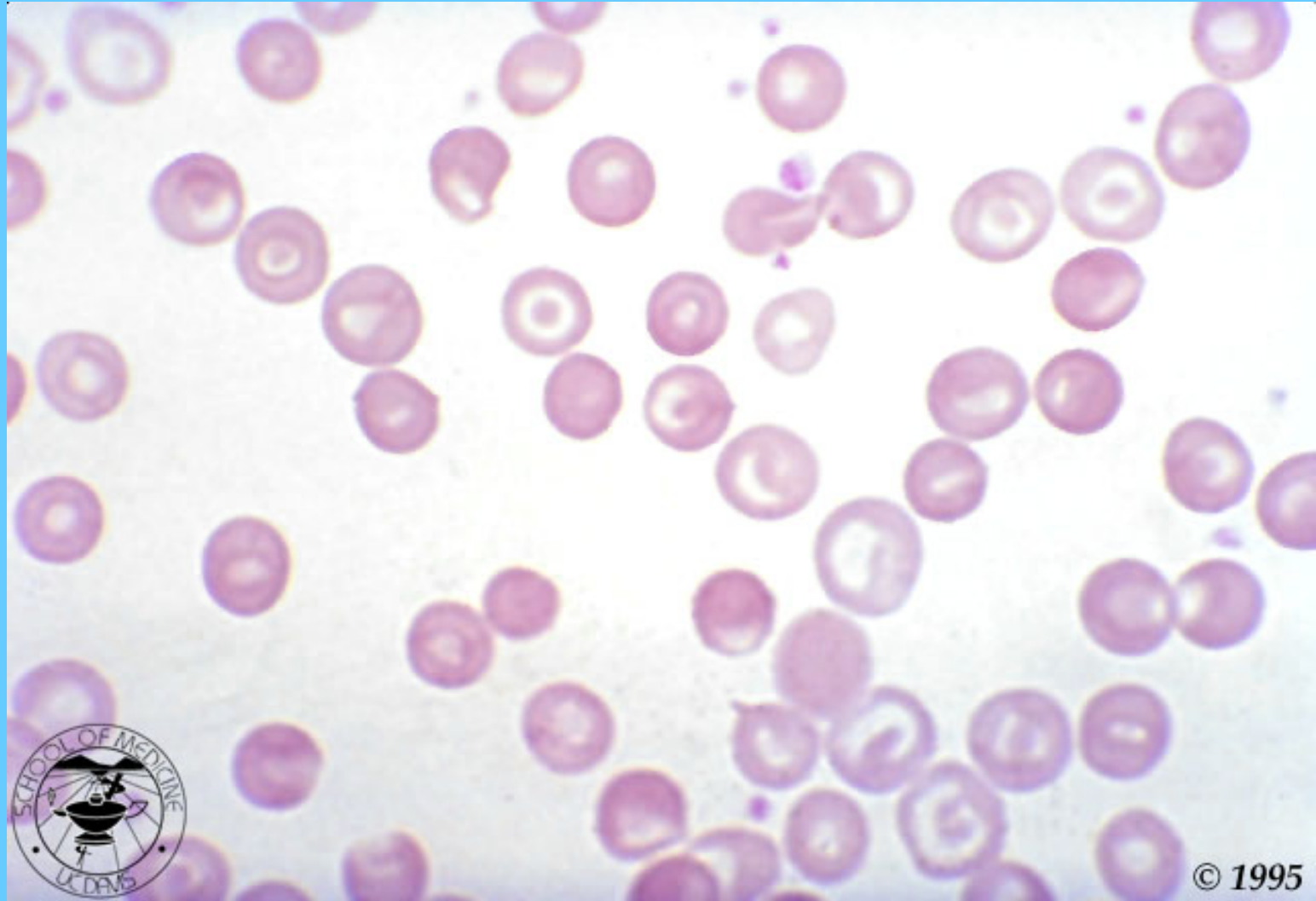


CÉLULAS FALCIFORMES



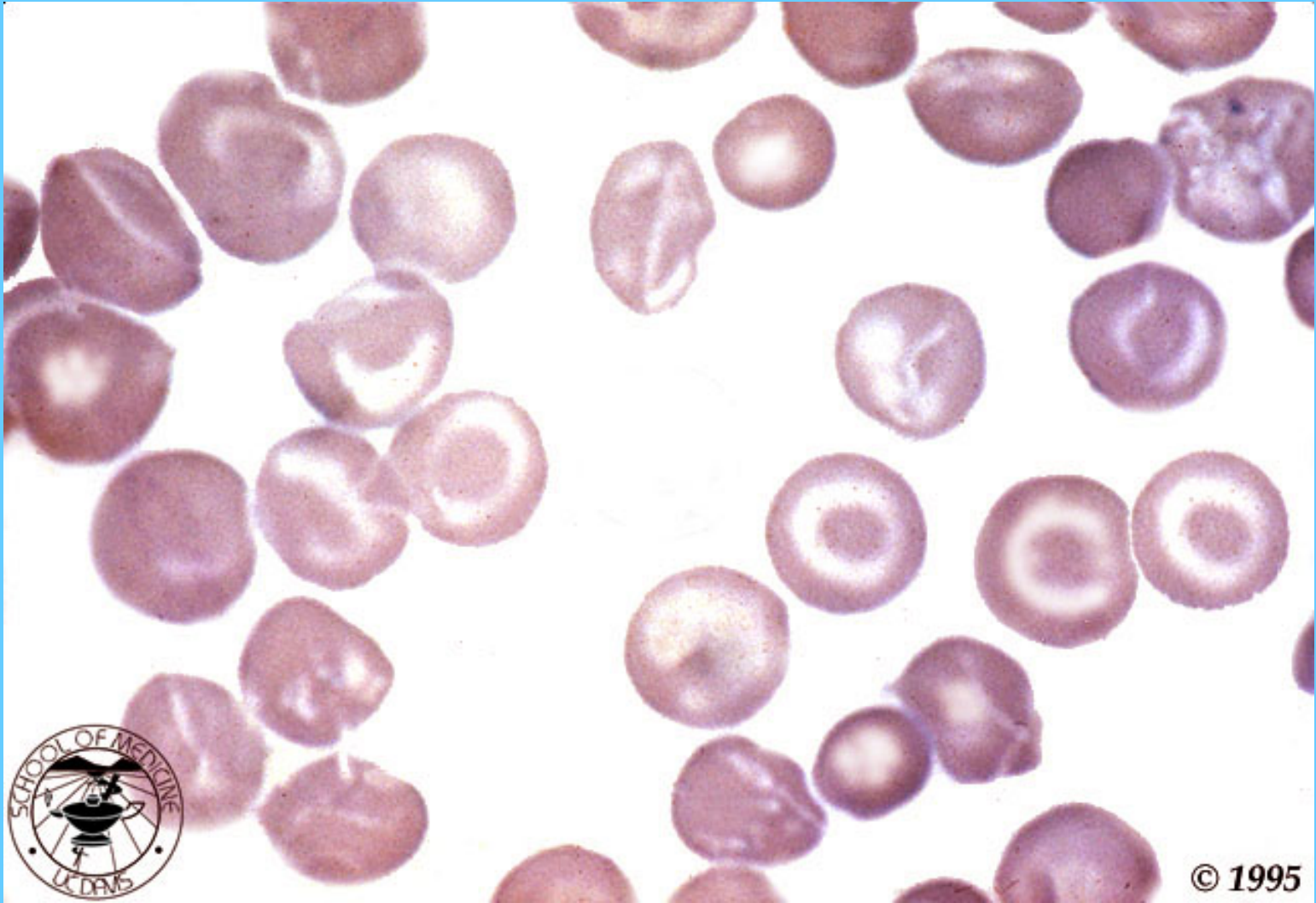
© 1995

HEMOGLOBINOPATIA CODOCITOS

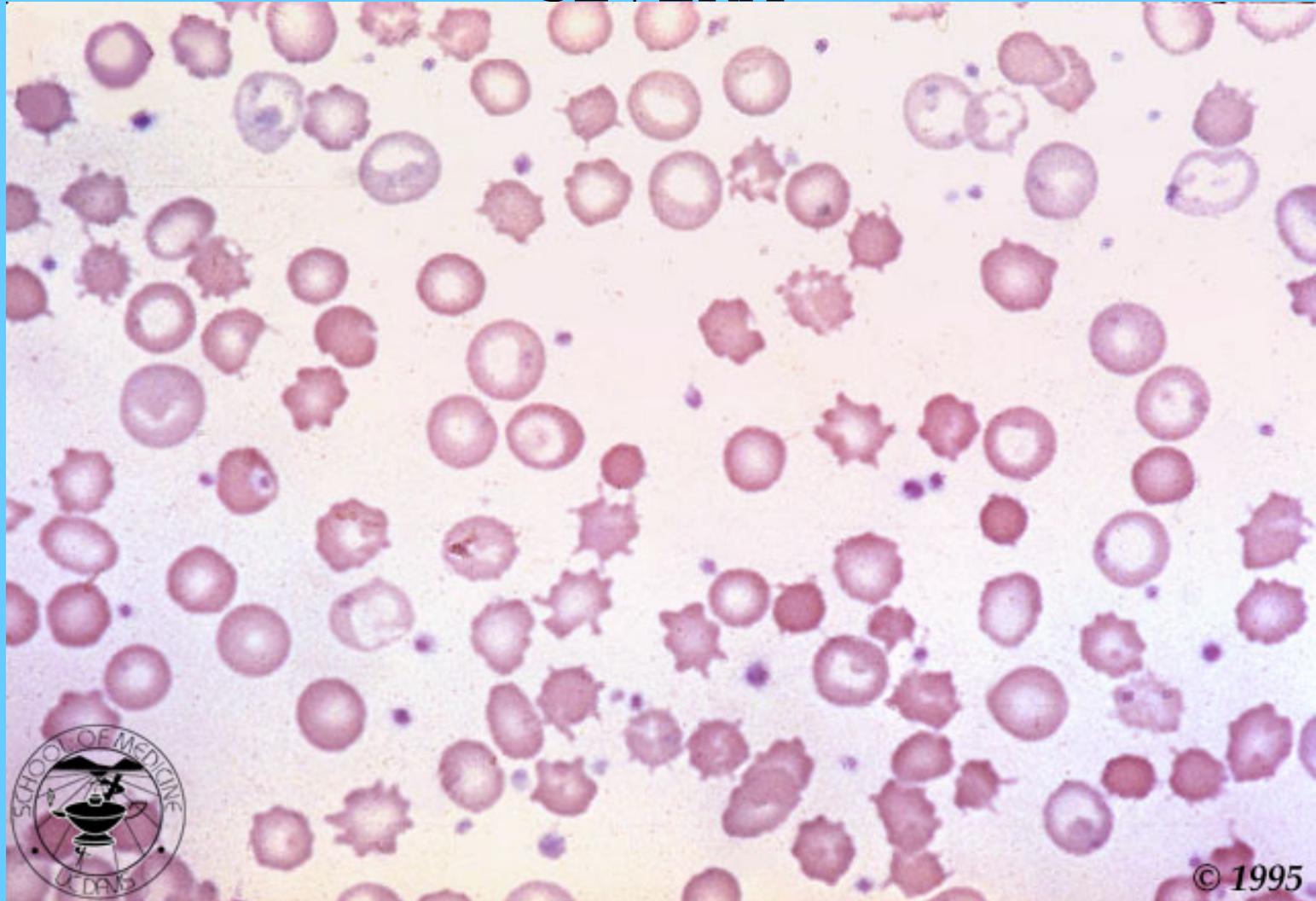


© 1995

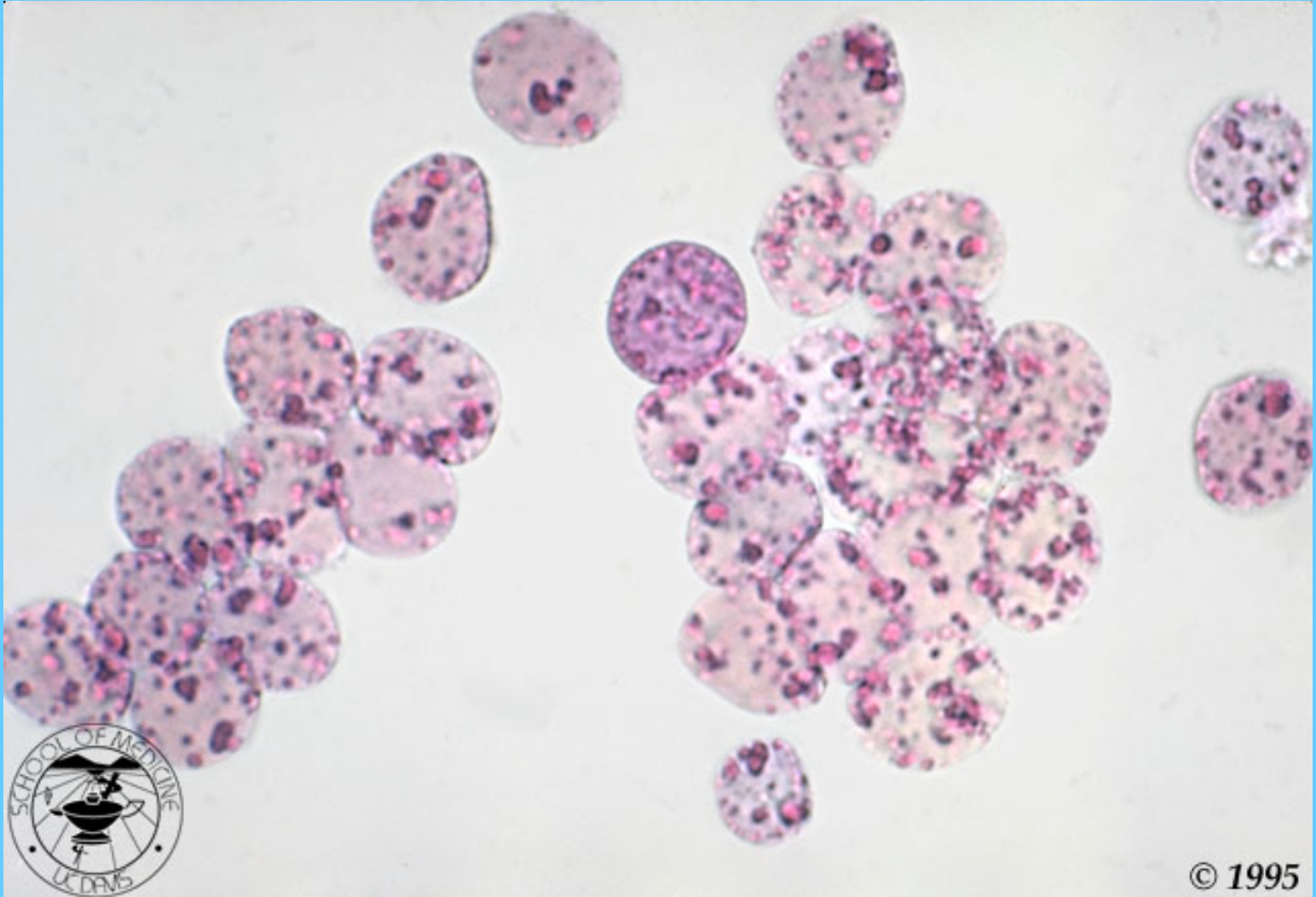
CODOCITOS EN ENFERMEDAD HEPÁTICA



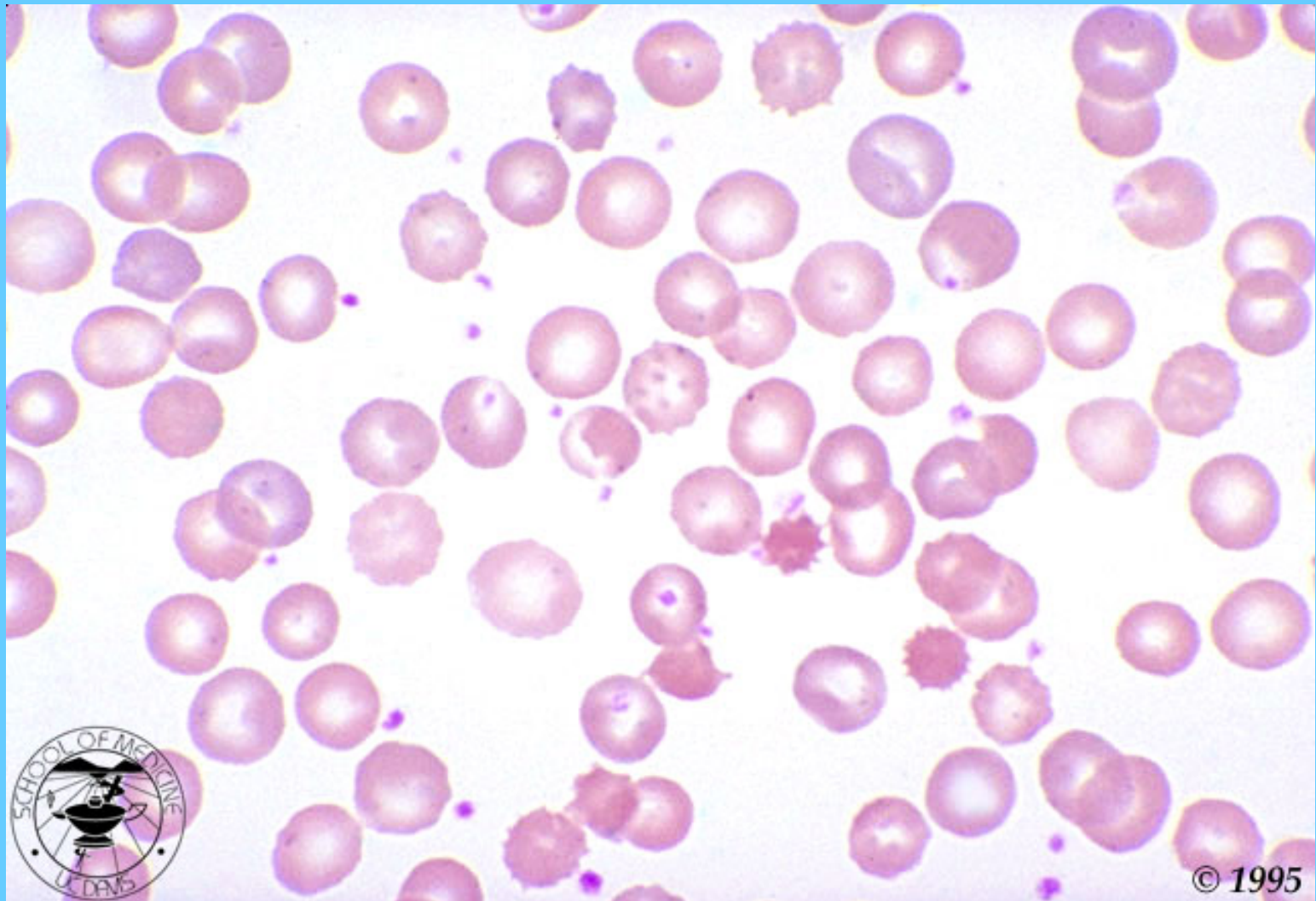
EQUINOCITOS Y ESFEROCITOS EN UN PACIENTE CON ENFERMEDAD HEPÁTICA SEVERA



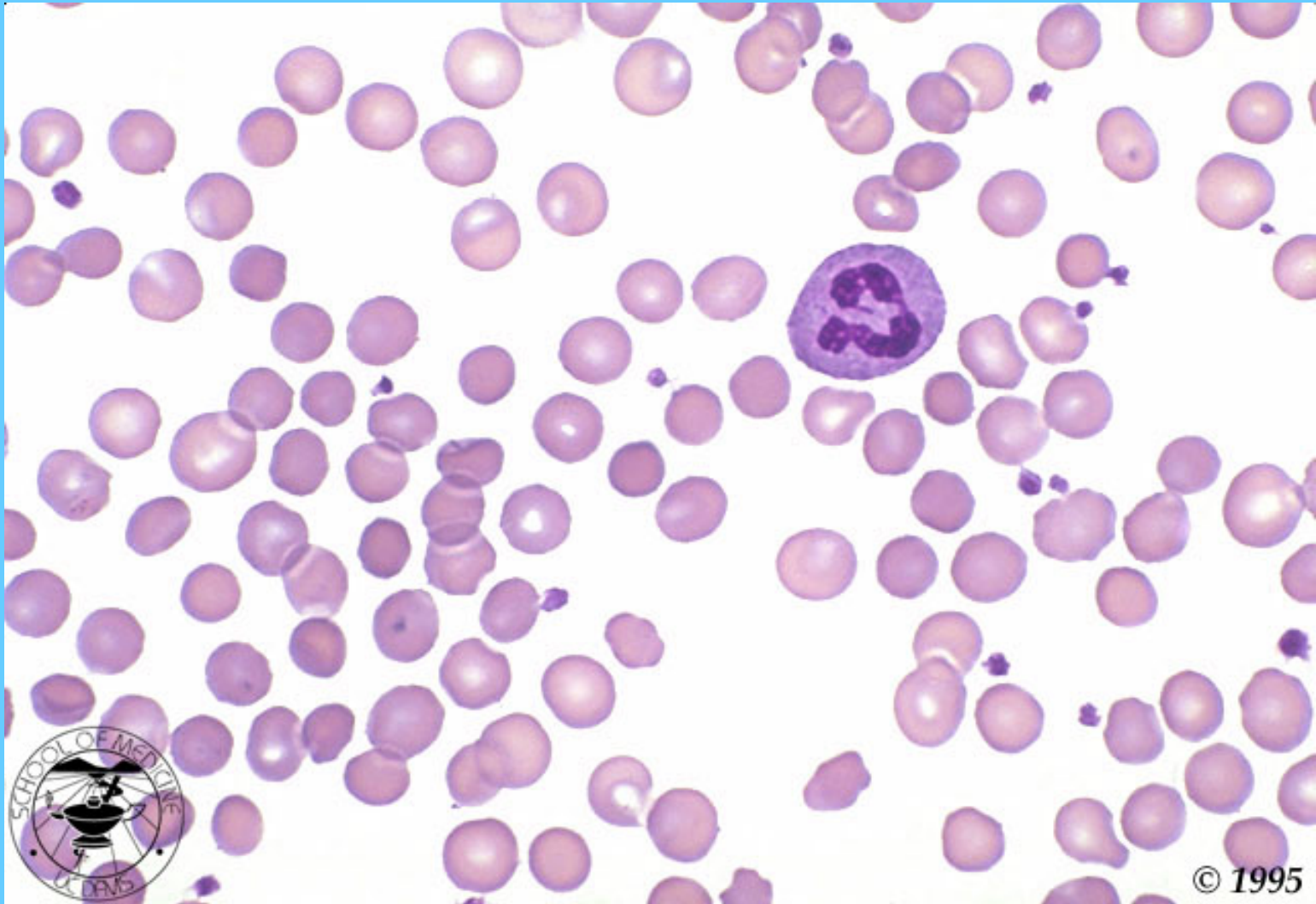
CUERPOS DE HEINZ TINCIÓN SUPRAVITAL



ANEMIA HEMOLITICA POR DEFICIENCIA DE PIRUVATO KINASA

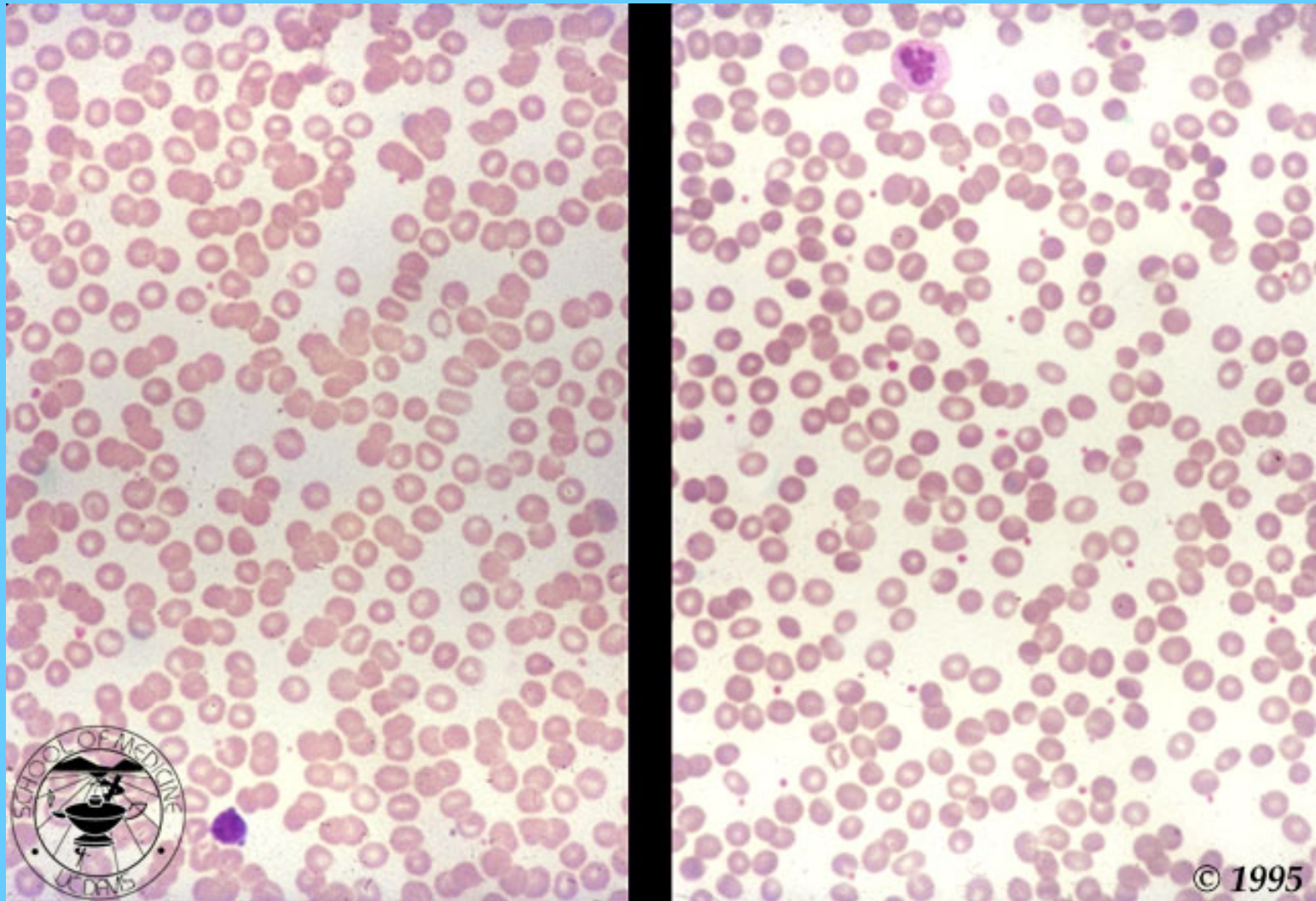


ESFEROCITOSIS



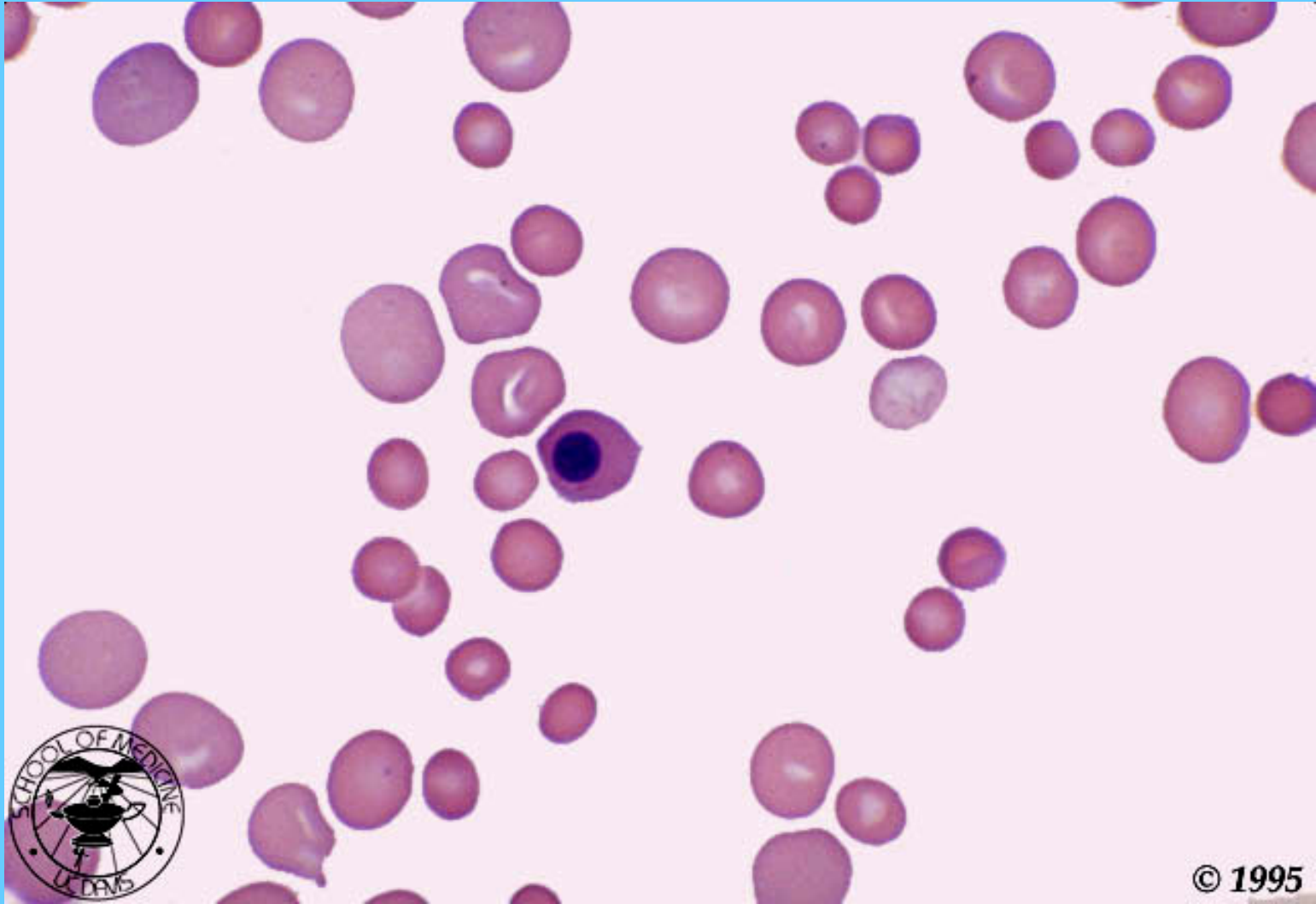
© 1995

SANGRE NORMAL/ ESFEROCITOSIS HEREDITARIA

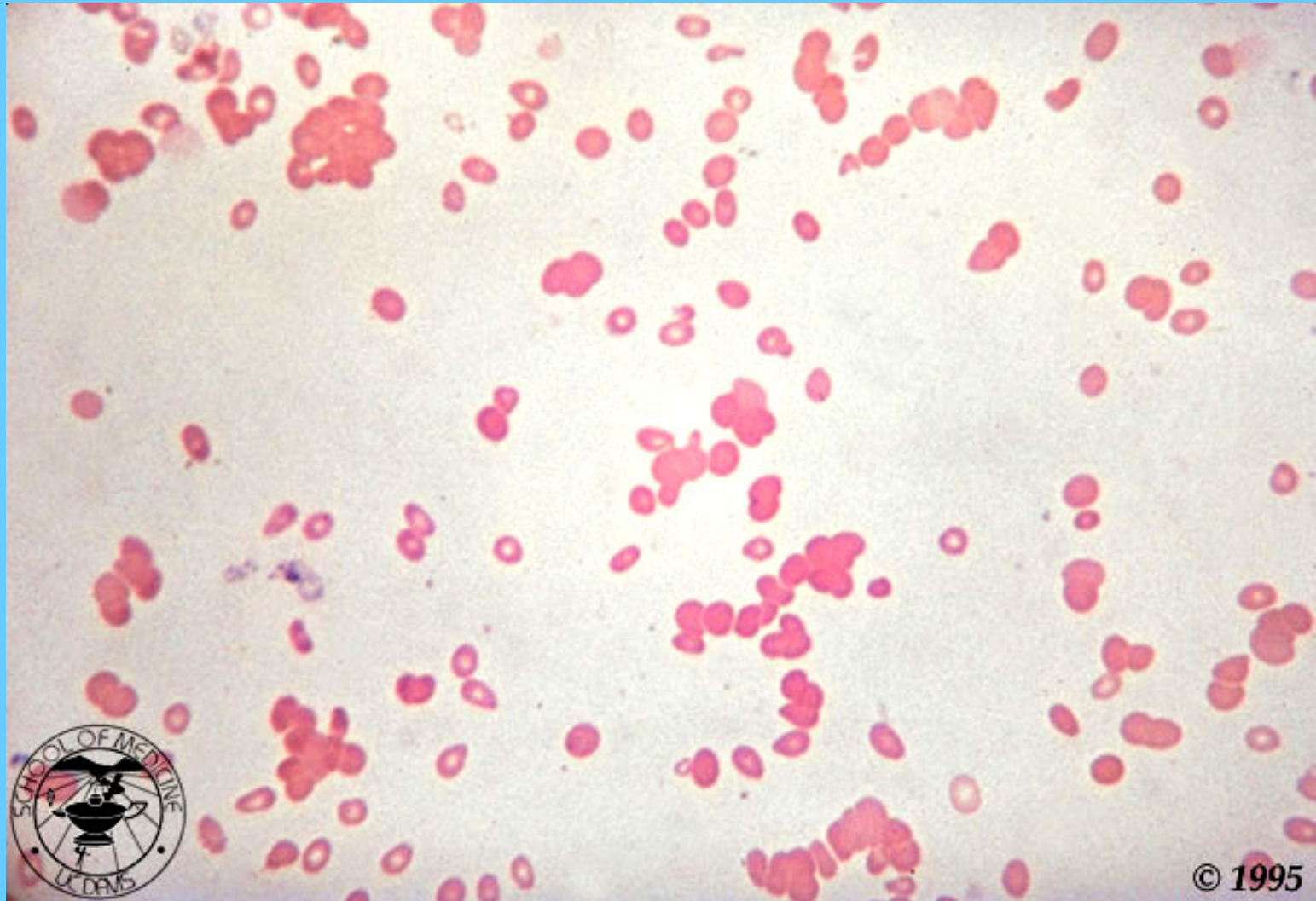


ANEMIA HEMOLITICA AUTOINMUNE

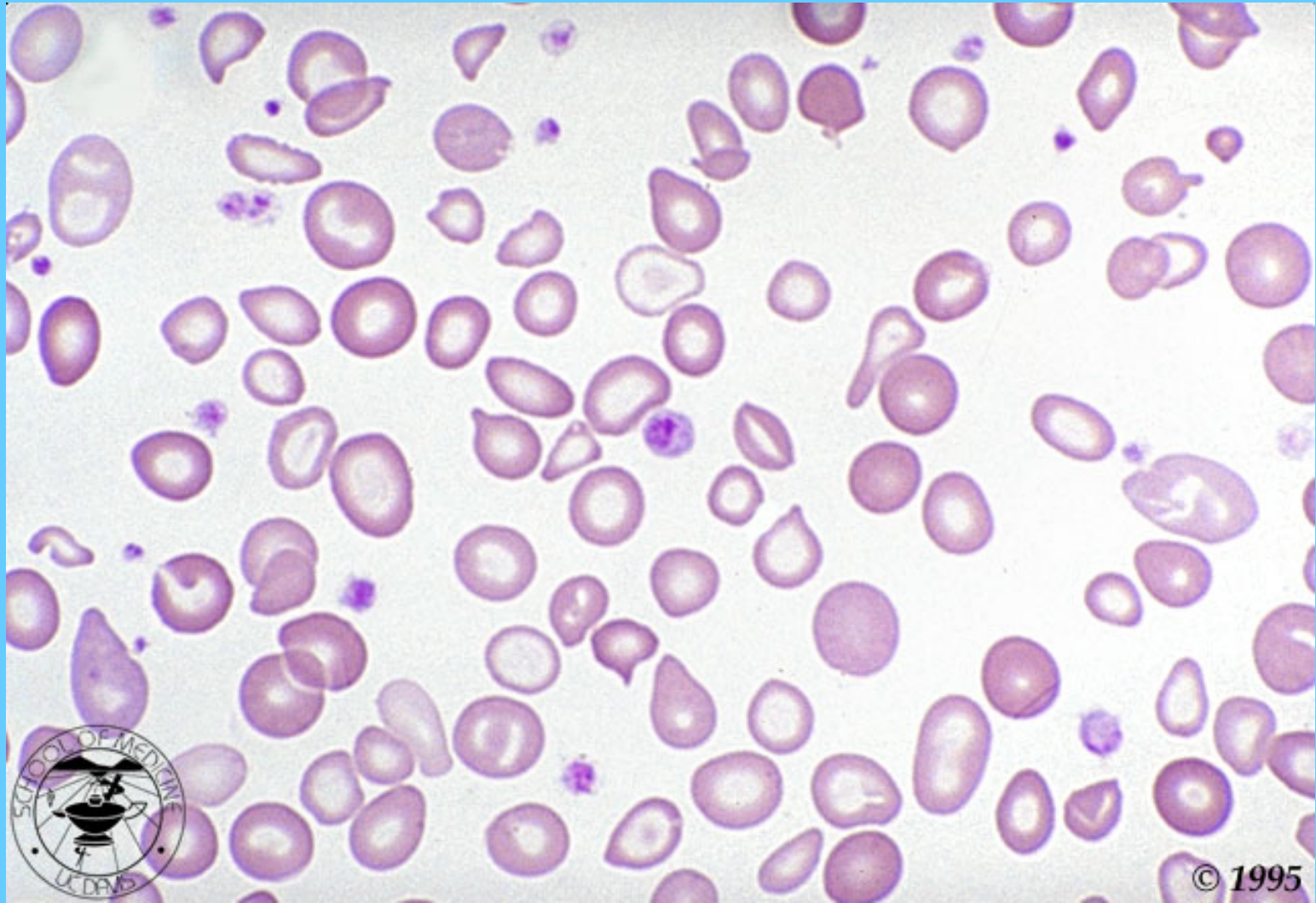
POLICROMASIA, ESFEROCITOSIS Y ERITOBLASTOS



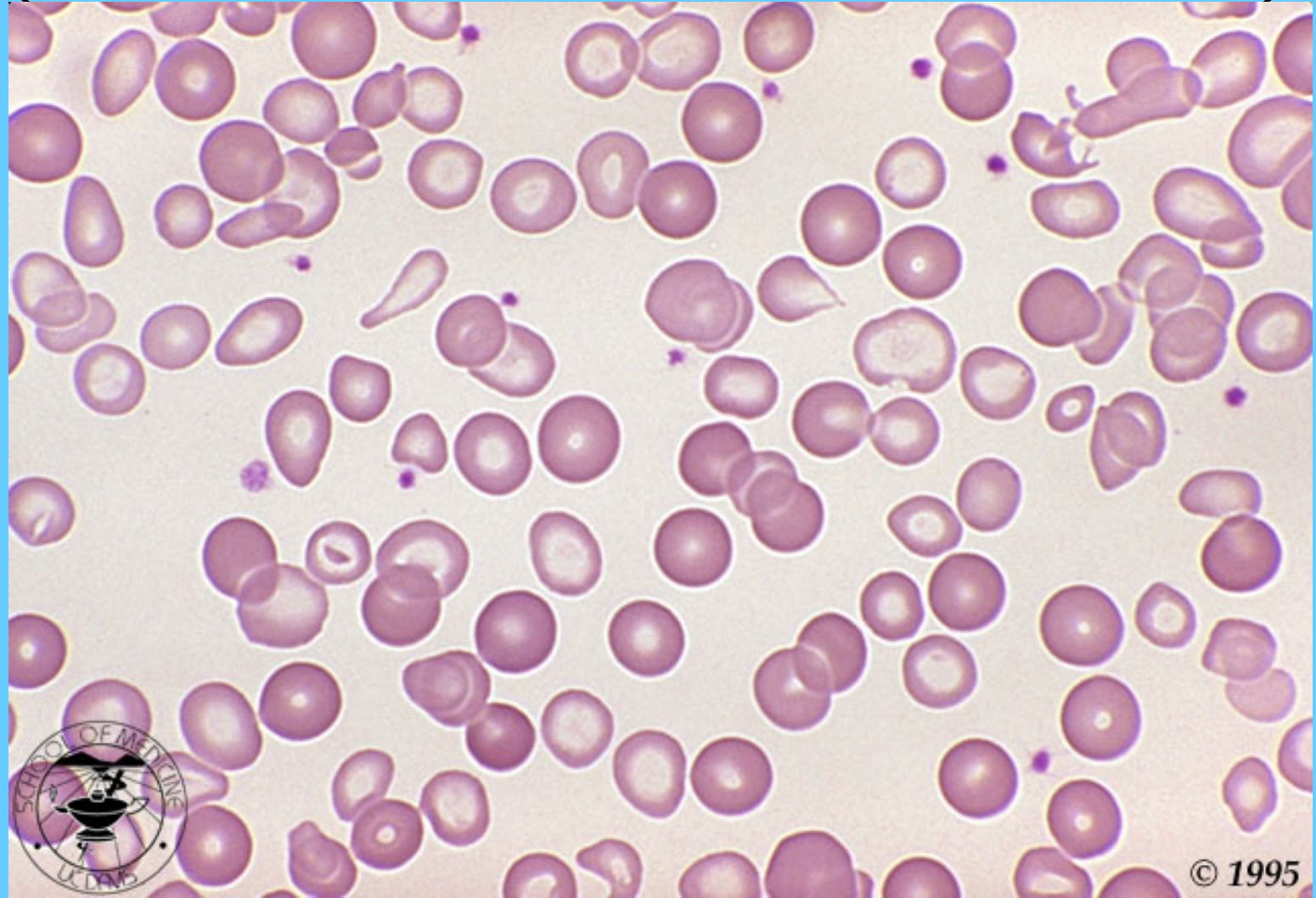AGLUTINACIÓN POR CRIOAGLUTININAS



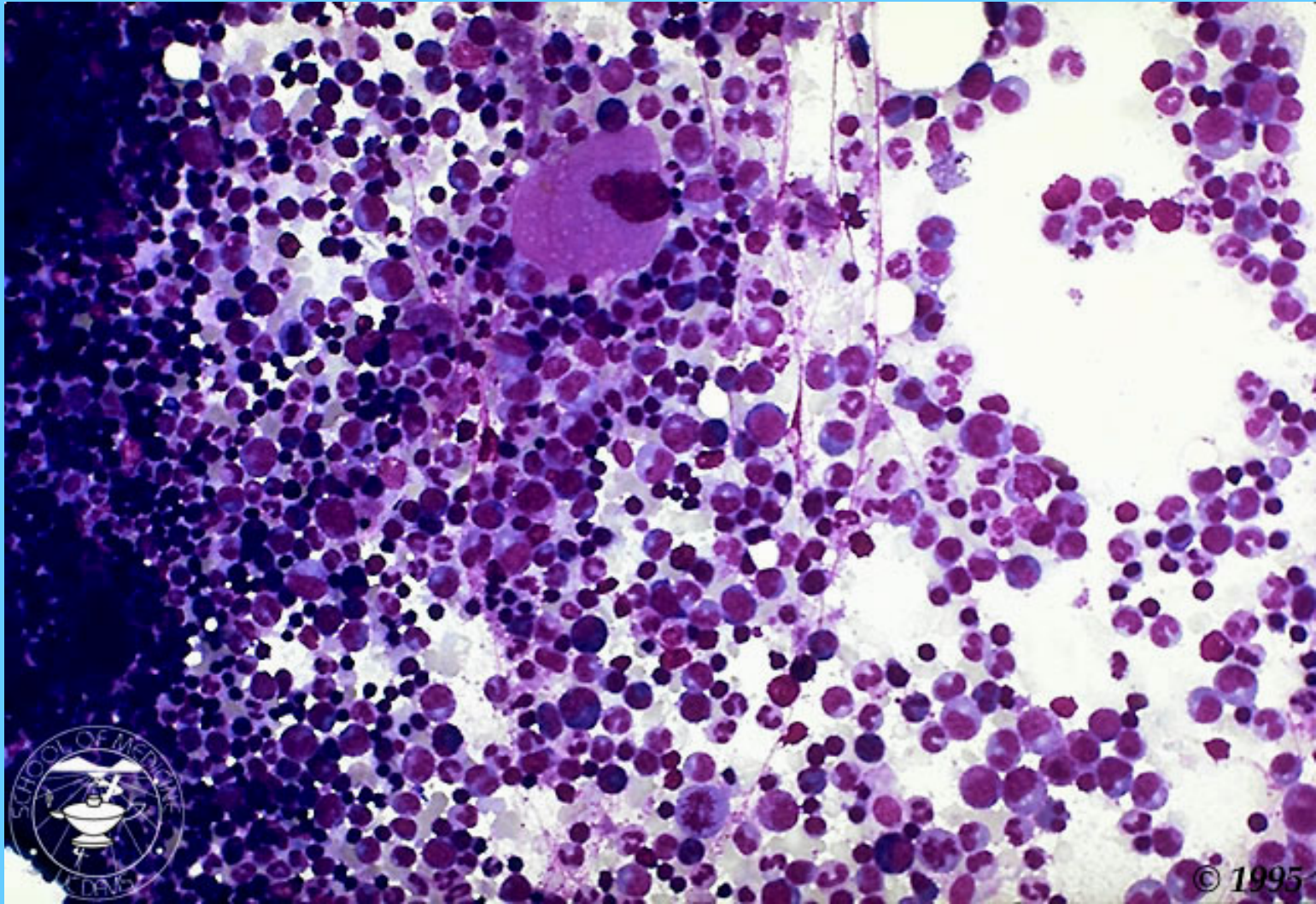
ANEMIA POR DEFICIENCIA DE HIERRO



DOS POBLACIONES (NORMAL Y FERROPENICA)

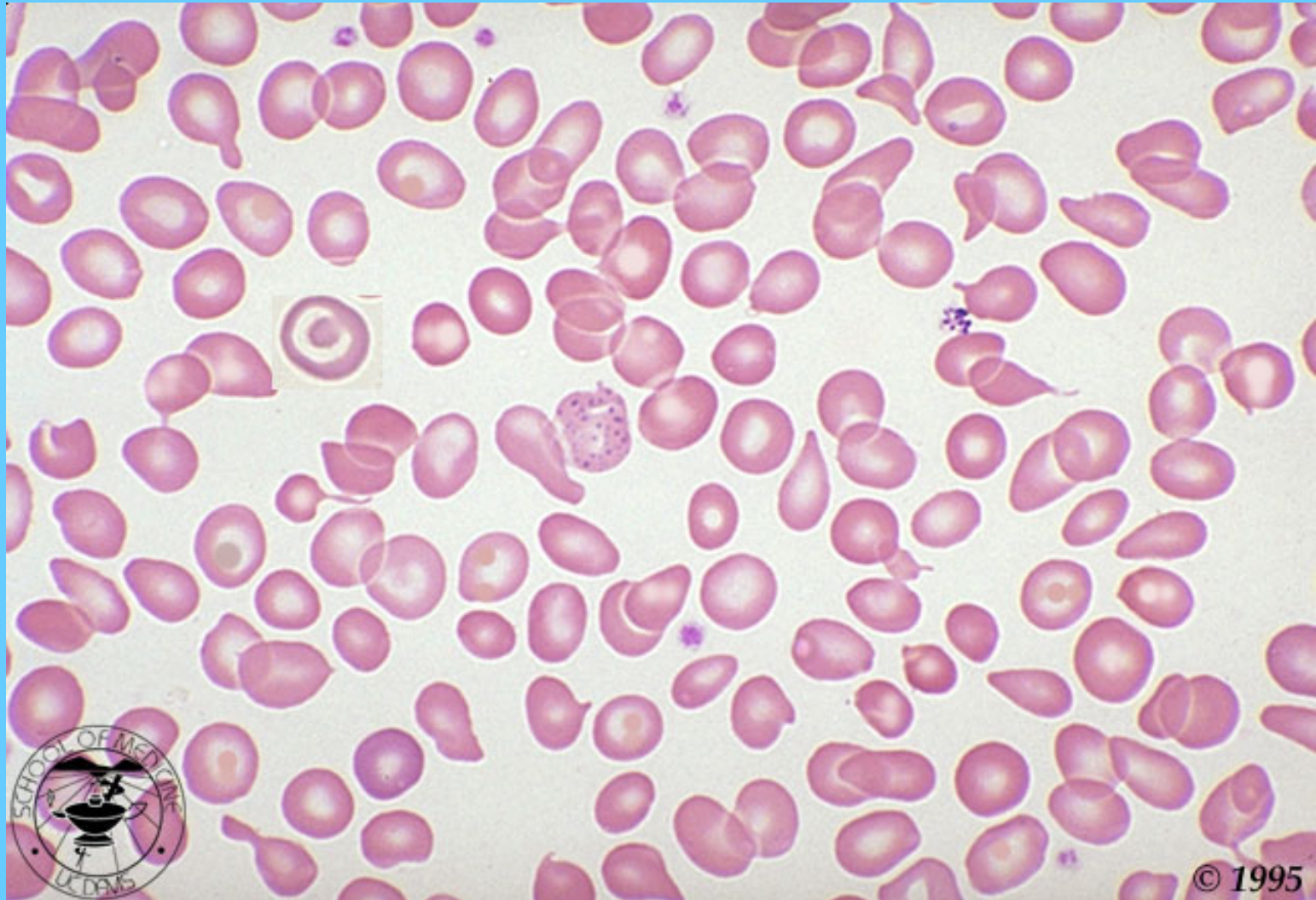


MÉDULA HIPERCELULARAR EN ANEMIA FERROPÉNICA

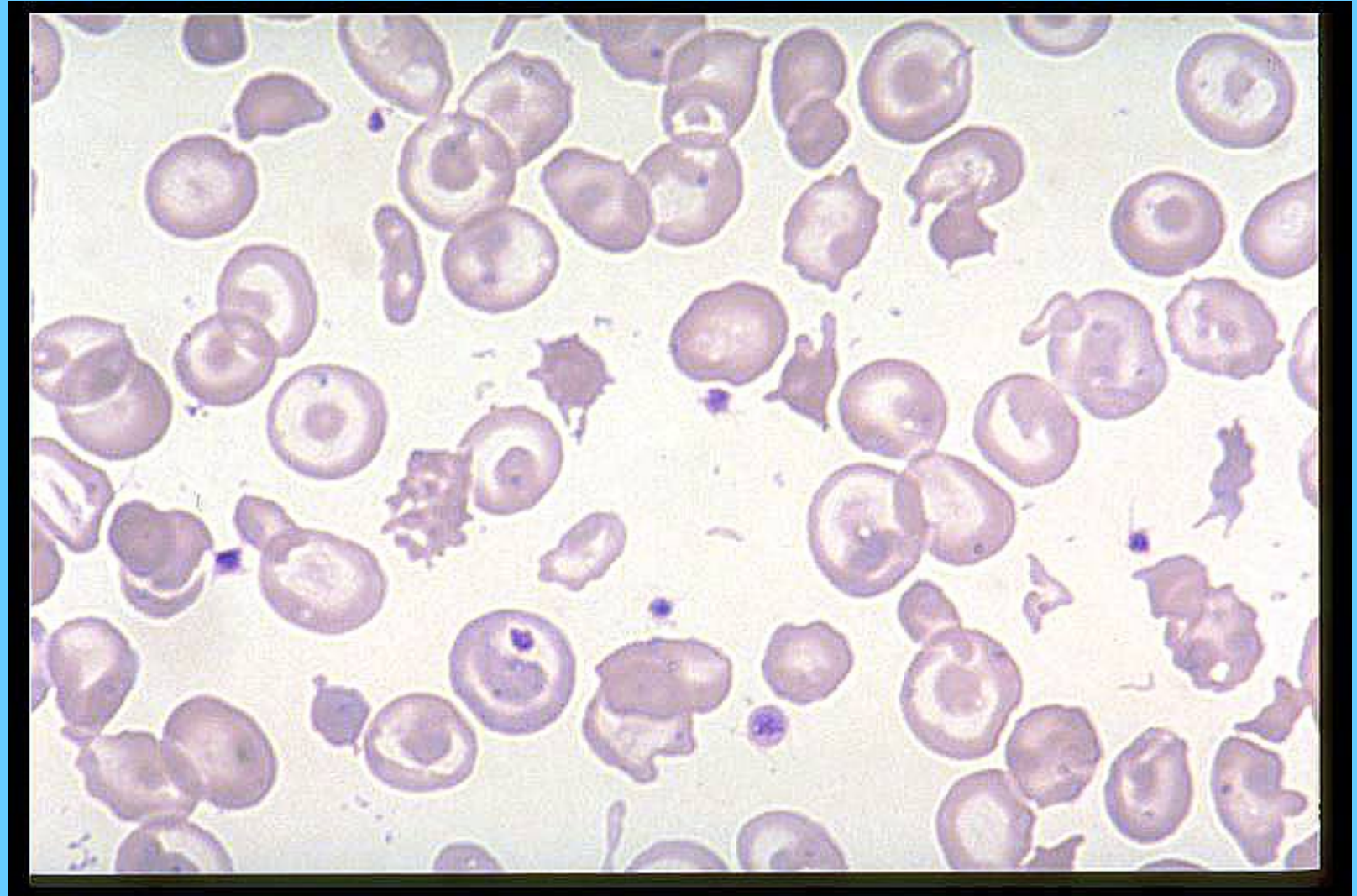


TALASEMIA MENOR

MICROCITOSIS, CODOCITOS Y PUNTEADO BASÓFILO

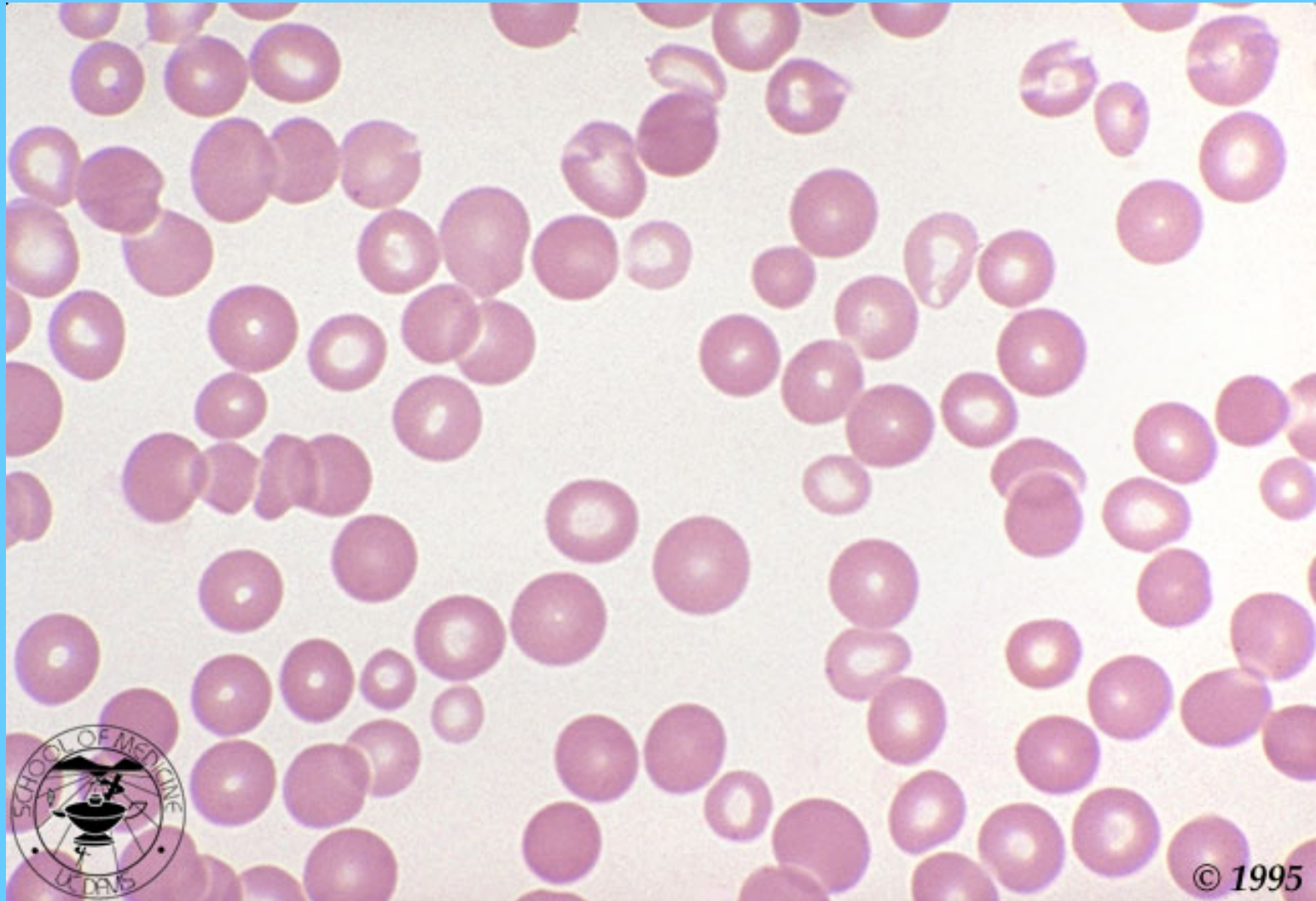


TALASEMIA MAYOR

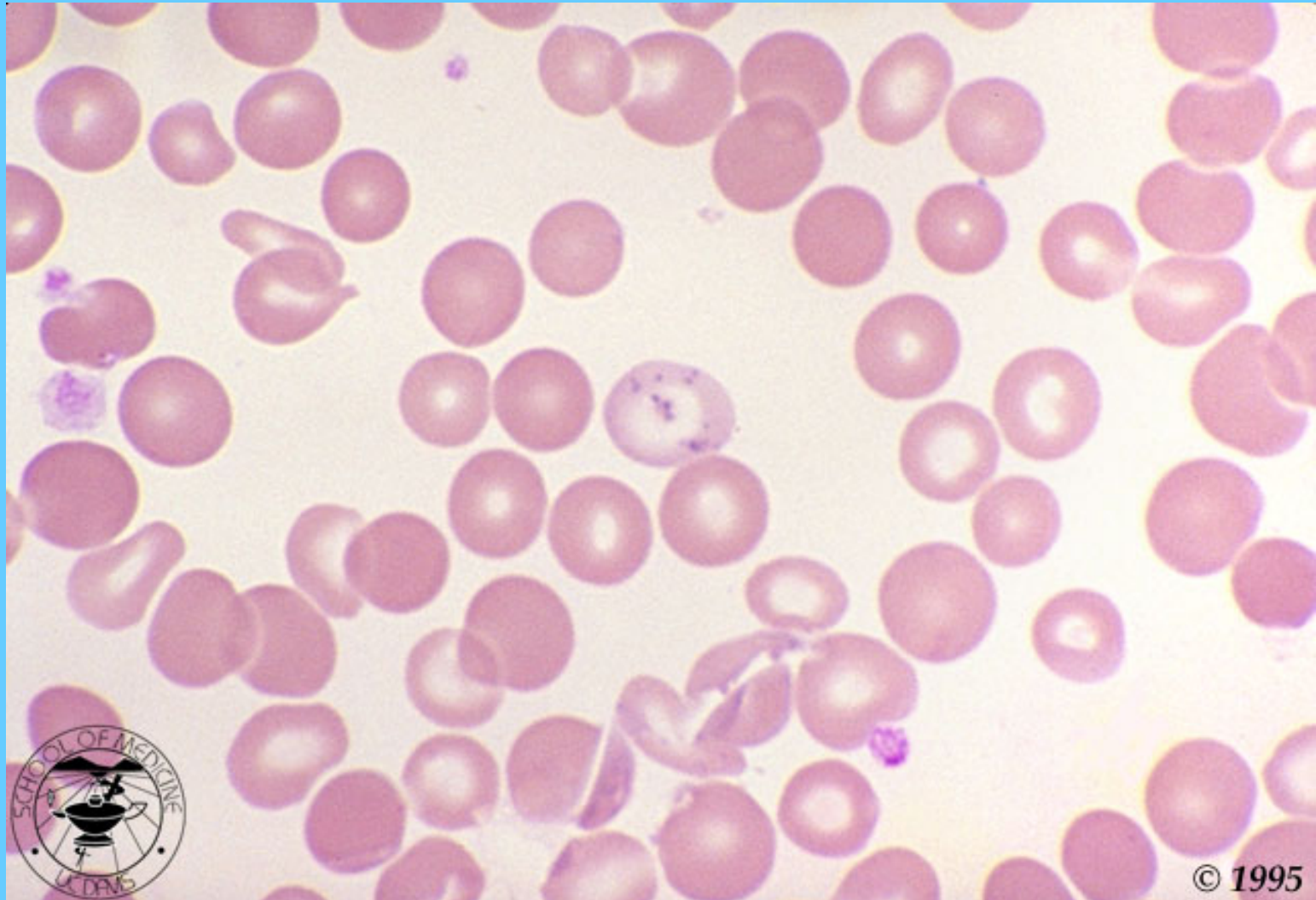

ANEMIA SIDEROBLASTICA

(DOS POBLACIONES UNA NORMAL Y LA OTRA MICROCÍTICA HIPOCRÓMICA)

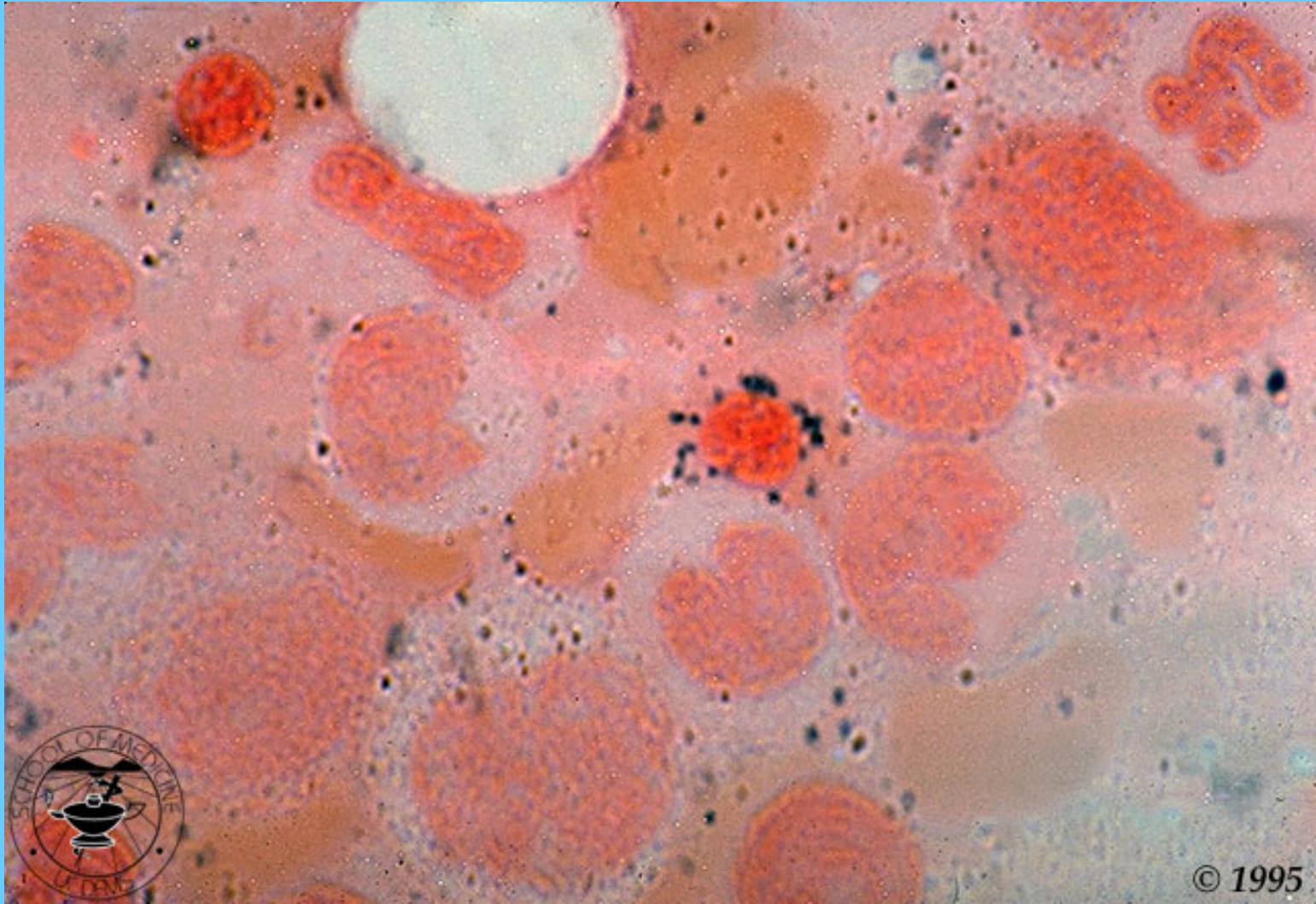


ANEMIA SIDEROBLASTICA CUERPO DE PAPANHEIMER

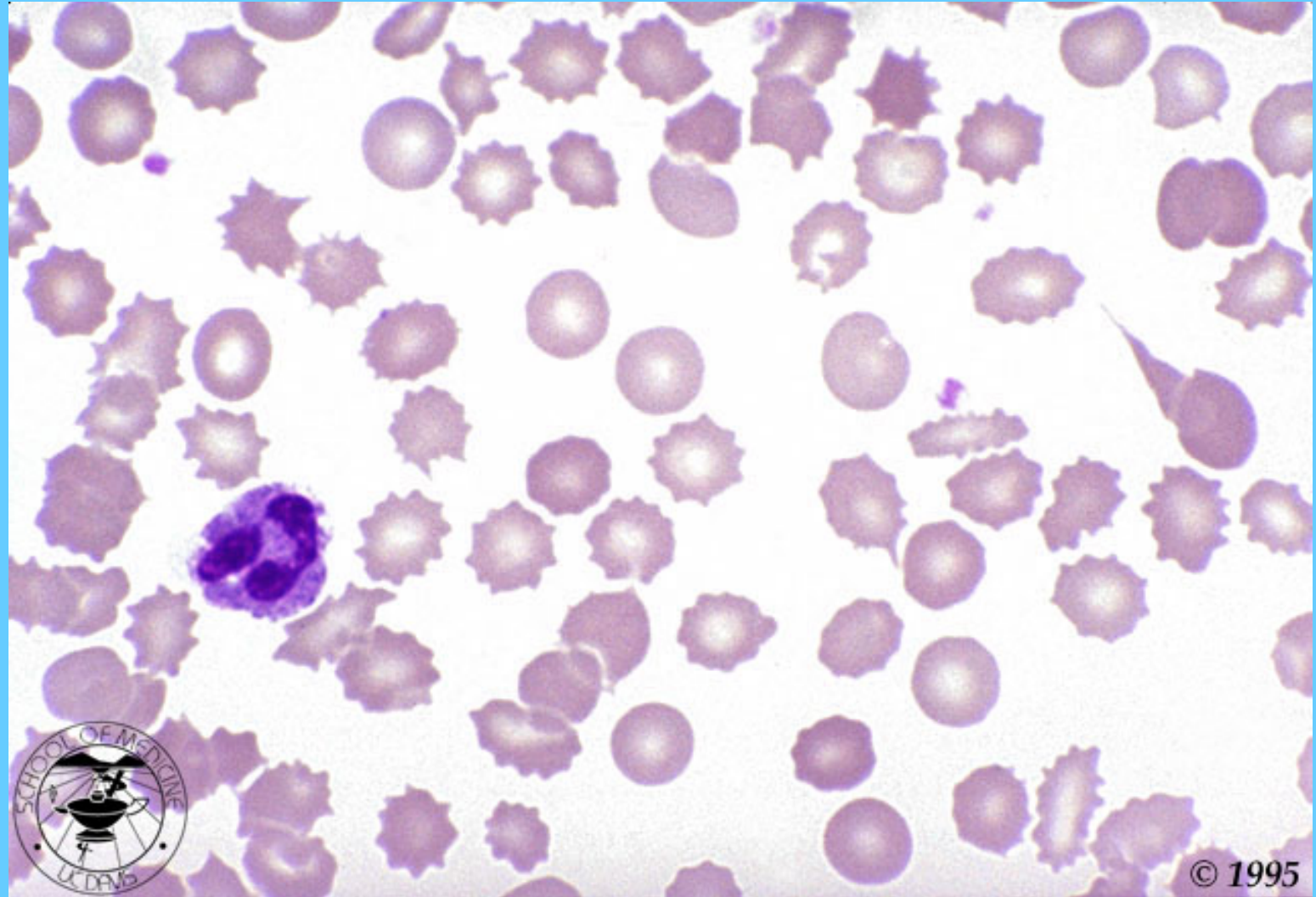


ANEMIA SIDEROBLASTICA

TINCIÓN DE AZUL DE PRUSIA EN M.O.



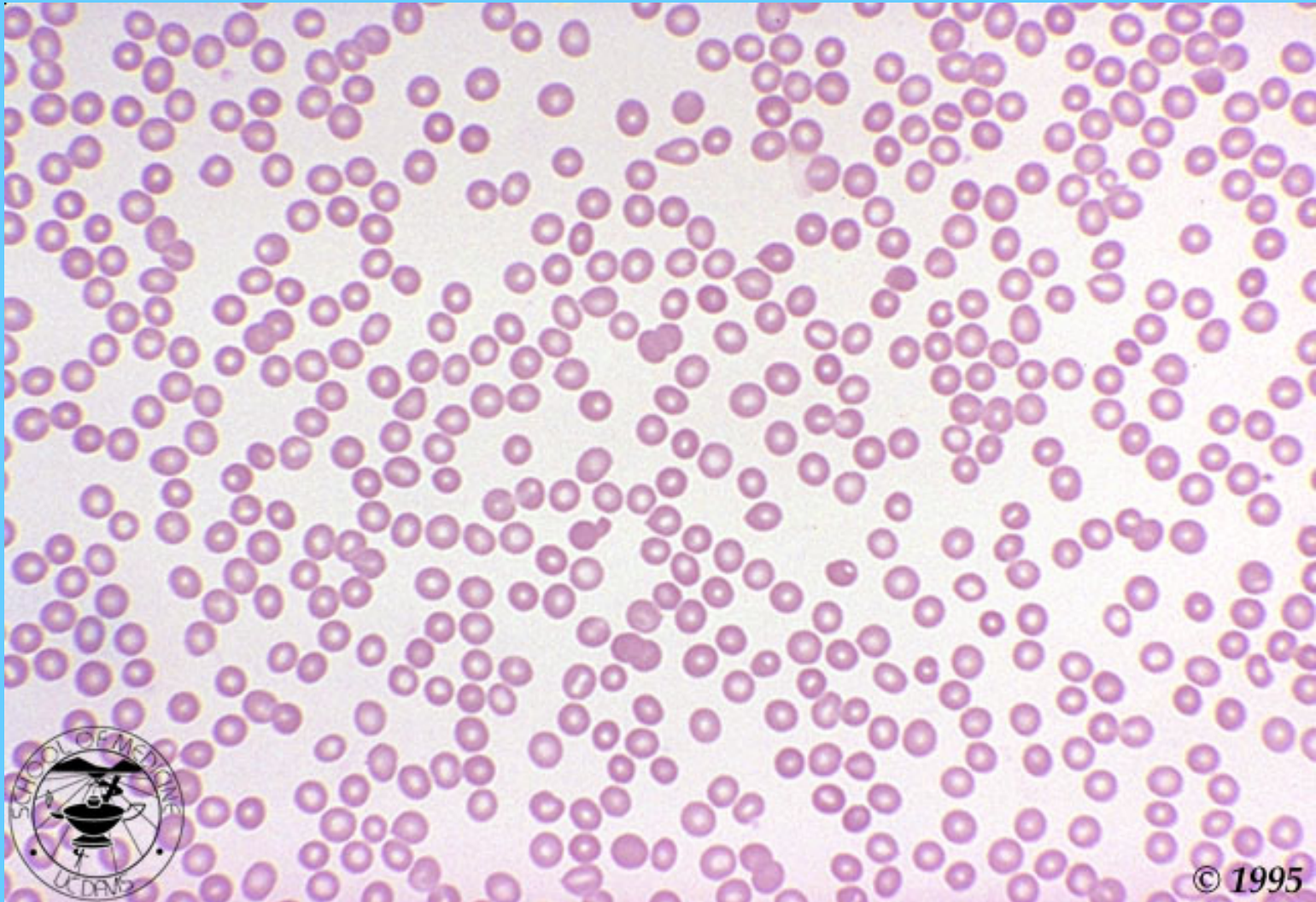
INSUFICIENCIA RENAL



© 1995

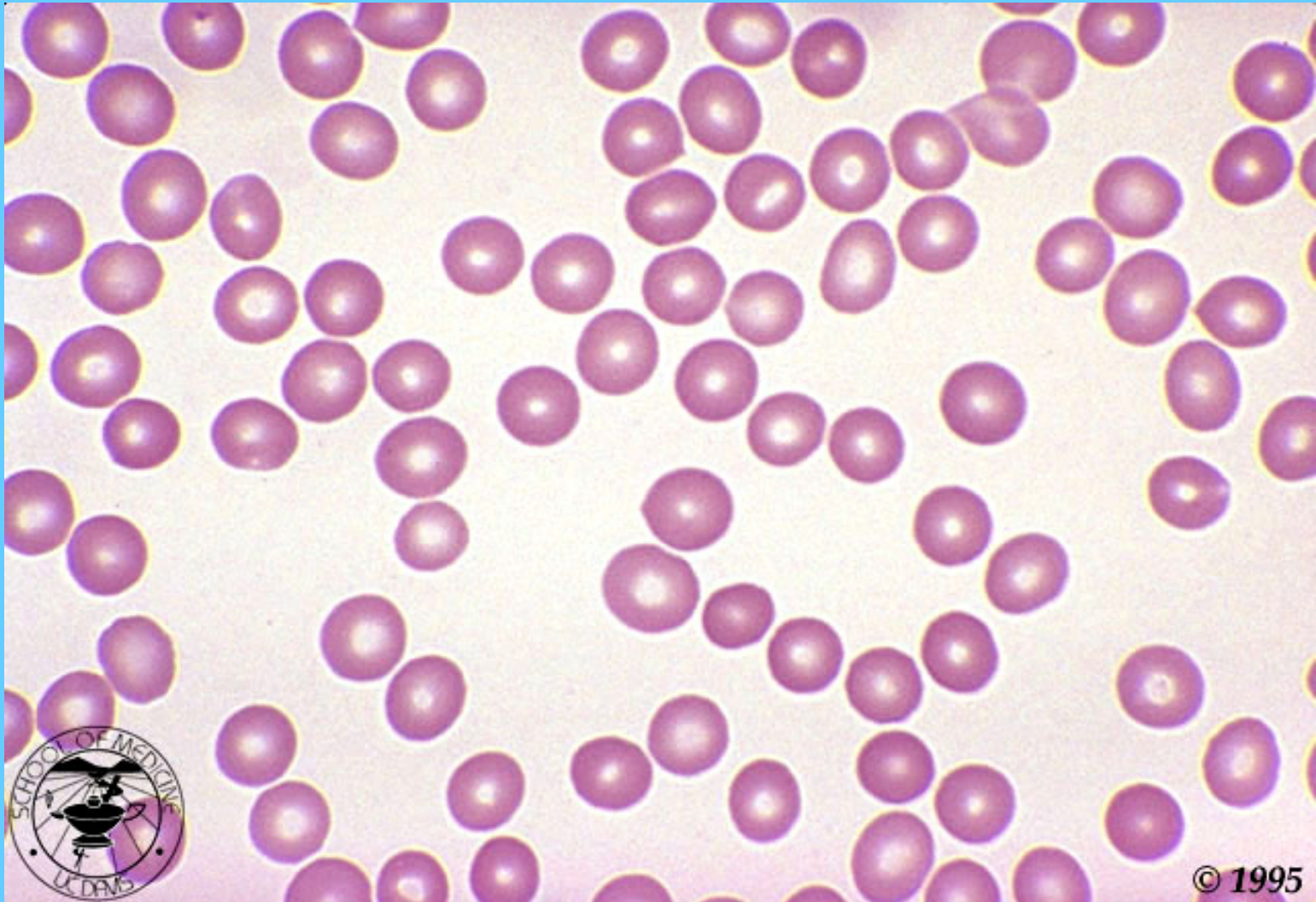ANEMIA APLÁSICA

(NOTE LA AUSENCIA DE PLAQUETAS Y DE LEUCOCITOS)



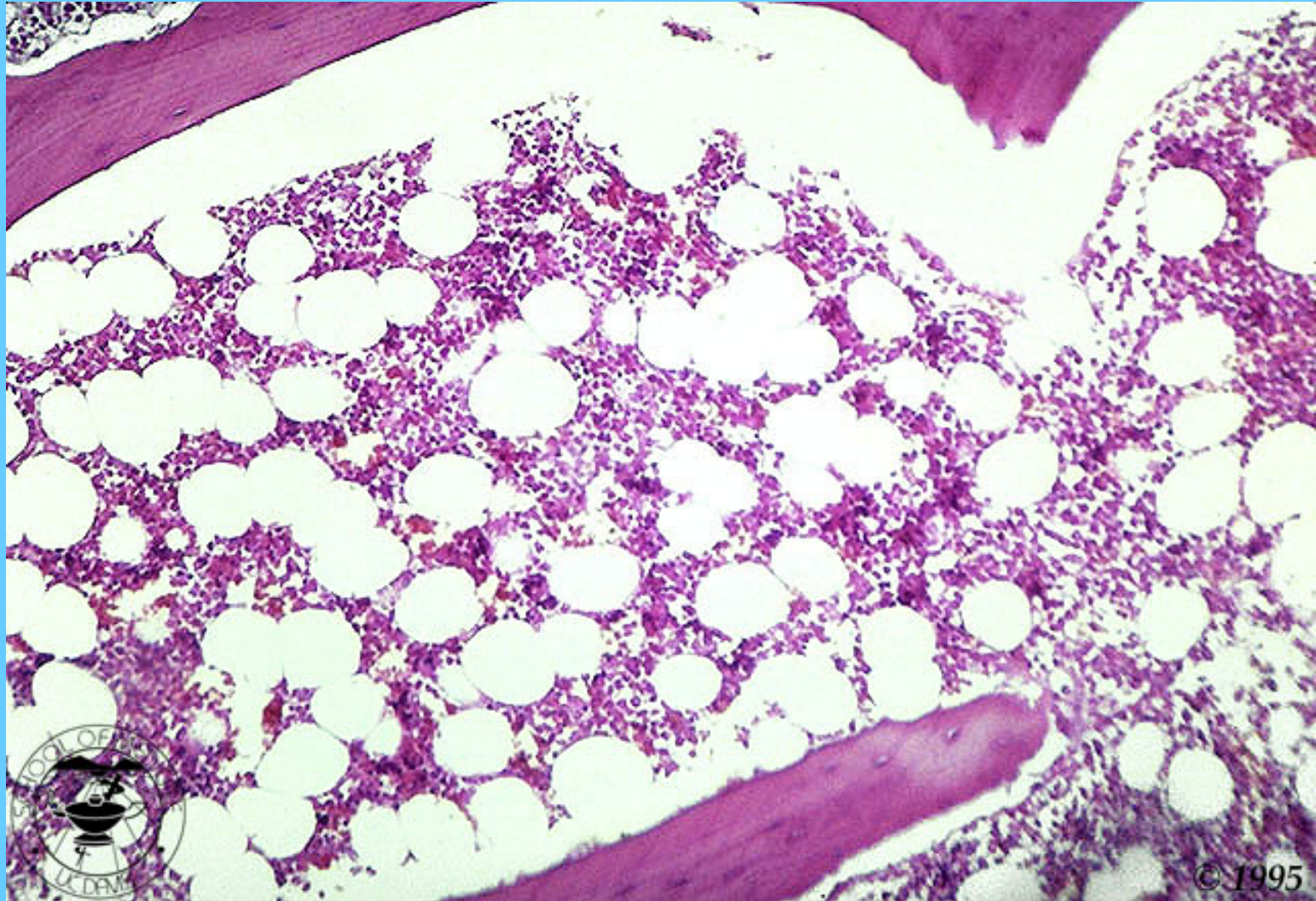
© 1995

ANEMIA APLÁSICA



© 1995

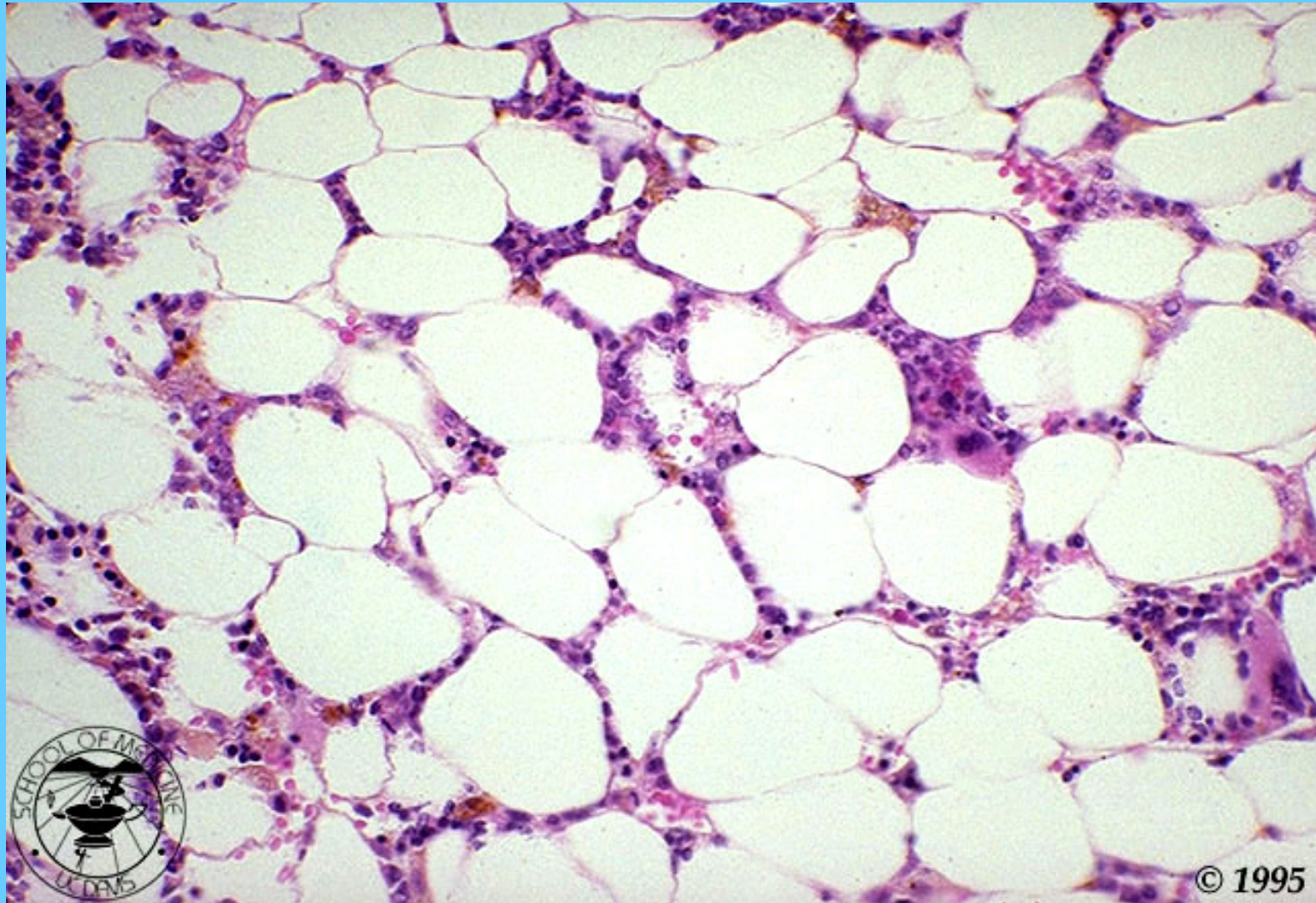
MEDULA ÓSEA NORMAL BIOPSIA



© 1995

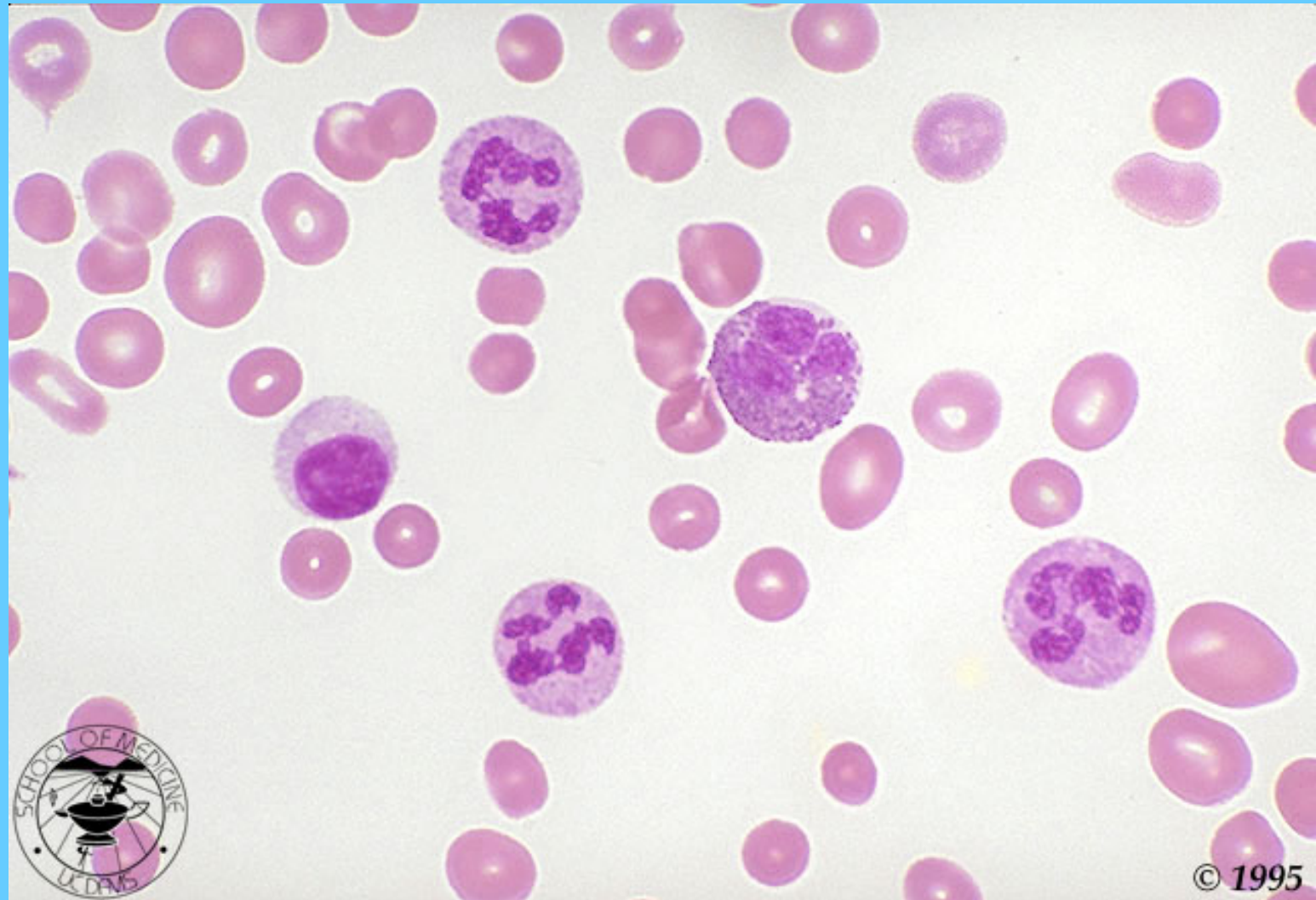
ANEMIA APLÁSICA

BIOPSIA DE M.O



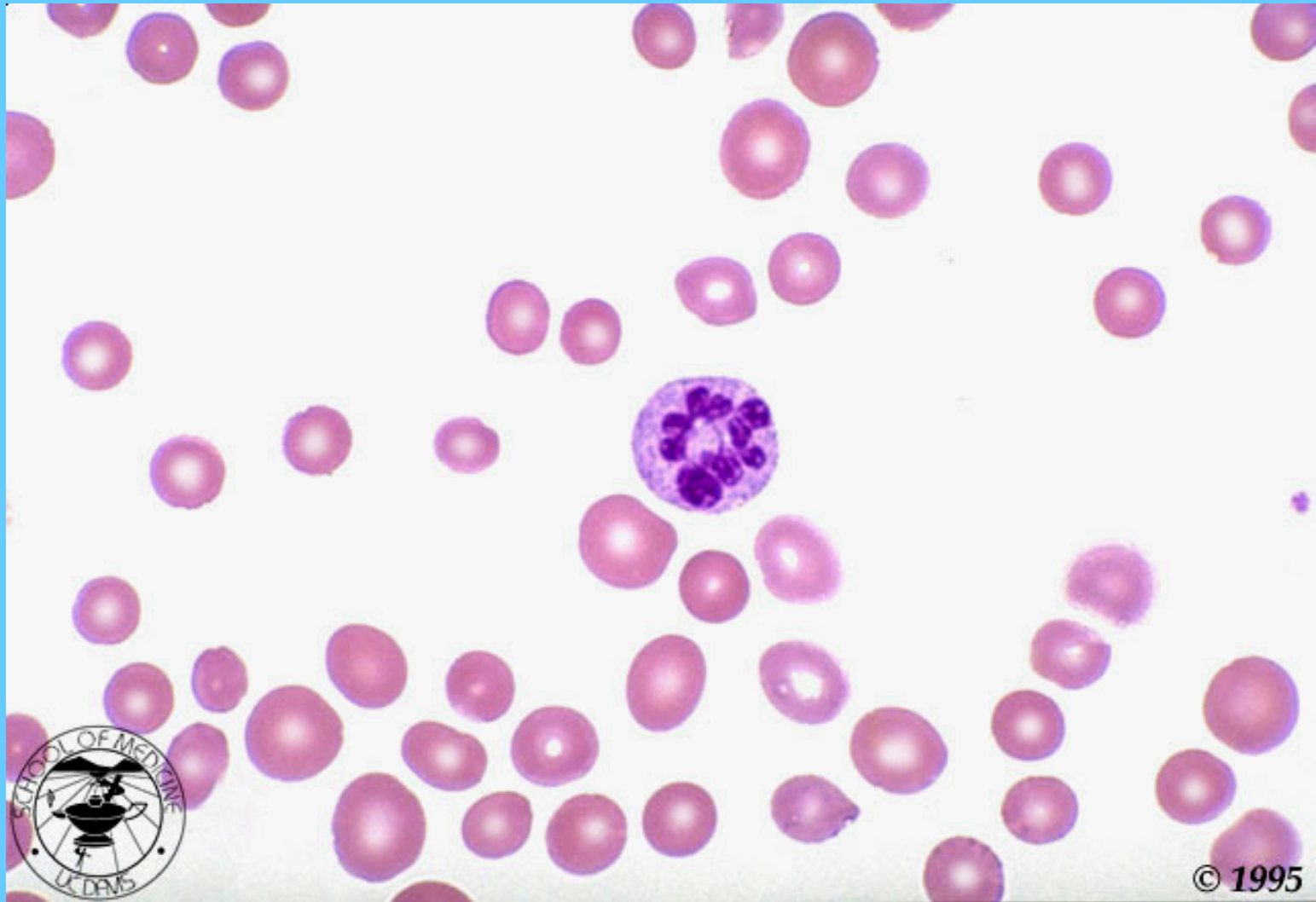
ANEMIA MEGALOBLÁSTICA

MACROCITOS, HIPERSEGMENTACIÓN, PLAQUETOPENIA



© 1995

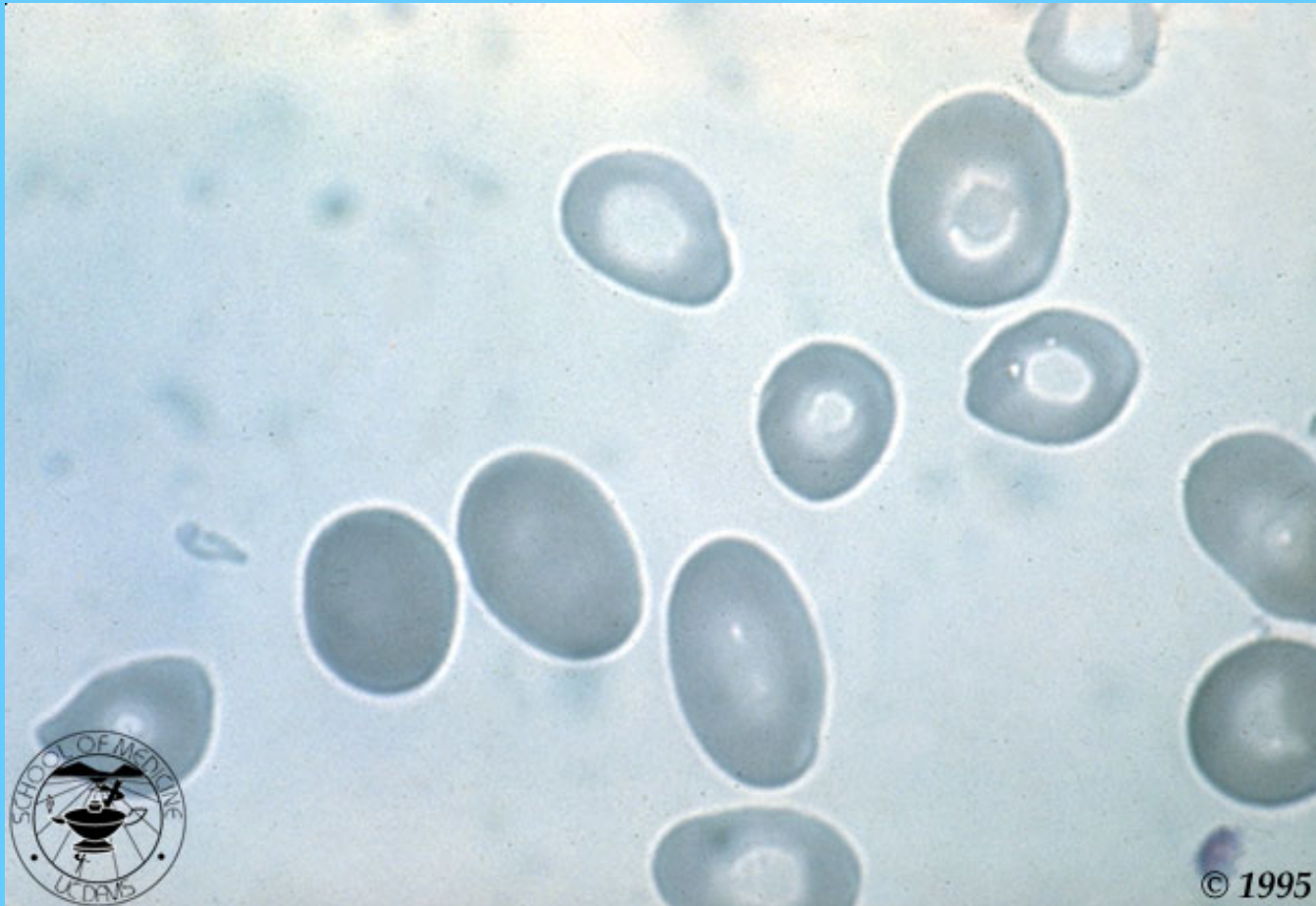
ANEMIA MEGALOBLÁSTICA



© 1995

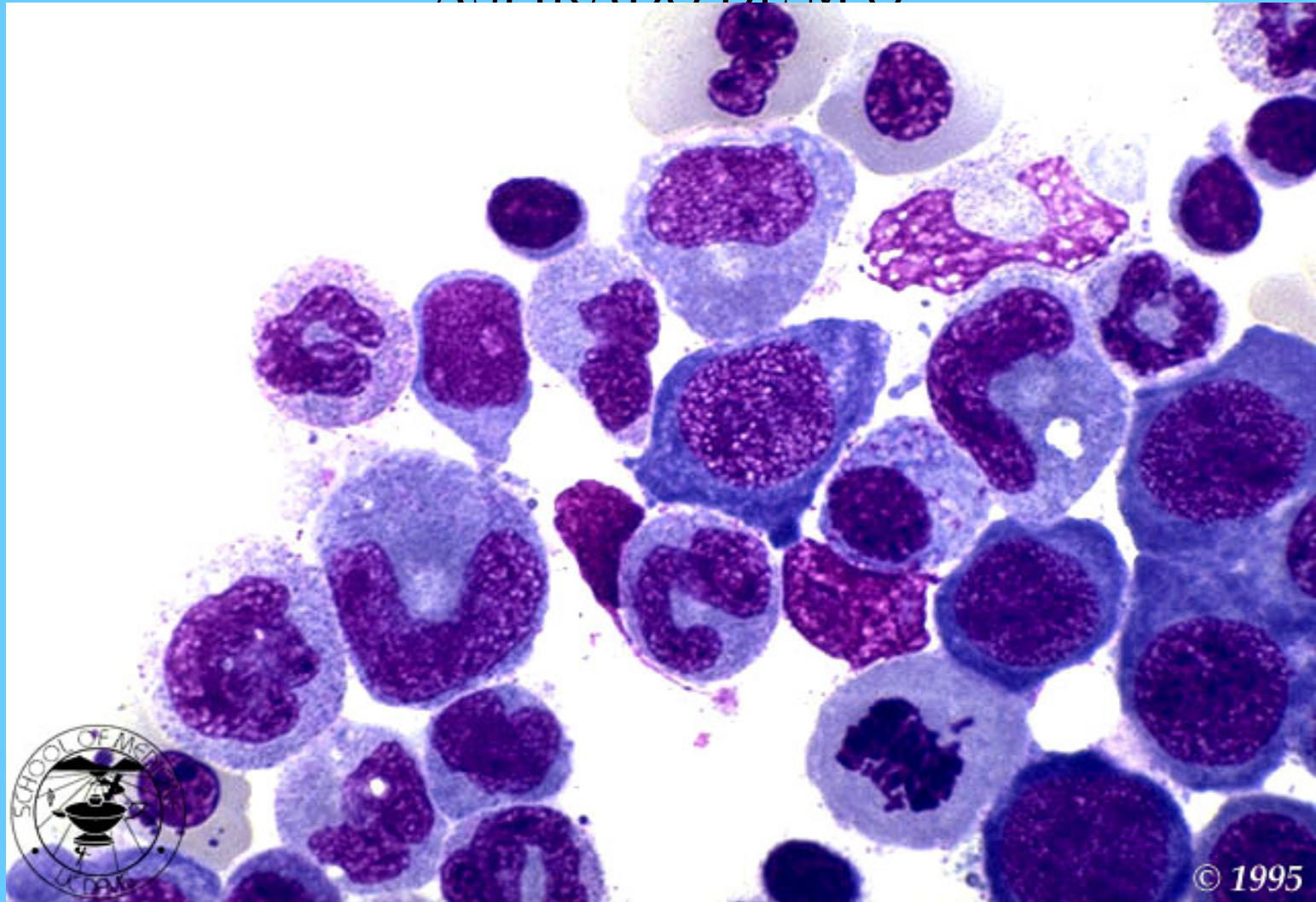
ANEMIA MEGALOBLÁSTICA

MACROOVALOCITOS



ANEMIA MEGALOBLÁSTICA

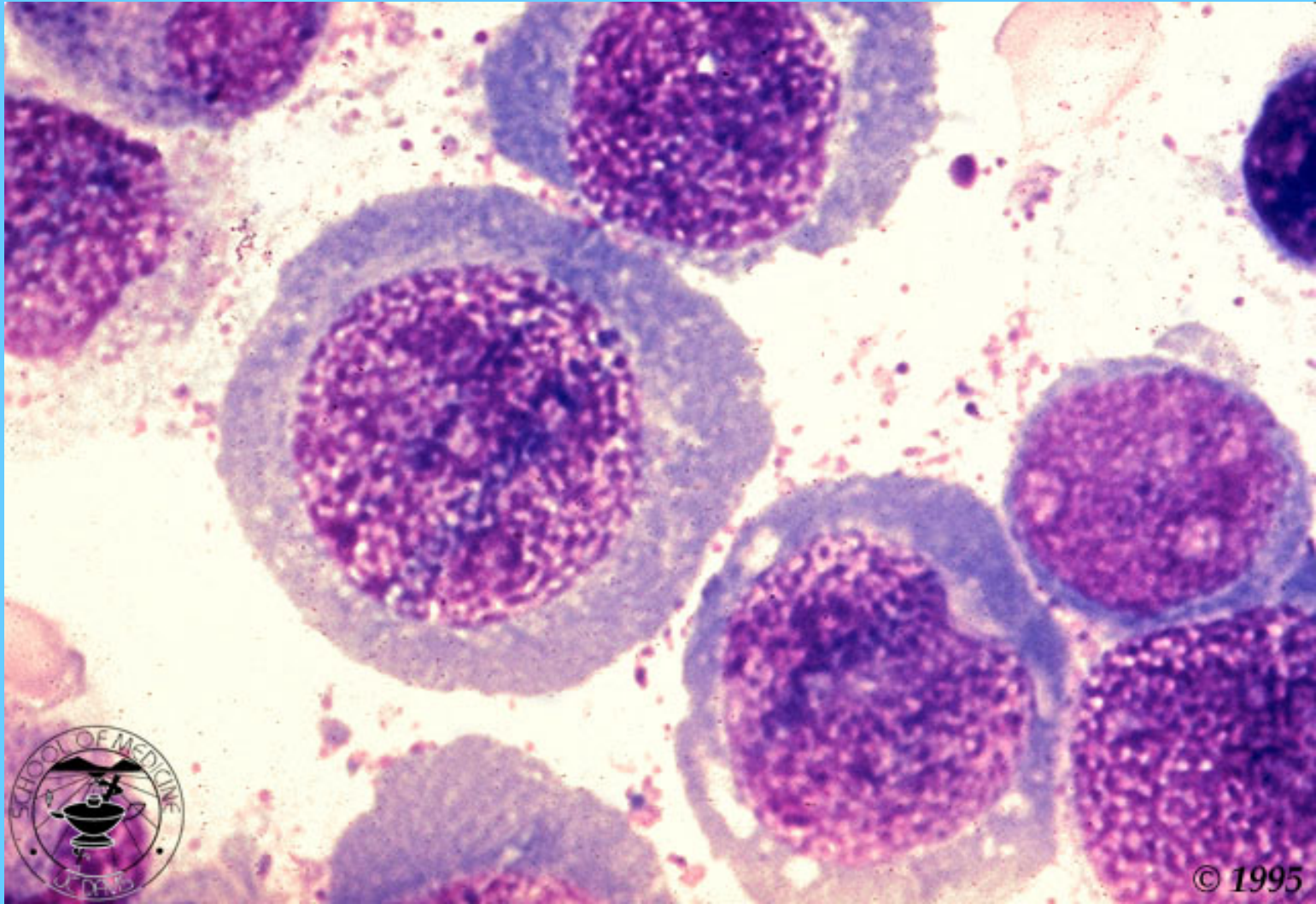
ASPIRADO DE M.O



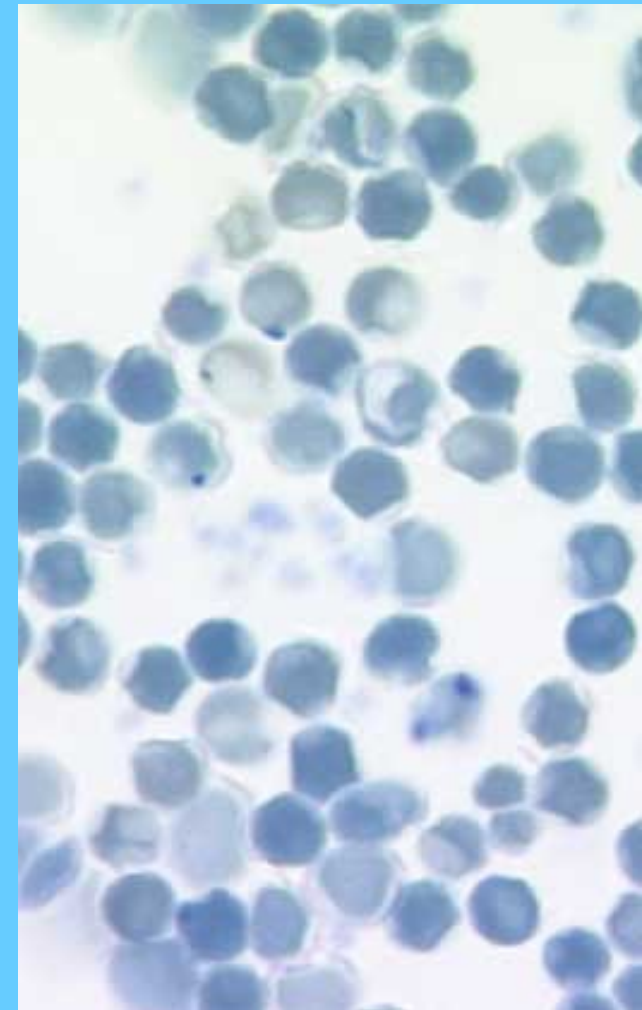
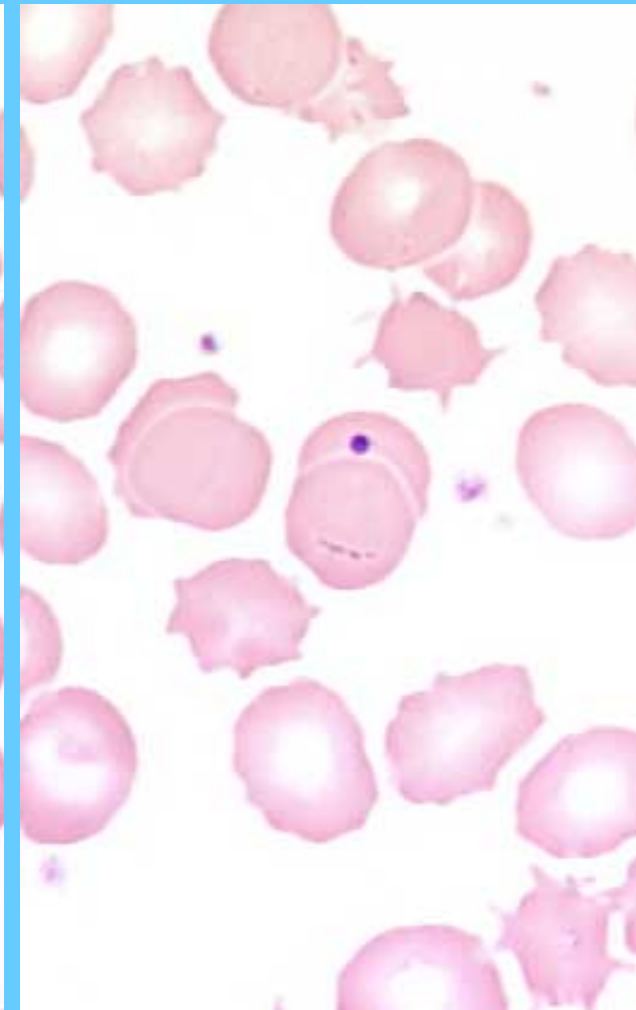
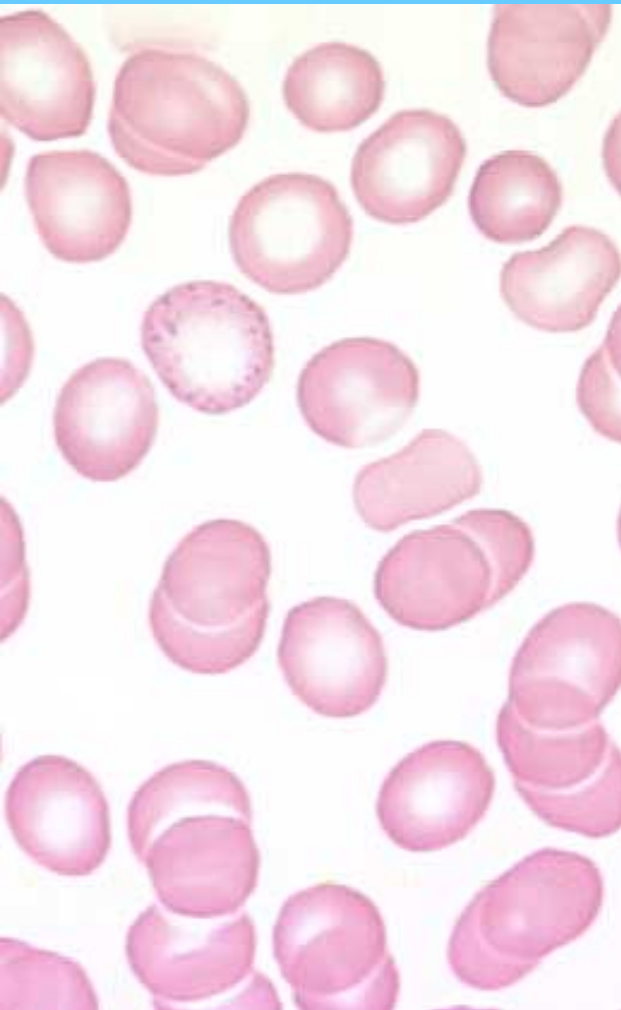
PRESURSORES GRANDES, TANTO DE ERITROCITOS COMO DE LEUCOCITOS, CON ASINCRONIA CELULAR (DISPERSIÓN DE CROMATINA CON CITOPLASMA MÁS MADURO)

ANEMIA MEGALOBLÁSTICA

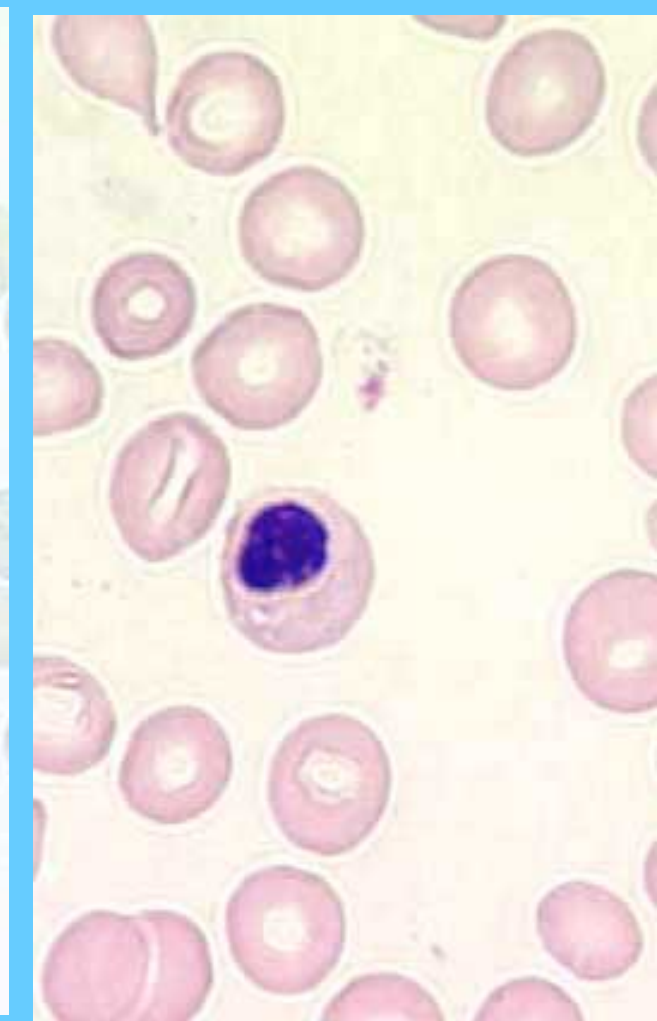
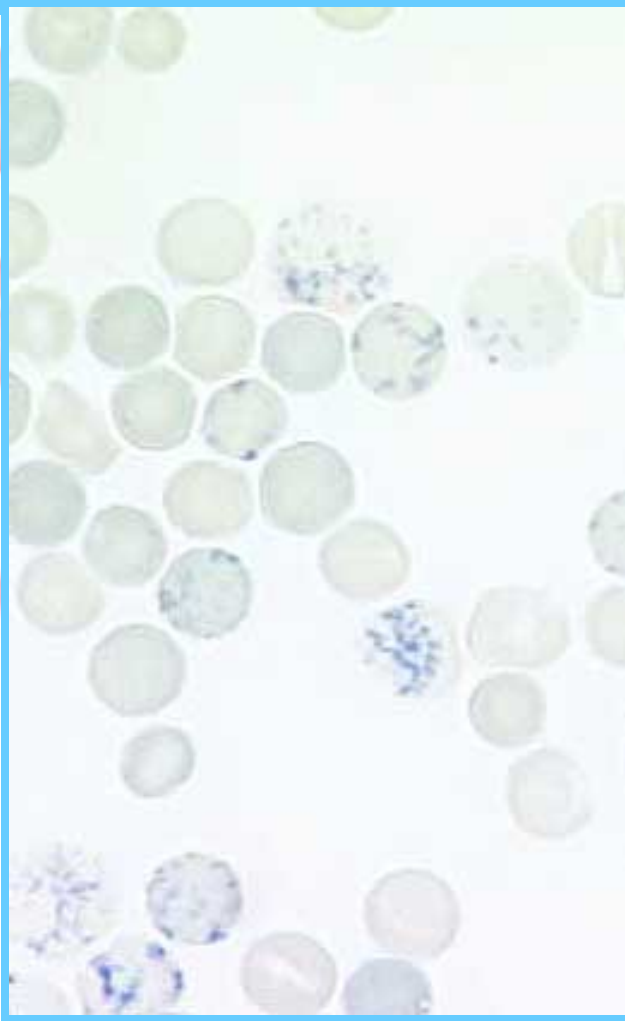
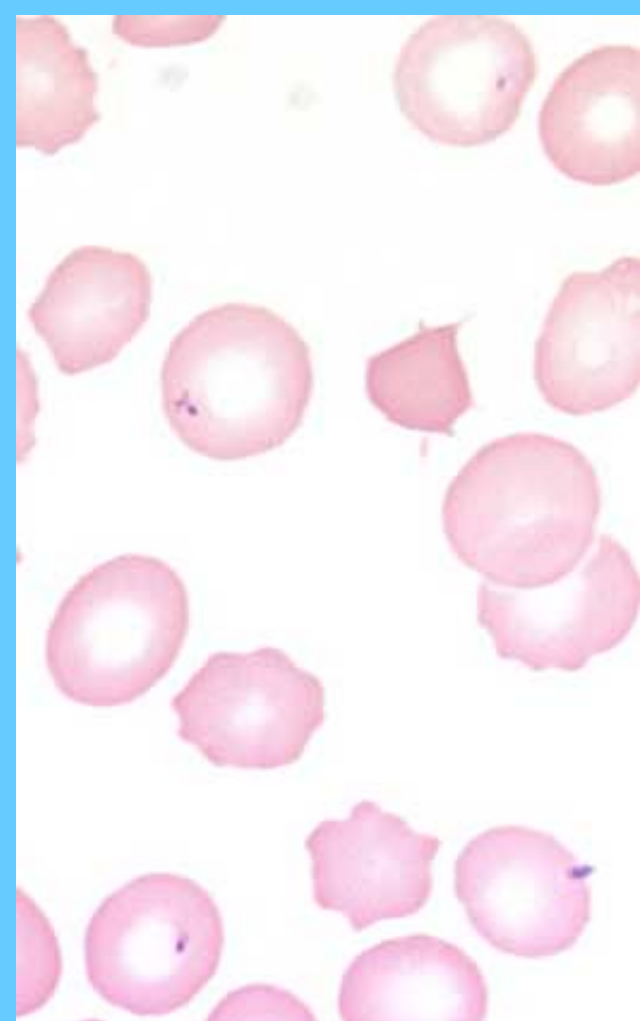M.O. PRECURSORES GIGANTES DE SERIE ROJA



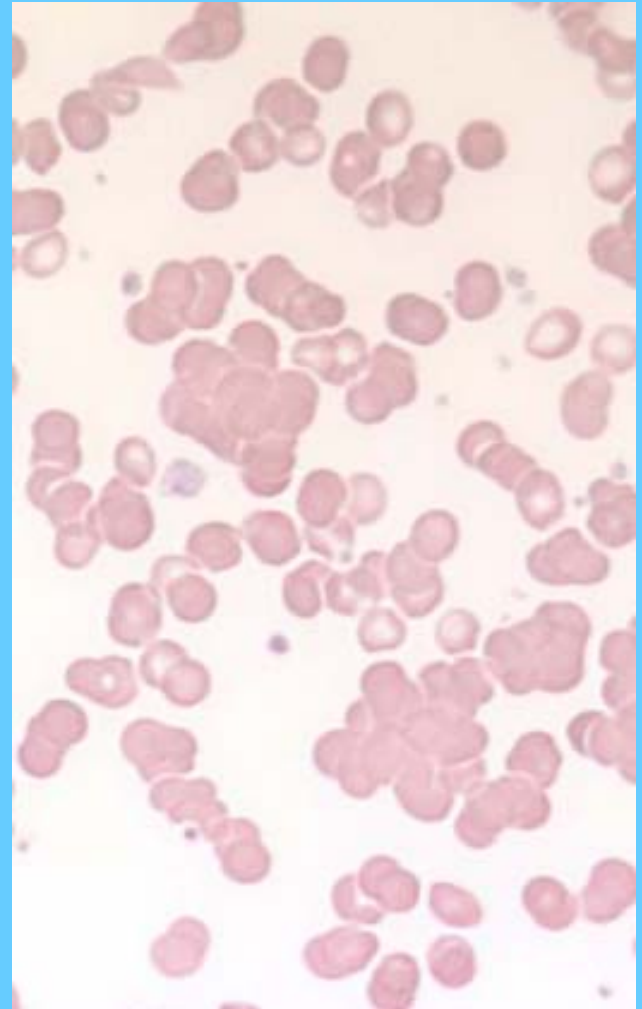
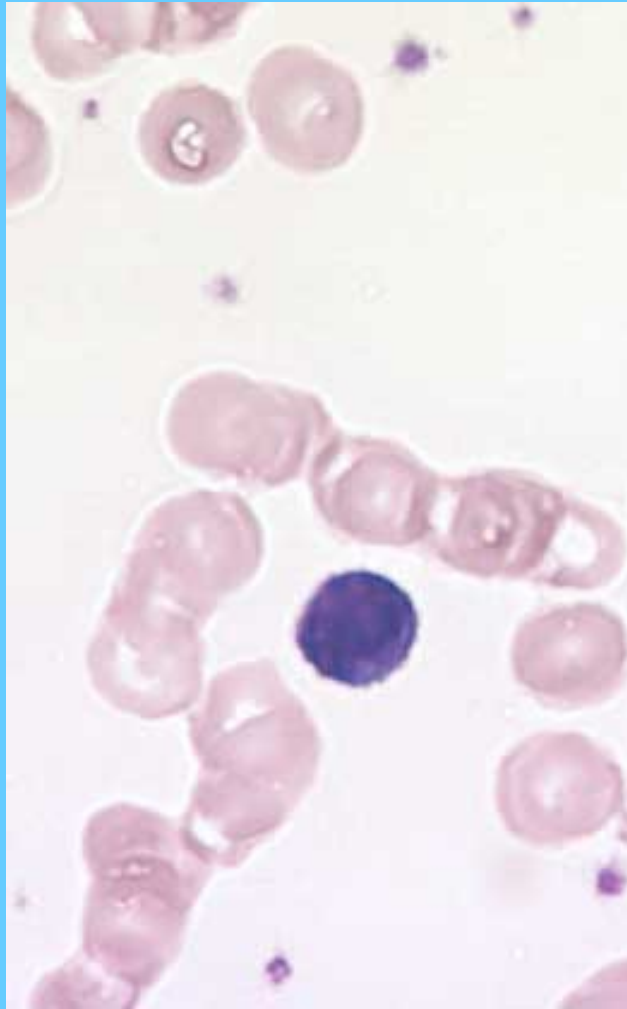
PUNTEADO BASÓFILO (I), CUERPO DE HOWEL-JOLLY (C)

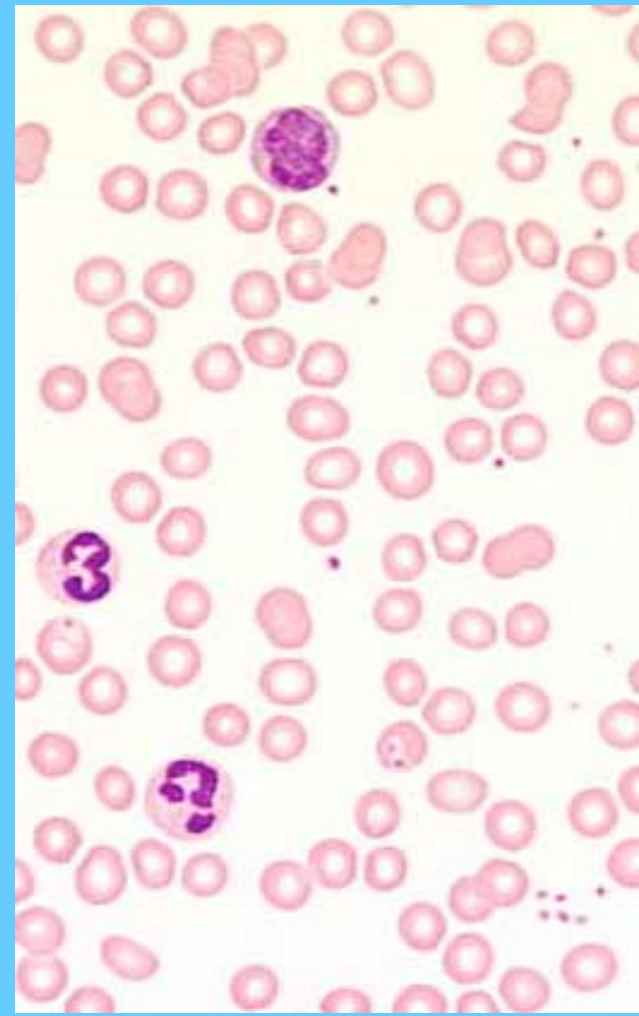
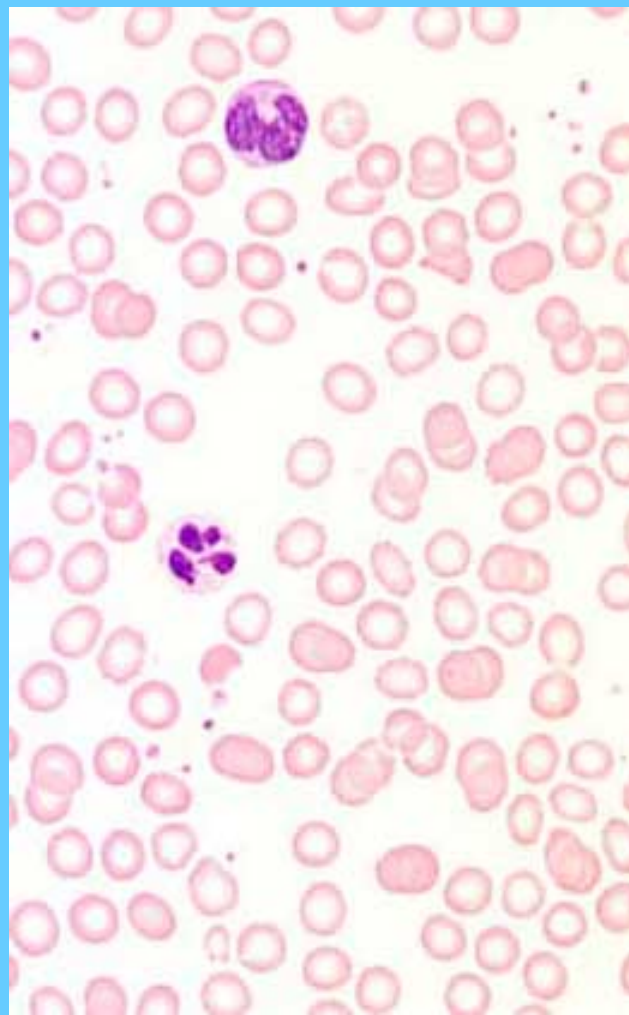
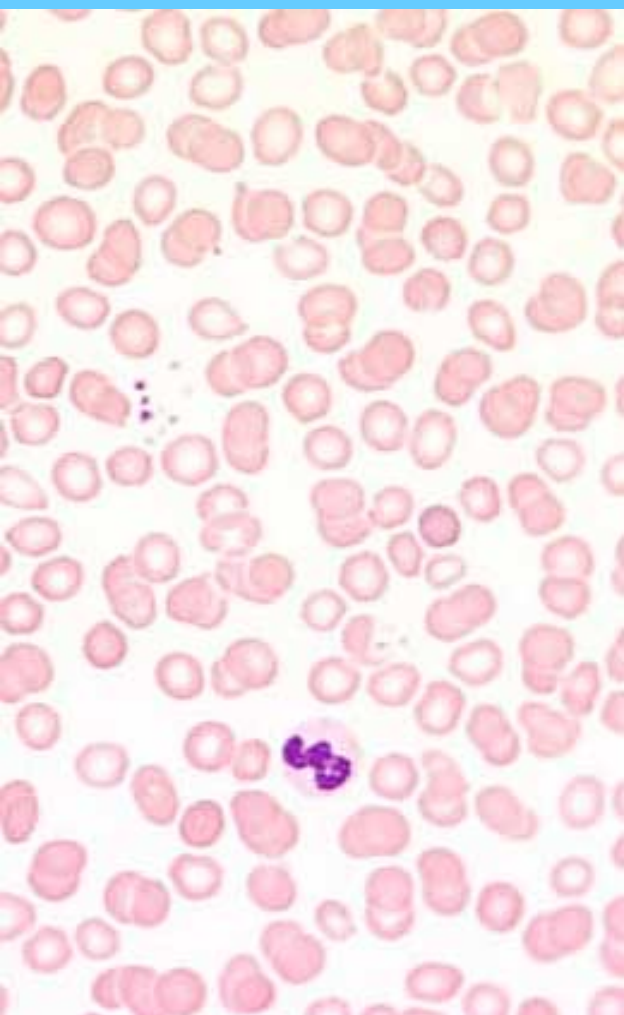

ACANTOCITO (I),RETICULOCITOSIS (C),
ERITROBLASTO (D)

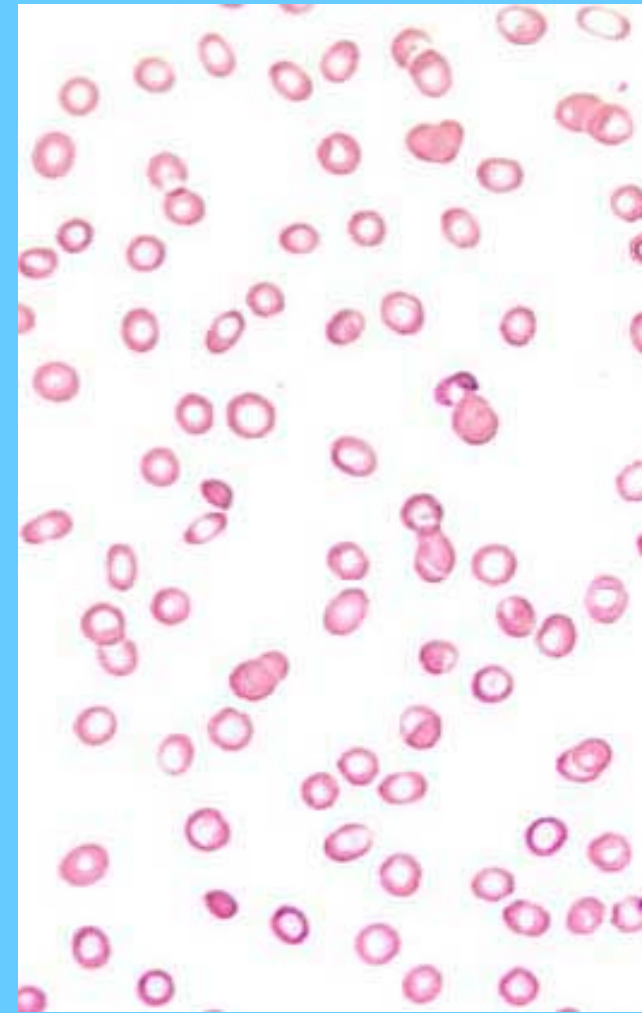
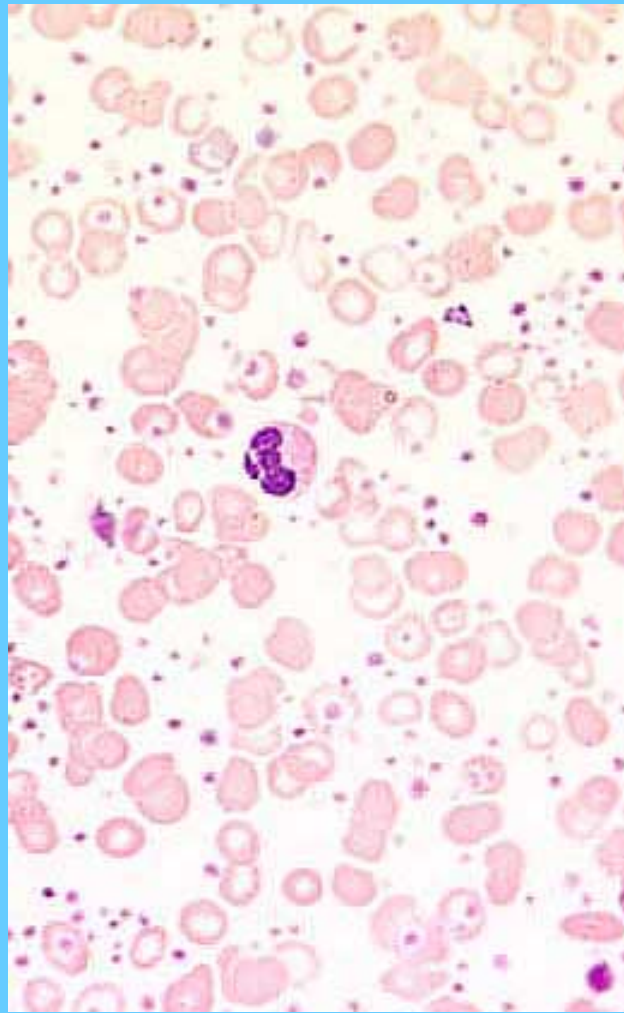
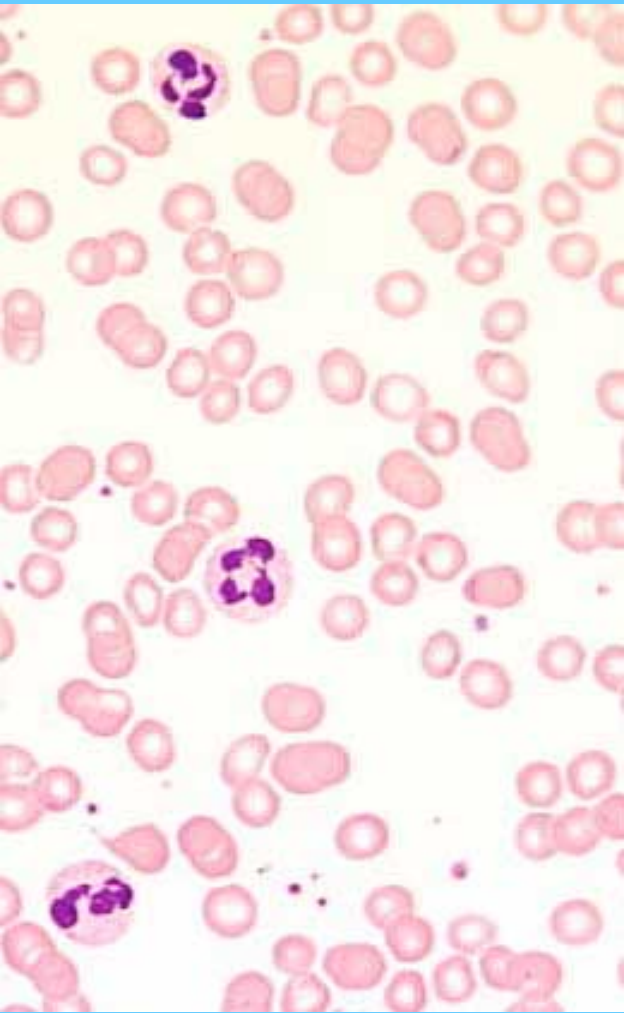


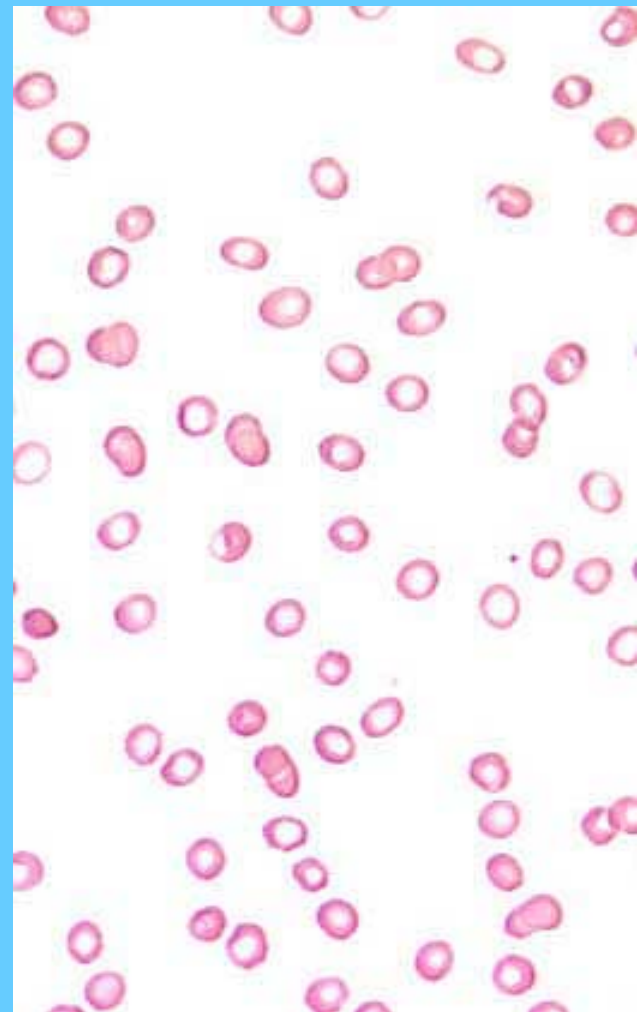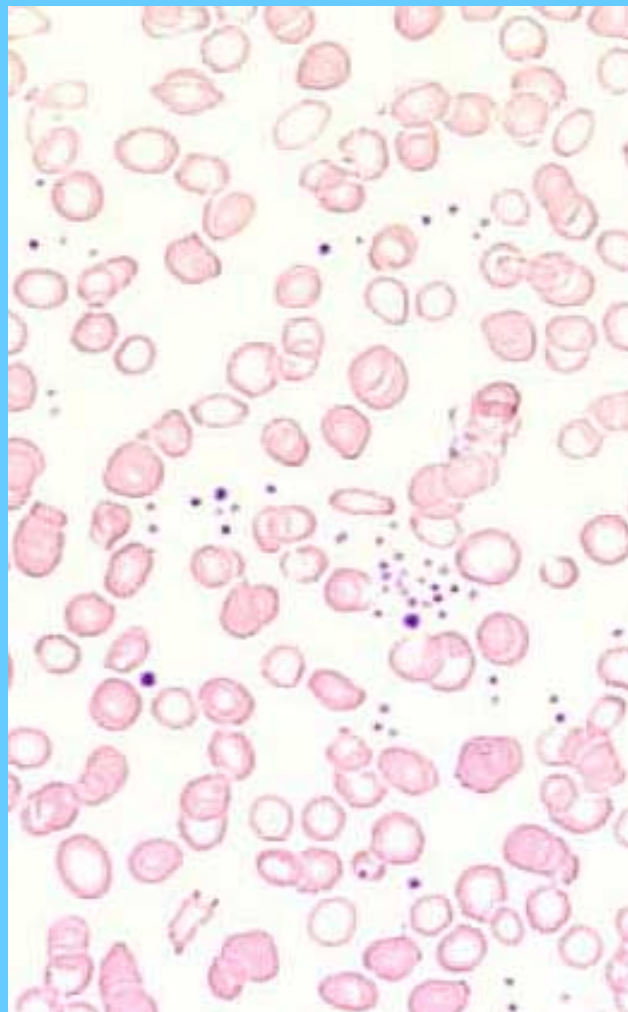
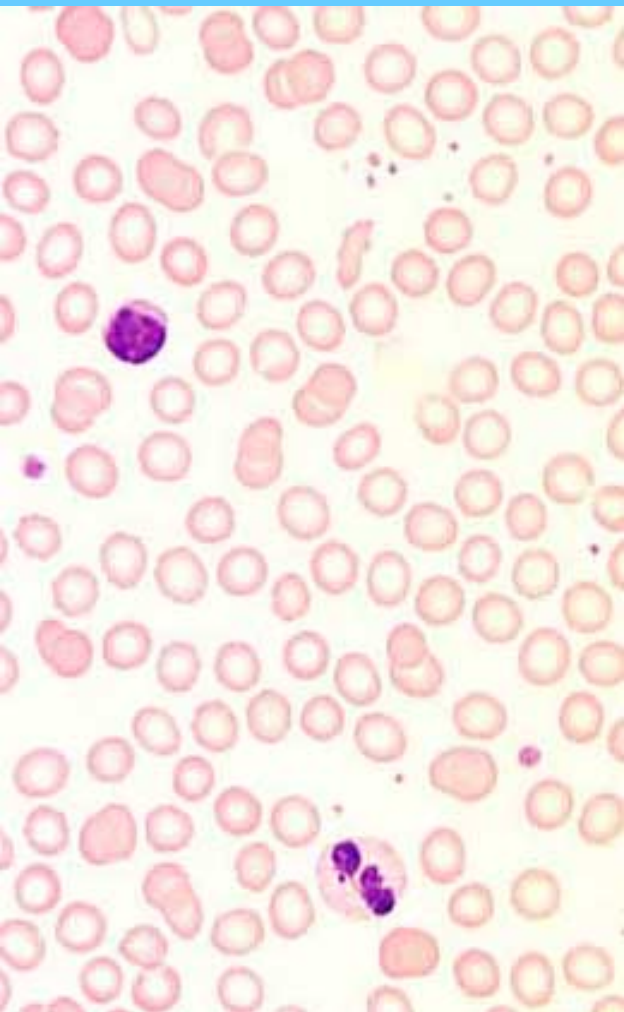
ROULEAUX

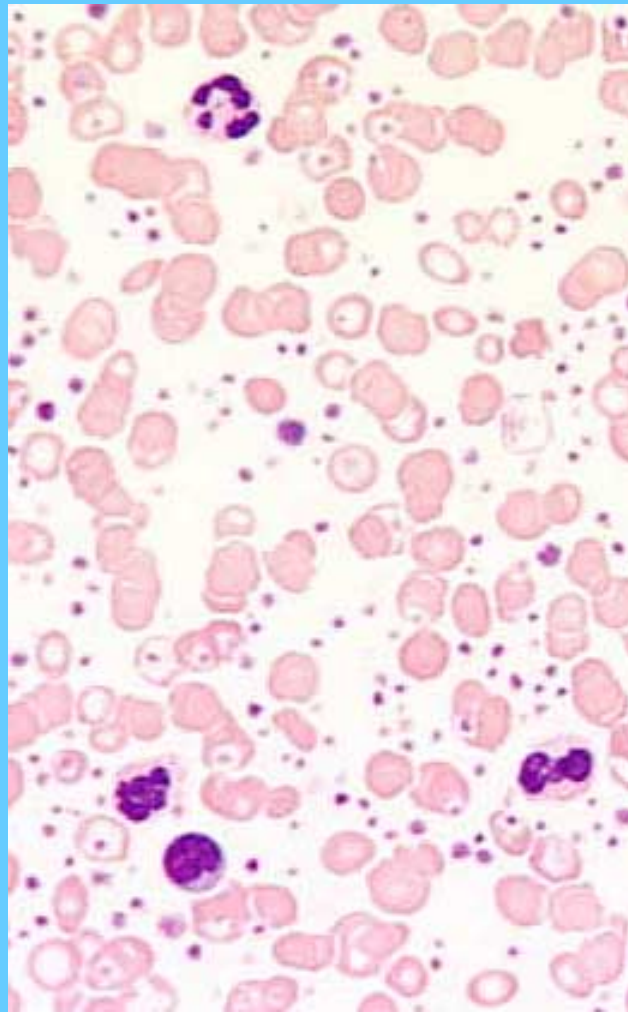
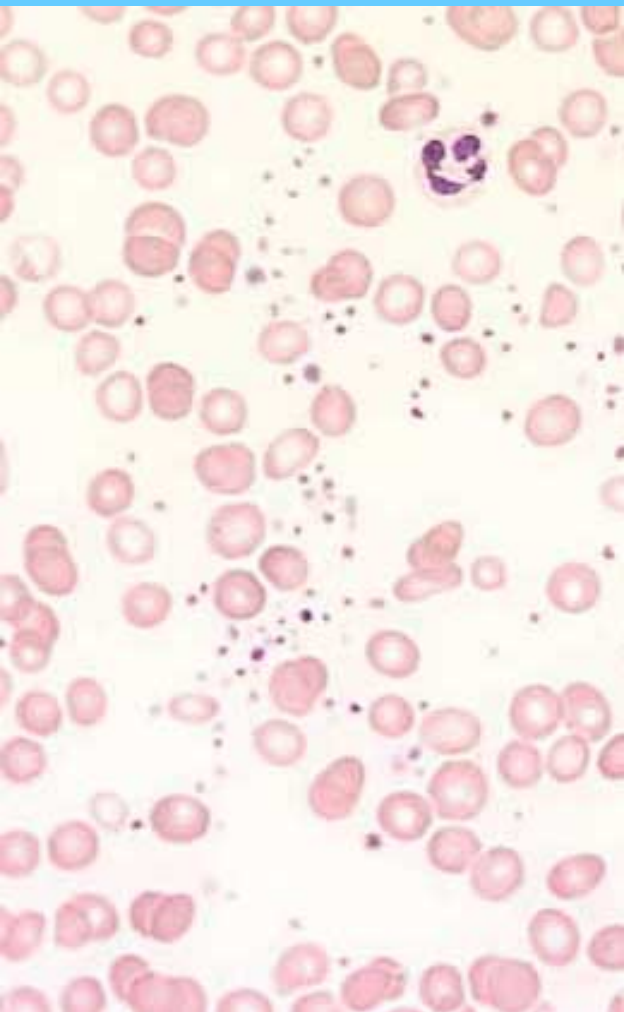


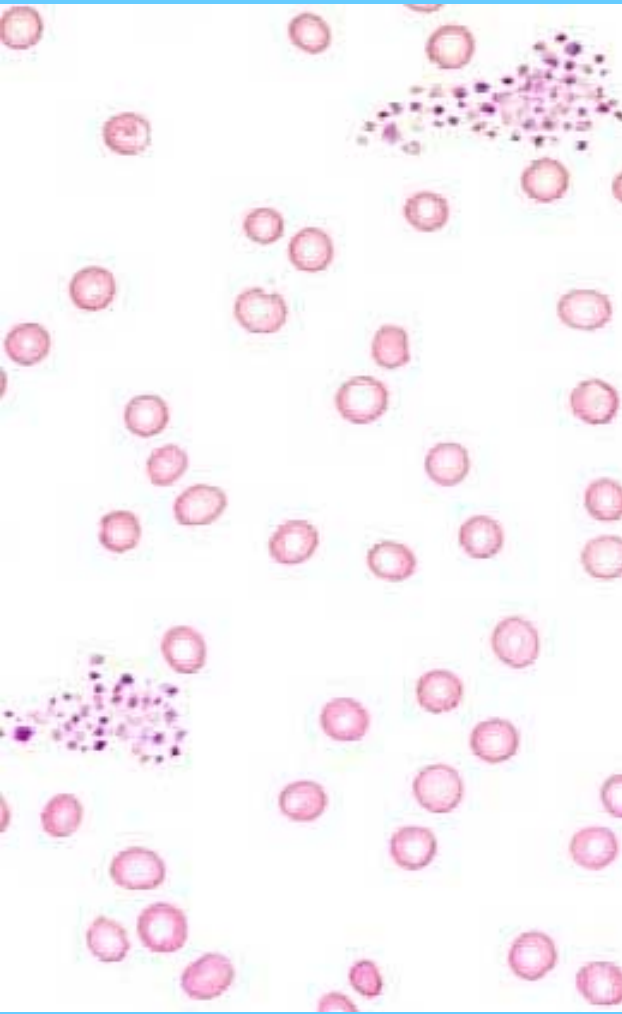


PLAQUETAS NORMALES (I), AUMENTADAS (C), DISMINUIDAS (D)

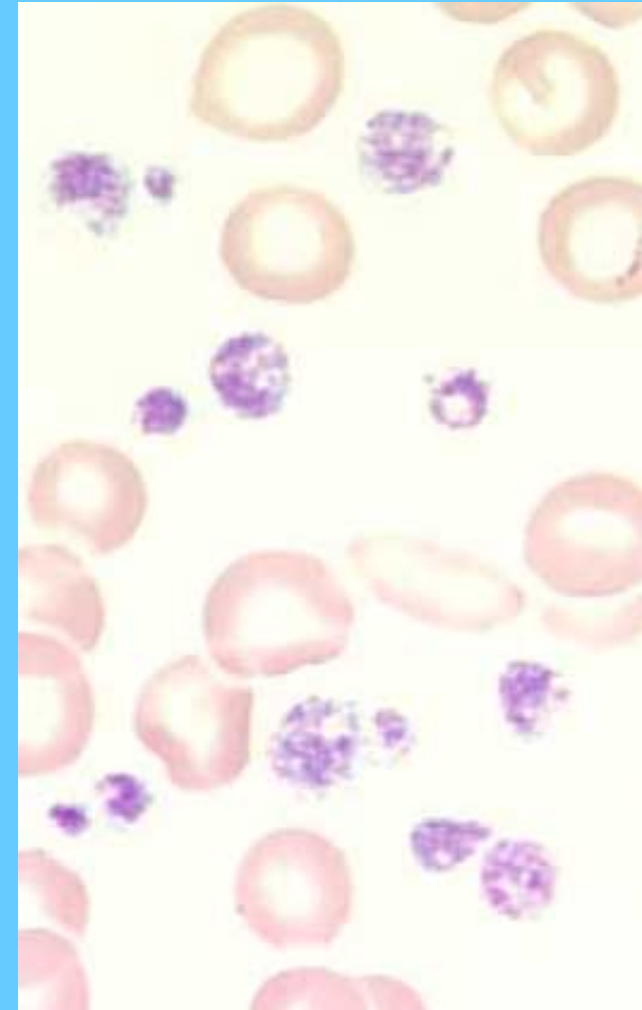
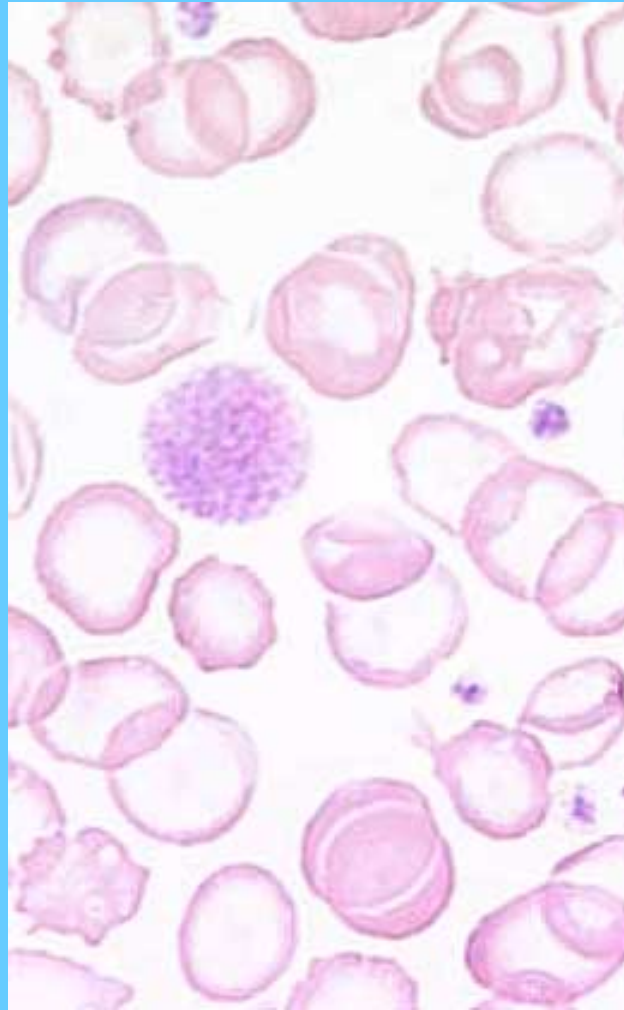
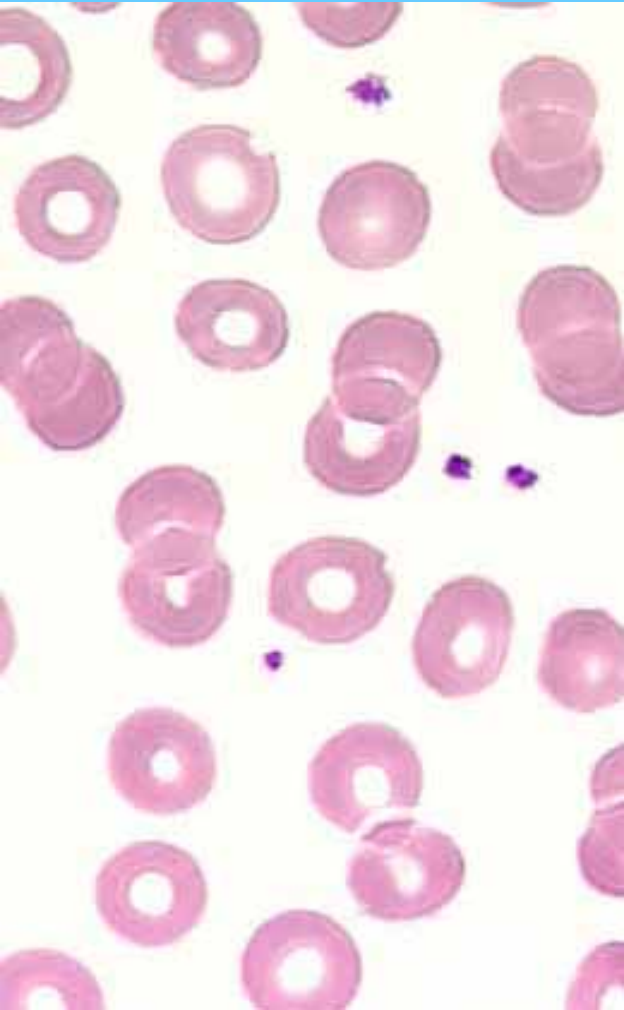




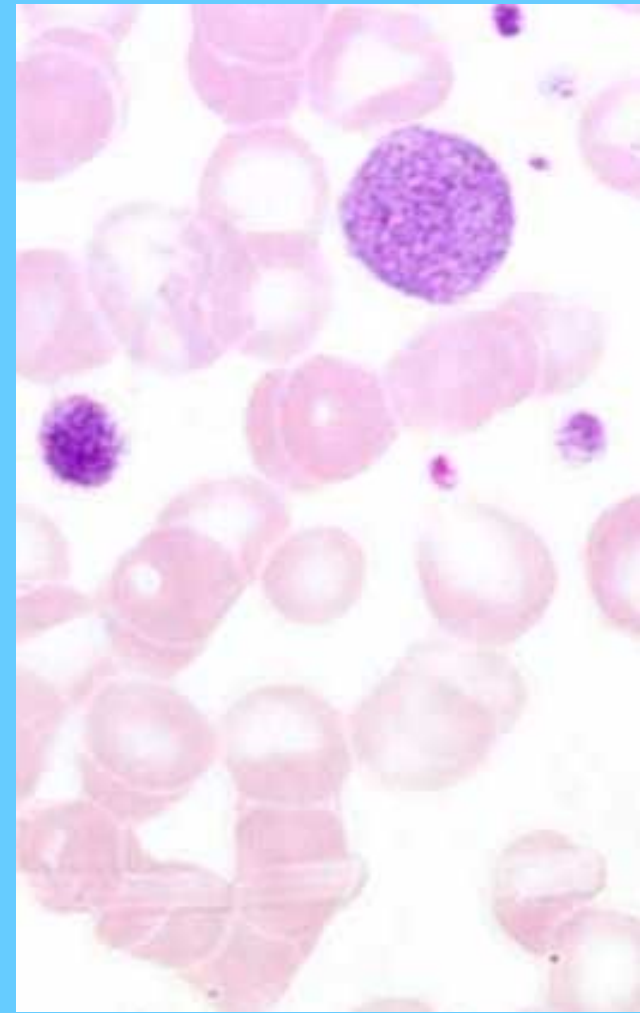
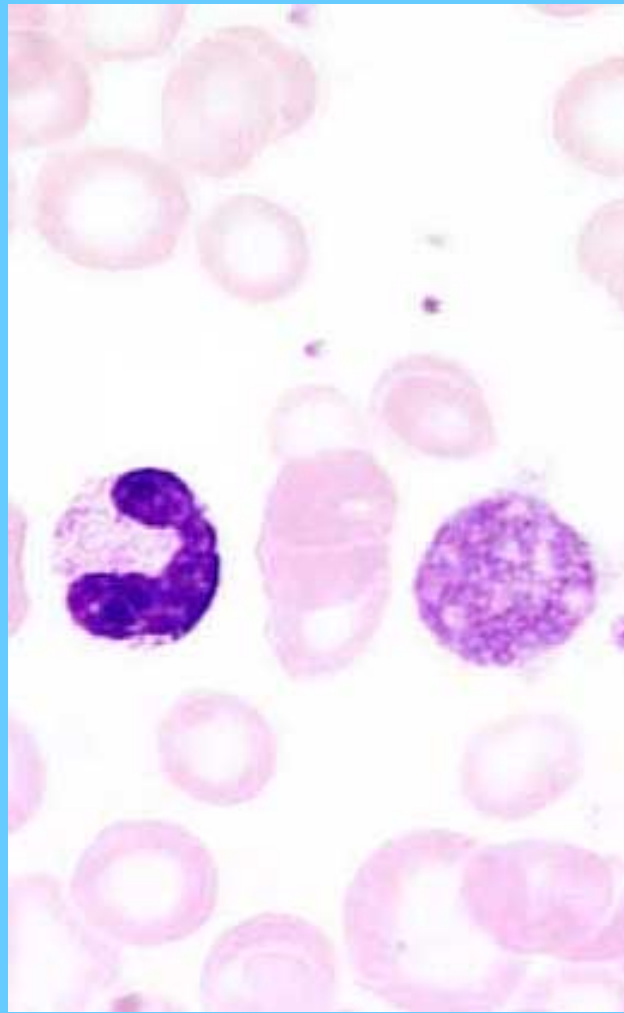
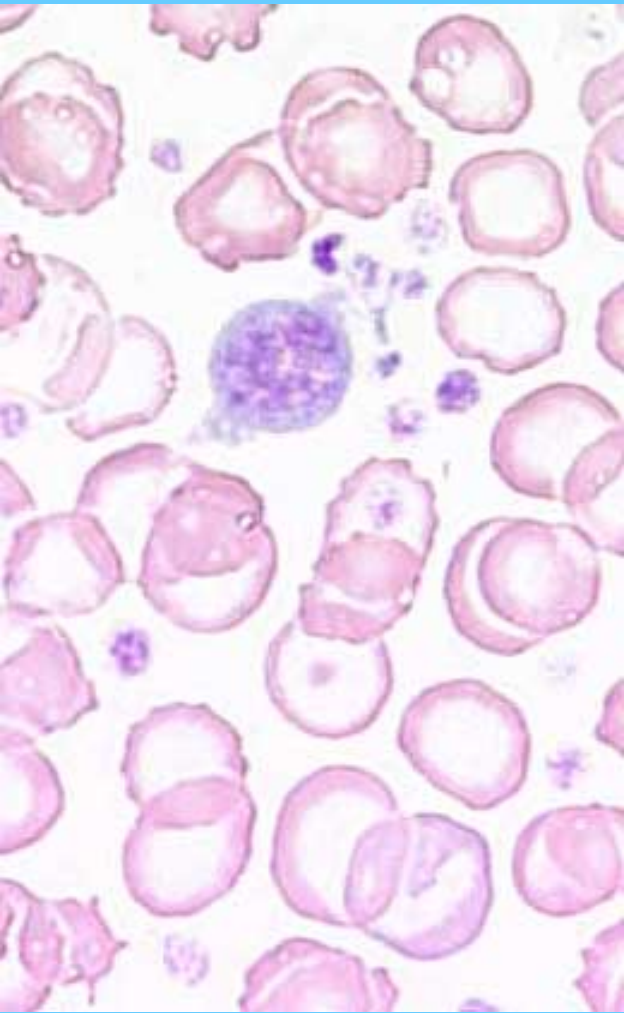


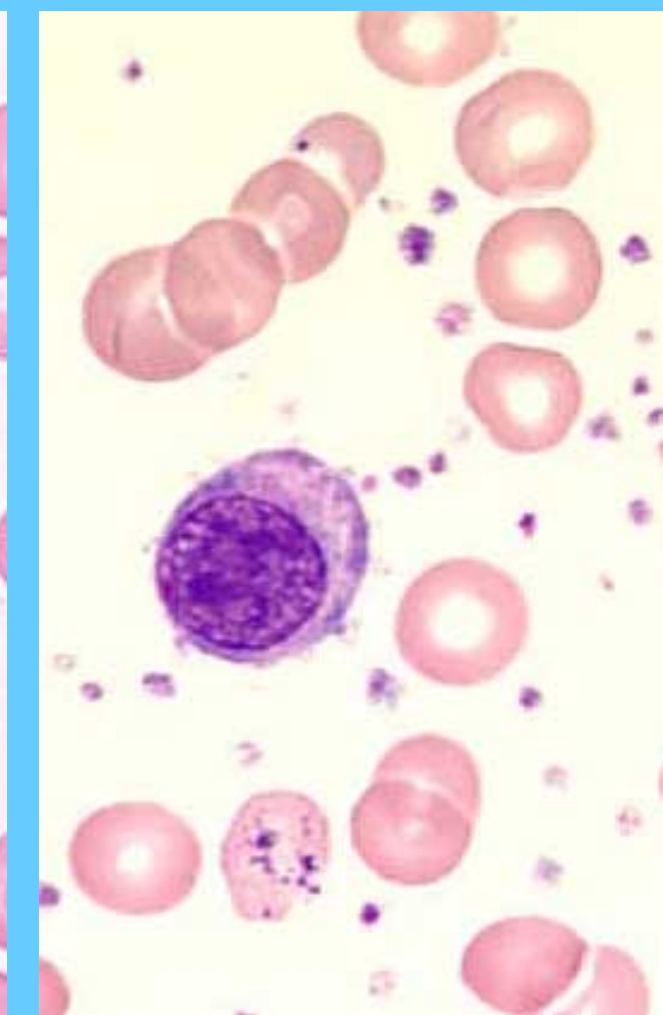
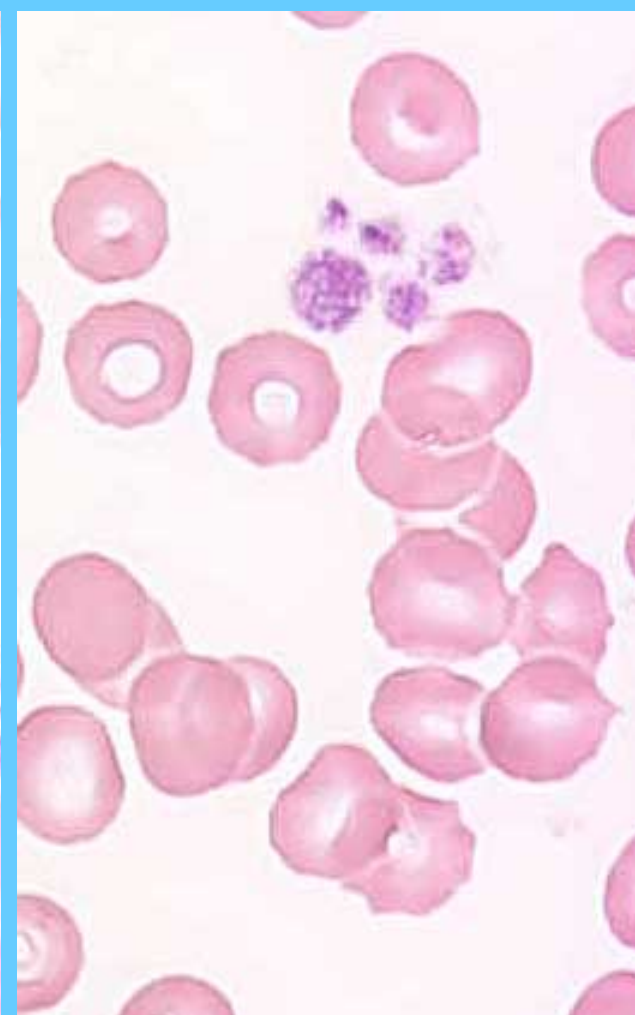
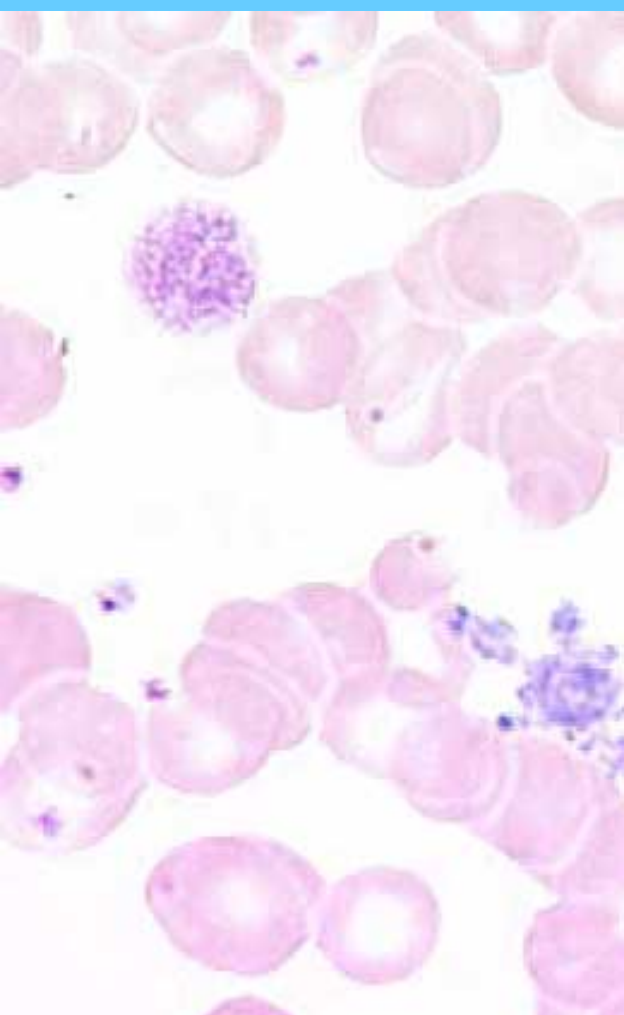


PLAQUETAS PEQUEÑAS (I), PLAQUETAS GRANDES

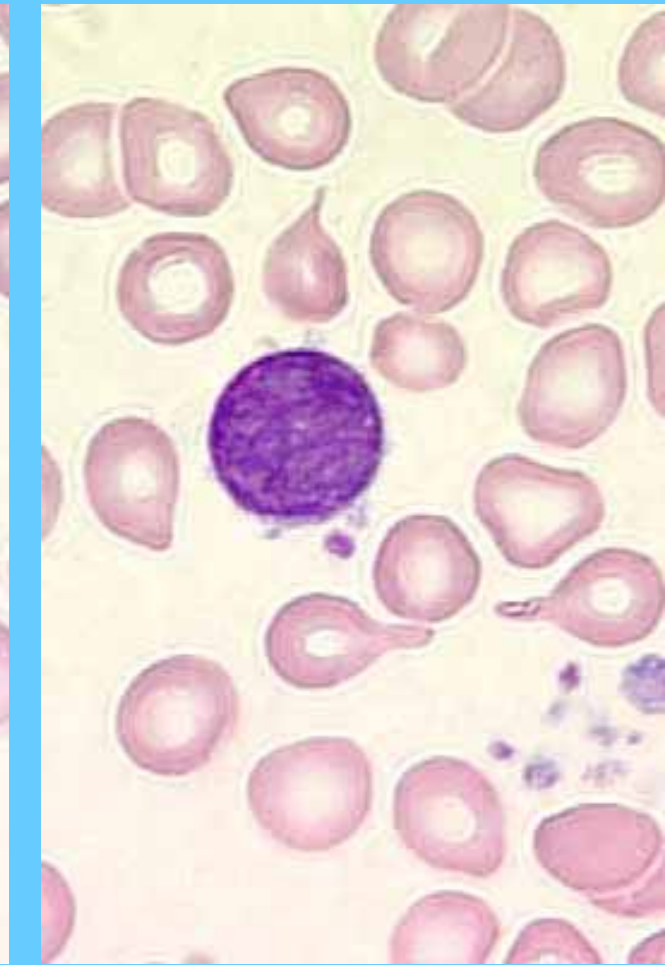
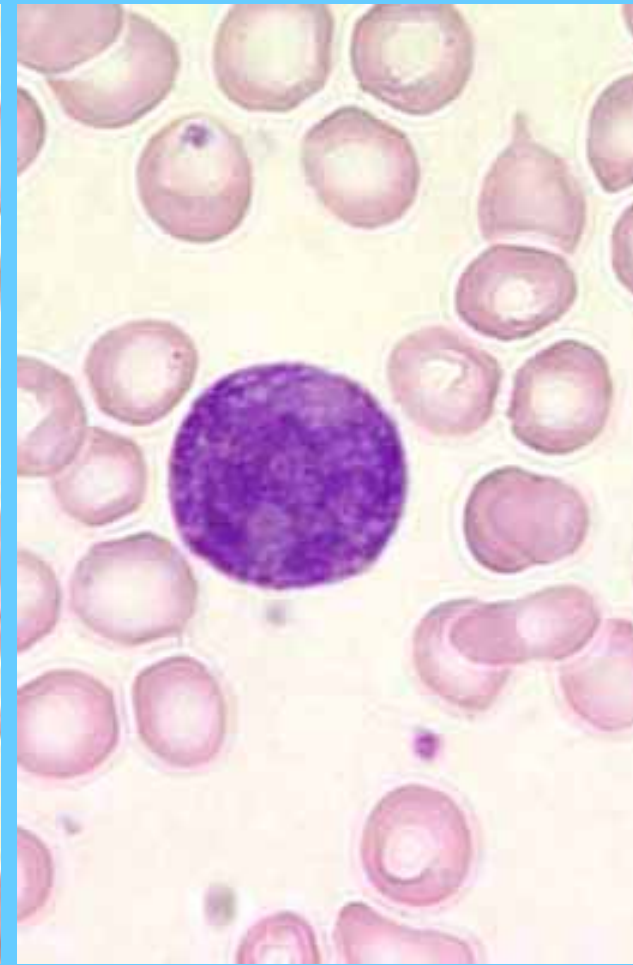
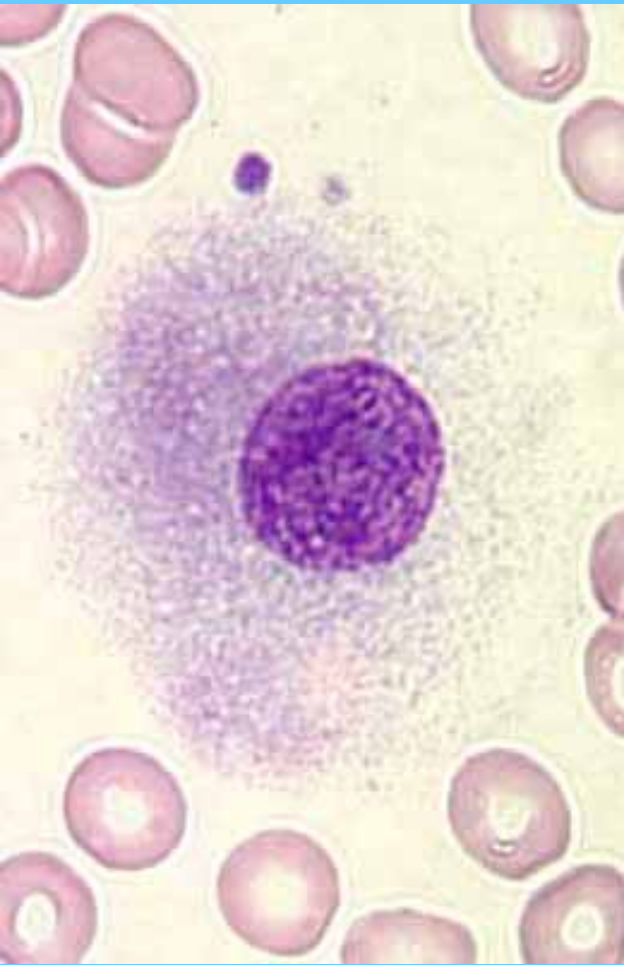


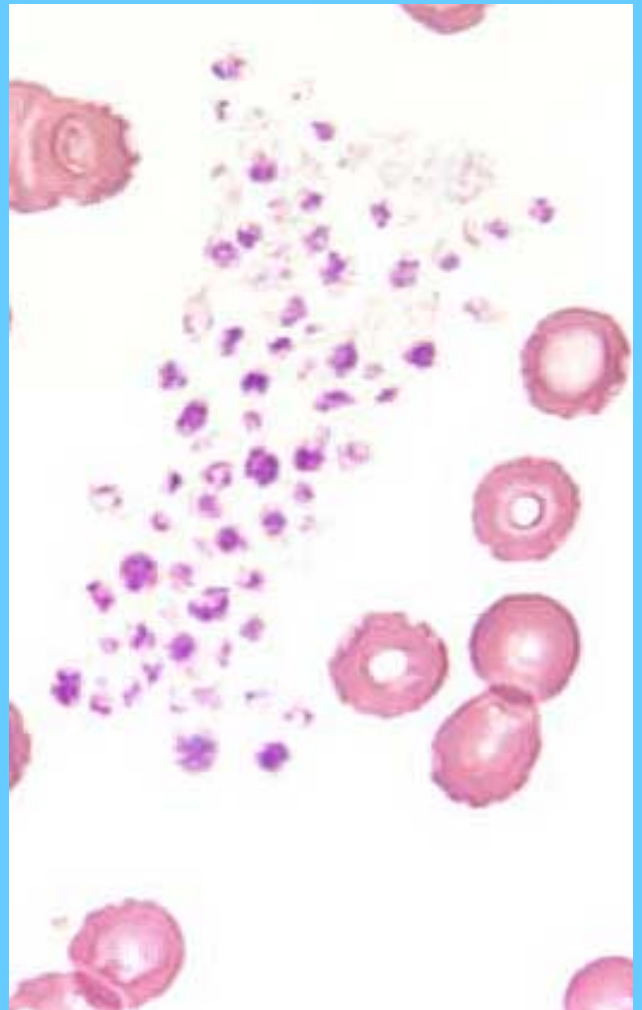
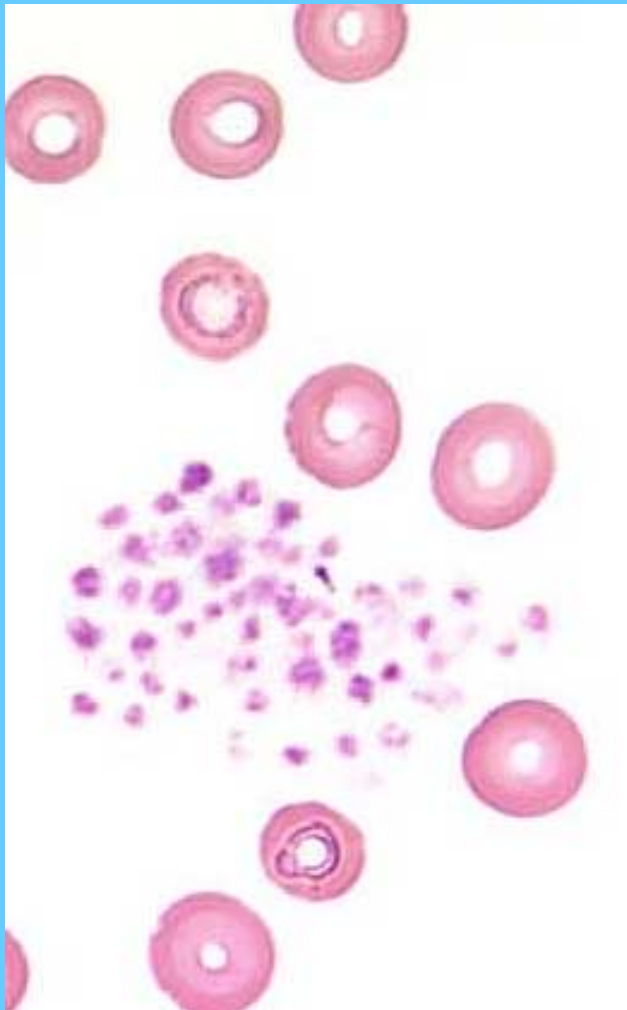
PLAQUETAS GIGANTES





NUCLEOS DESNUDOS DE MEGACARIOCITOS

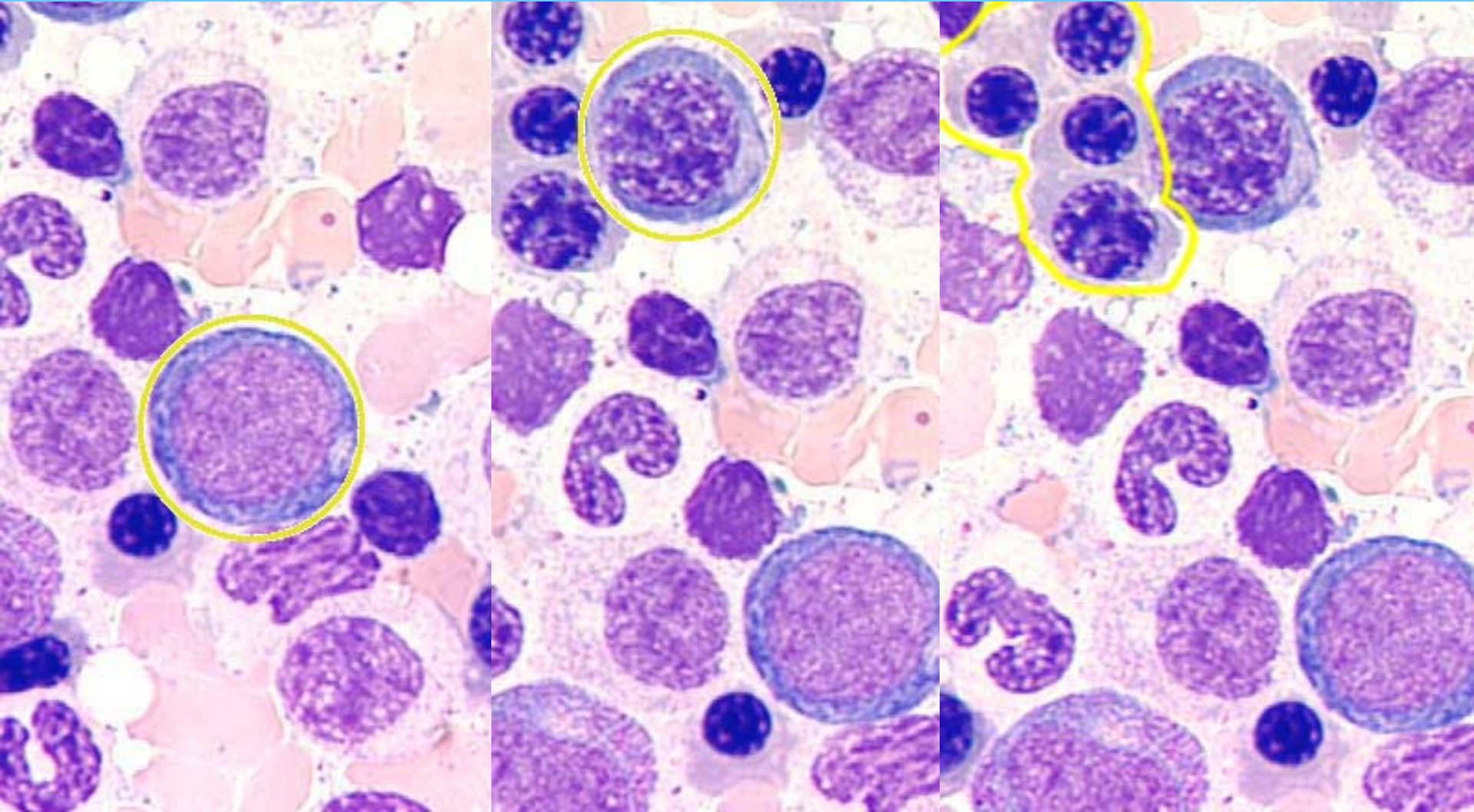




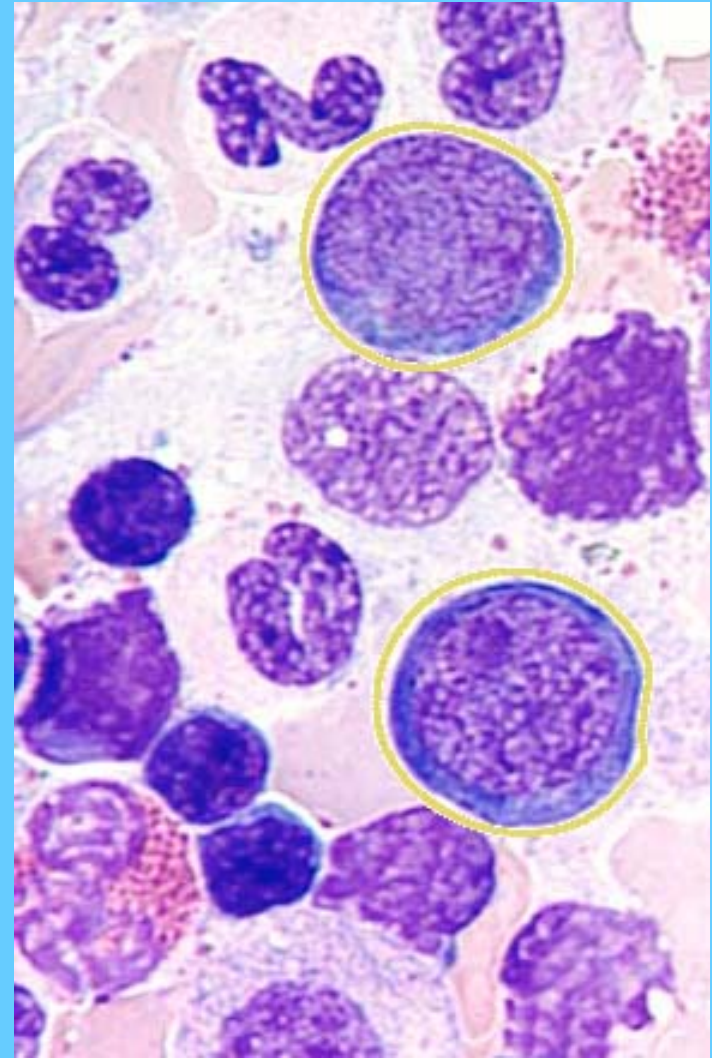
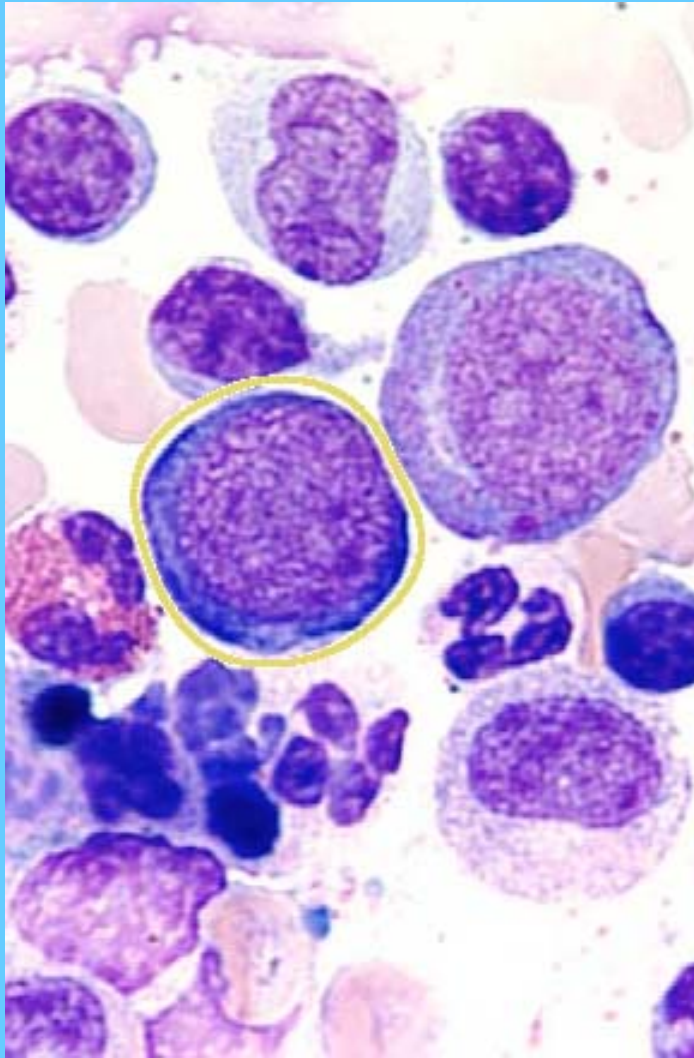
PROERITROBLASTO

ERITROBLASTO
BASÓFILO

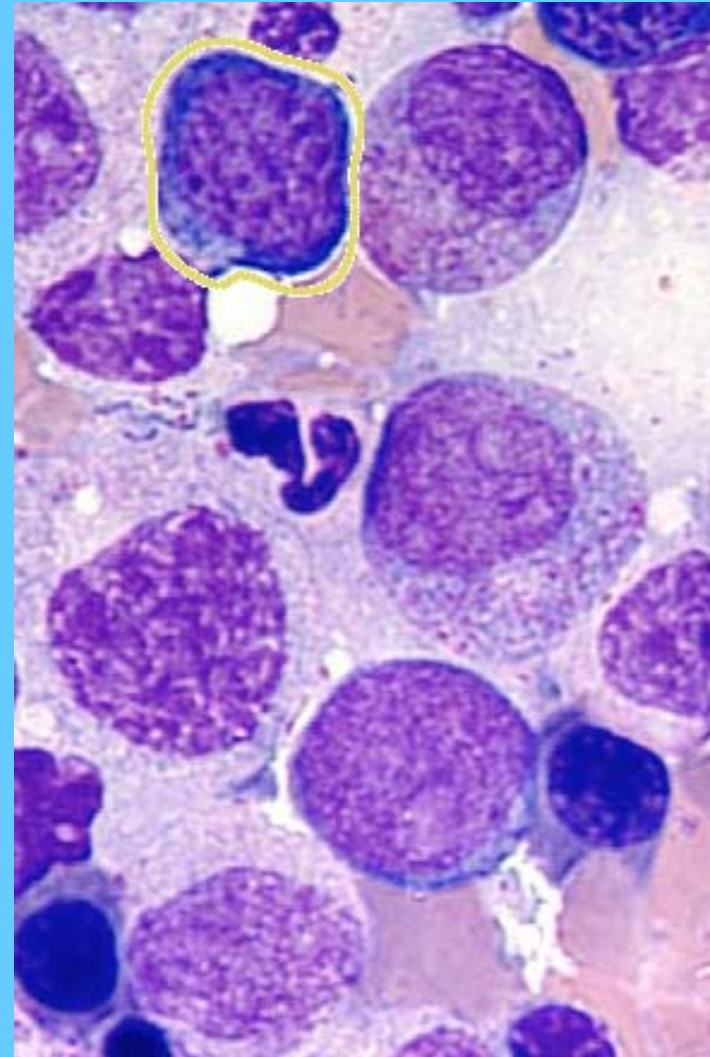
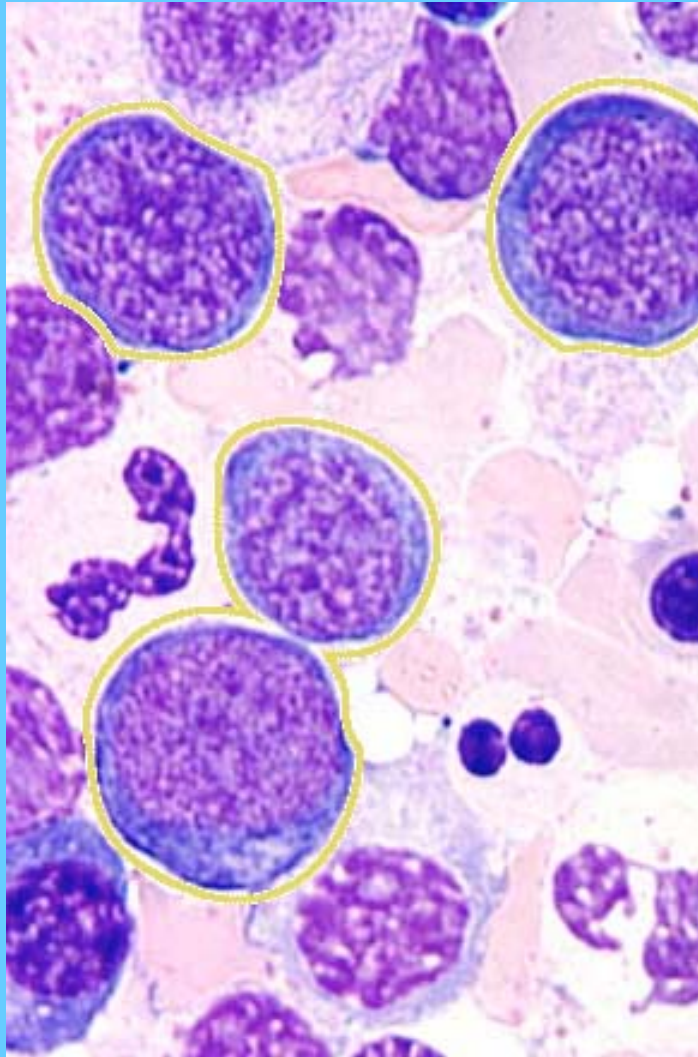
ERITROBLASTO
POLICROMATÓFILO



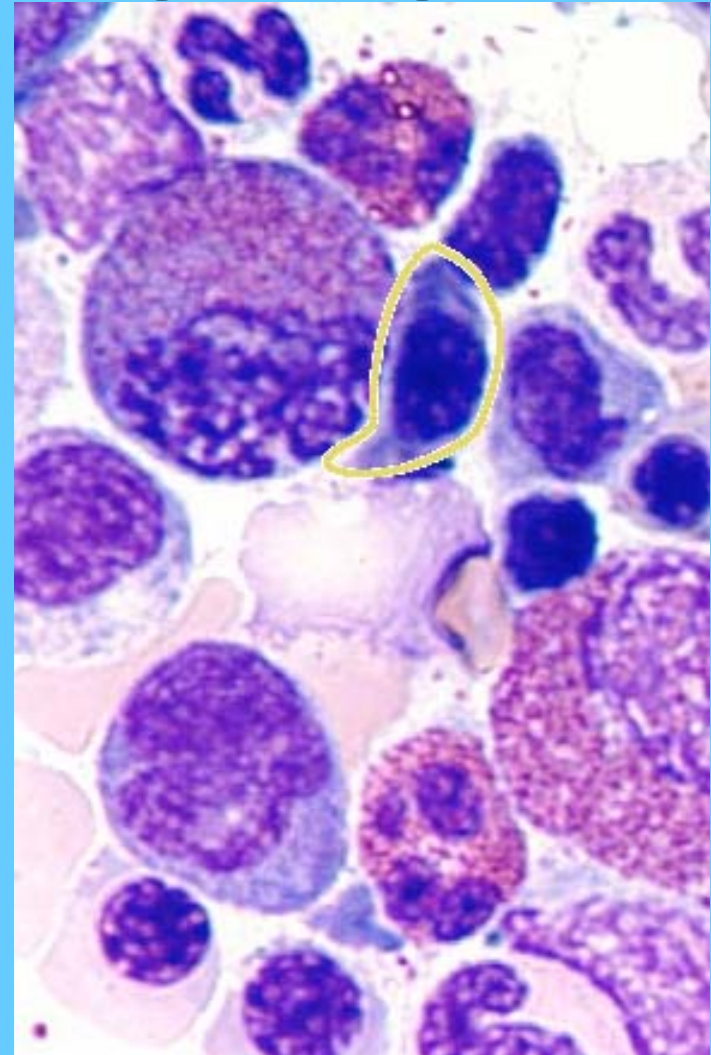
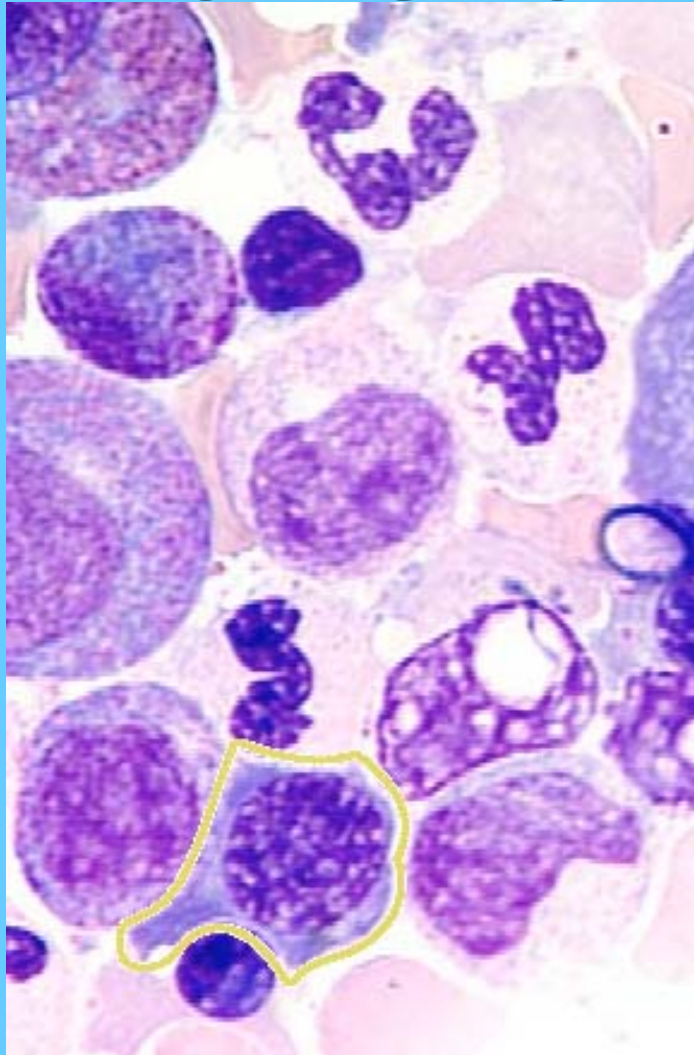
PROERITROBLASTOS



ERITROBLASTOS BASÓFILOS

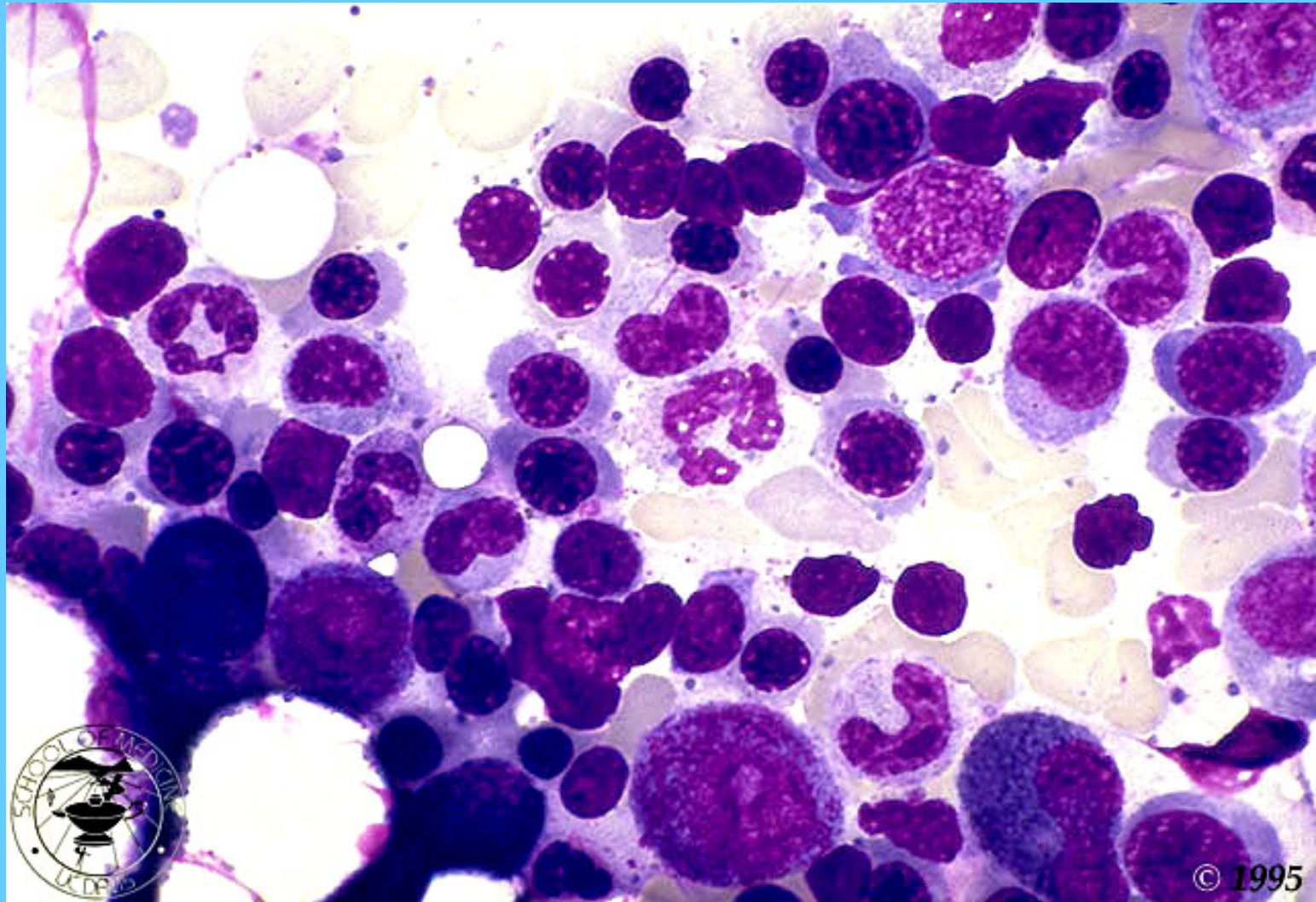


ERITROBLASTO POLICROMATÓFILO

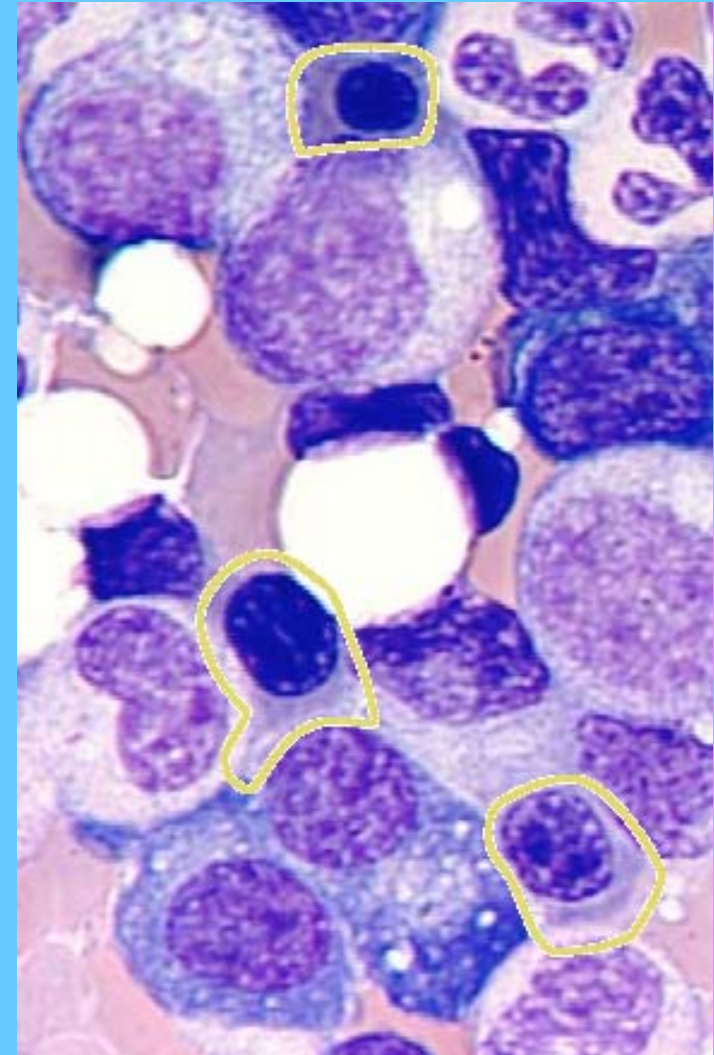
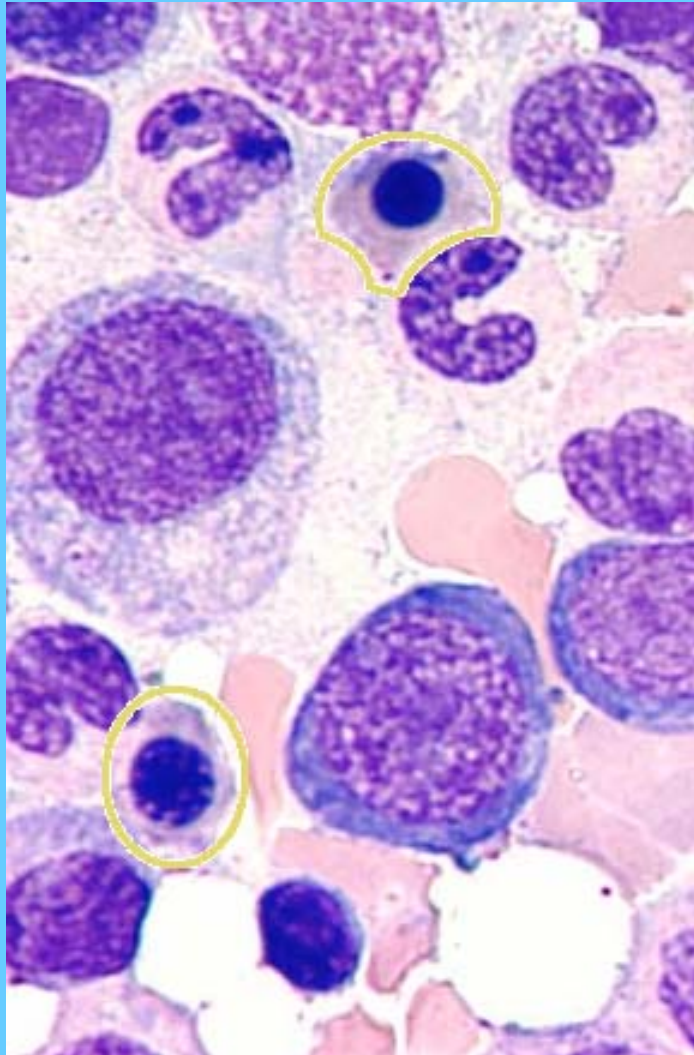


HIPERPLASIA ERITROIDE

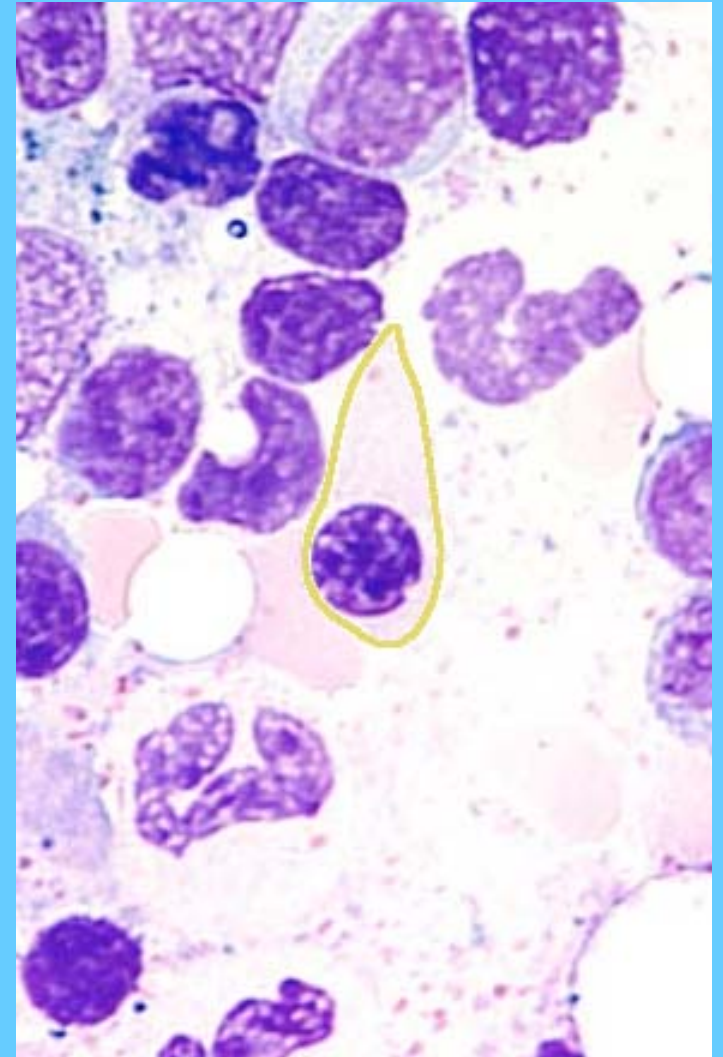
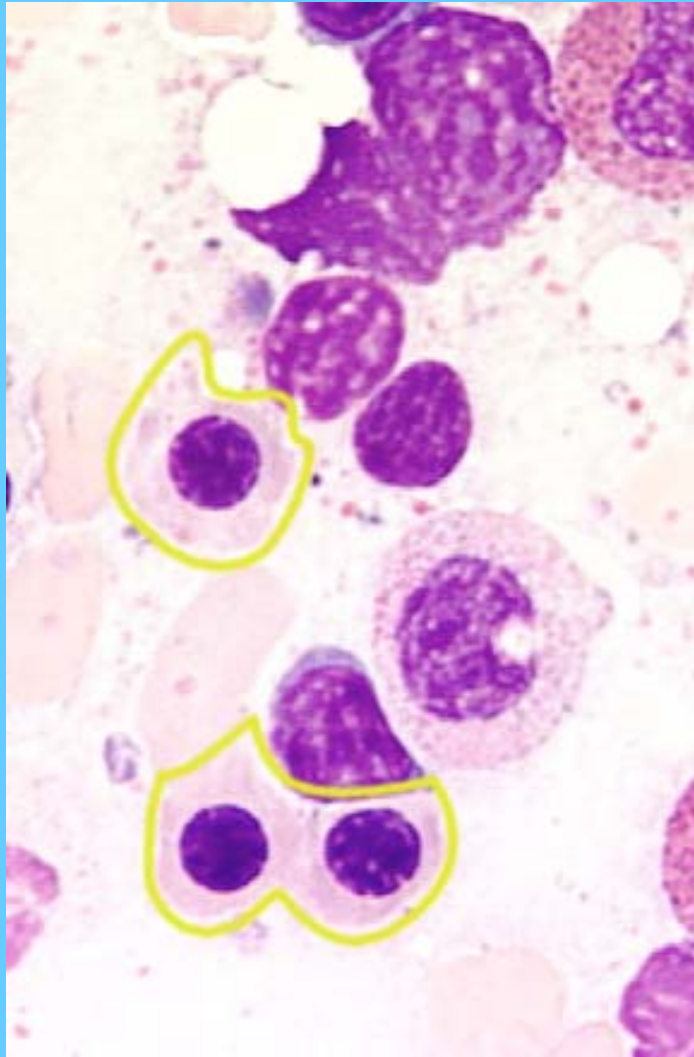
M.O.



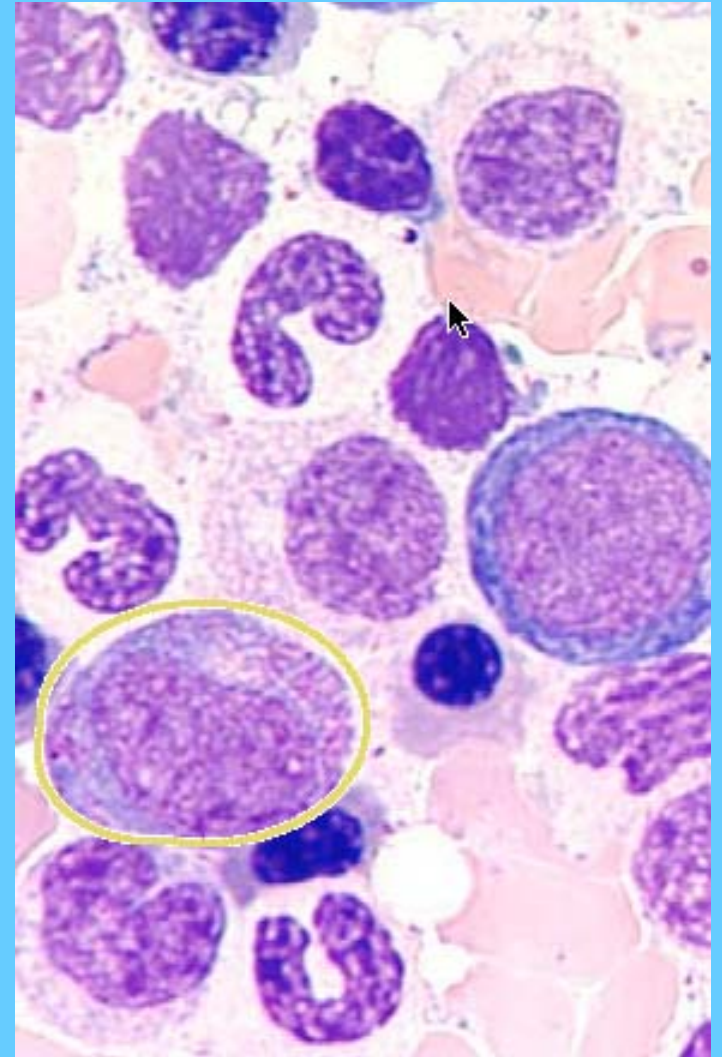
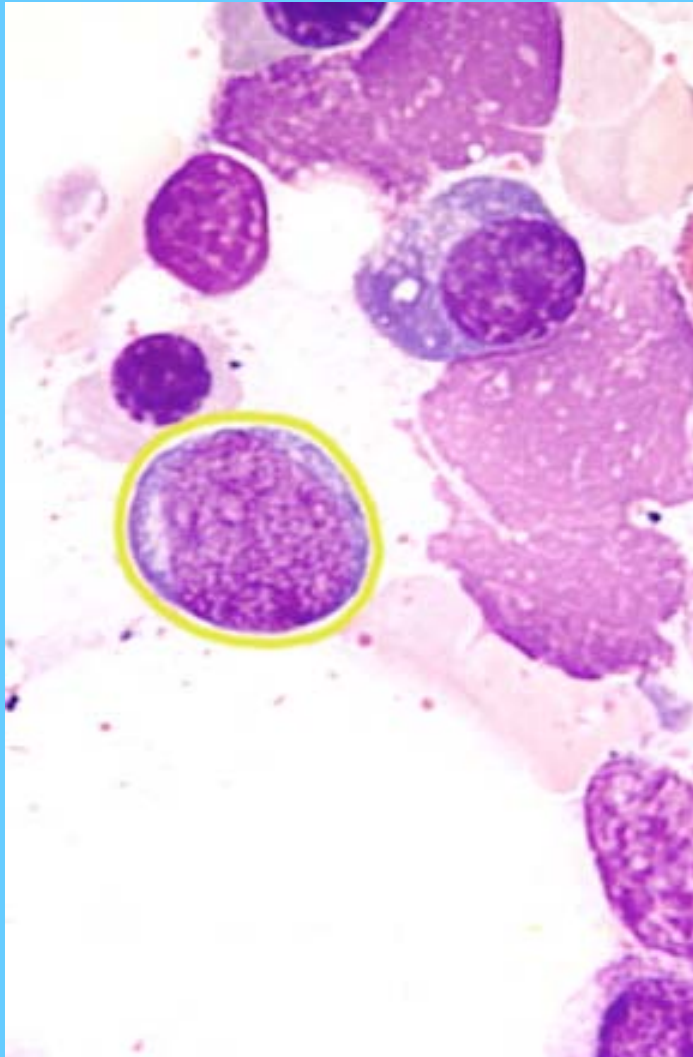
ERITROBLASTOS POLICROMATÓFILOS



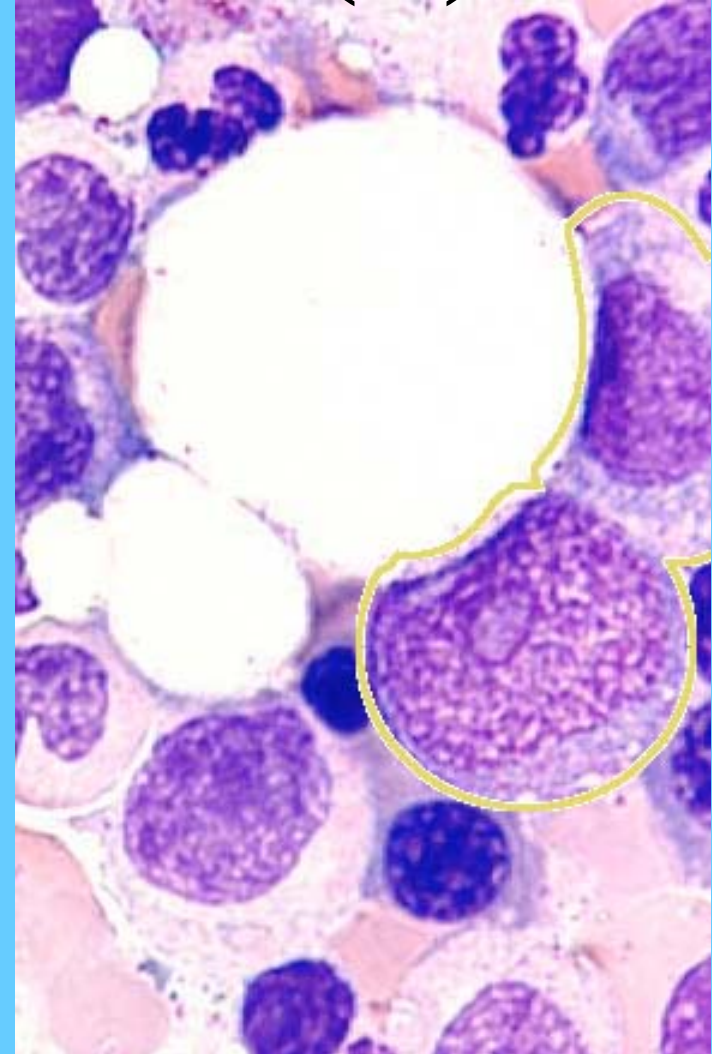
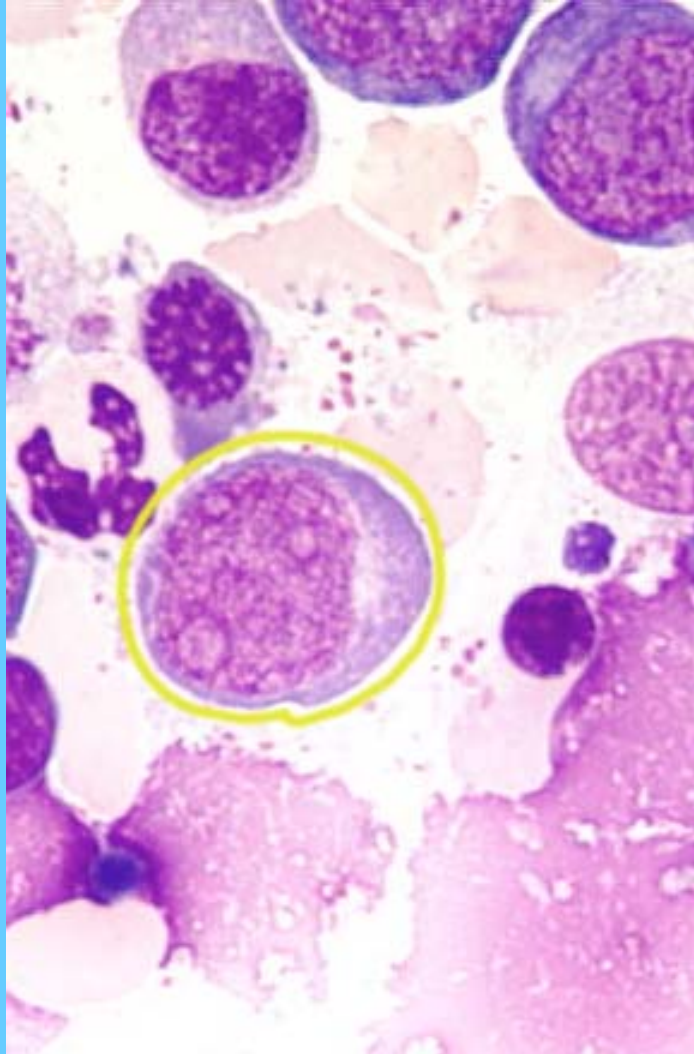
ERITROBLASTOS ORTOCROMÁTICOS

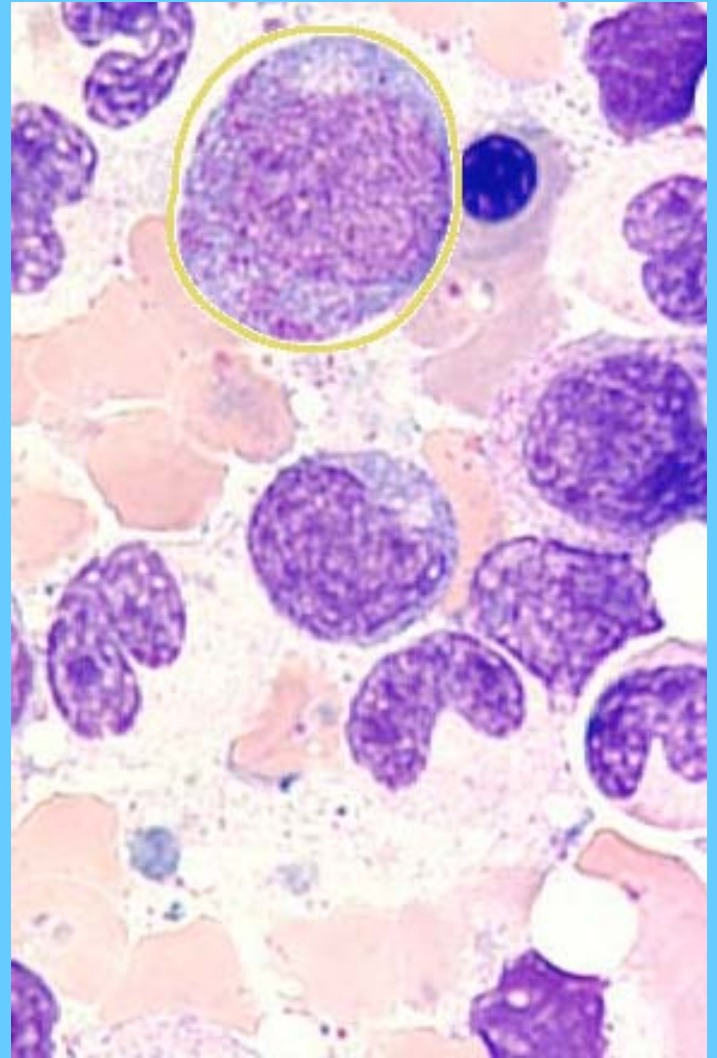
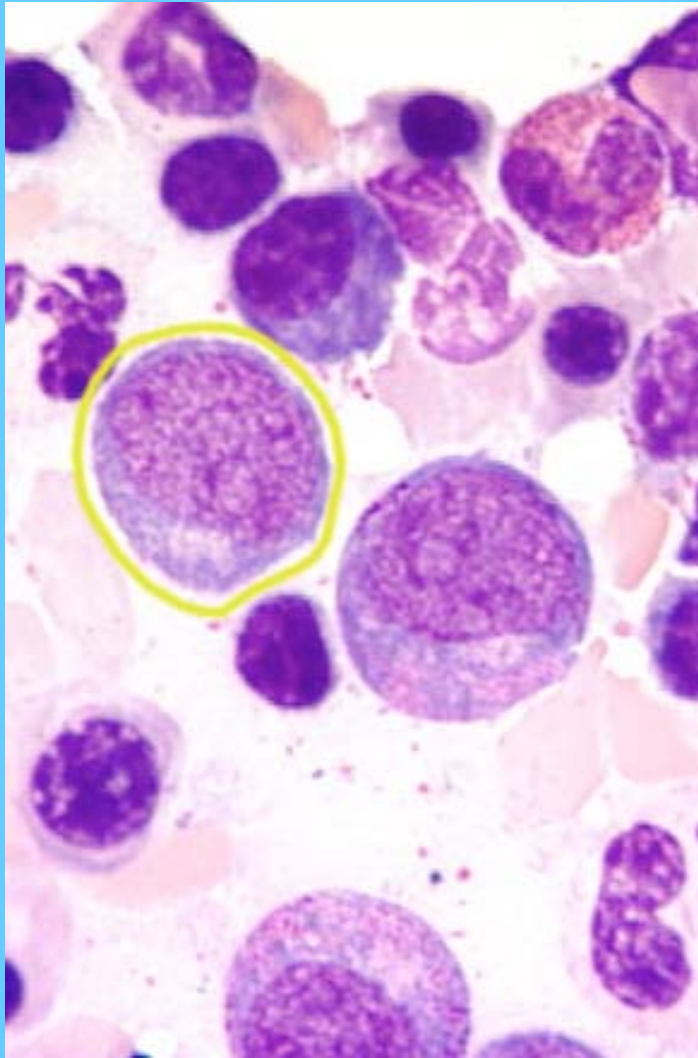


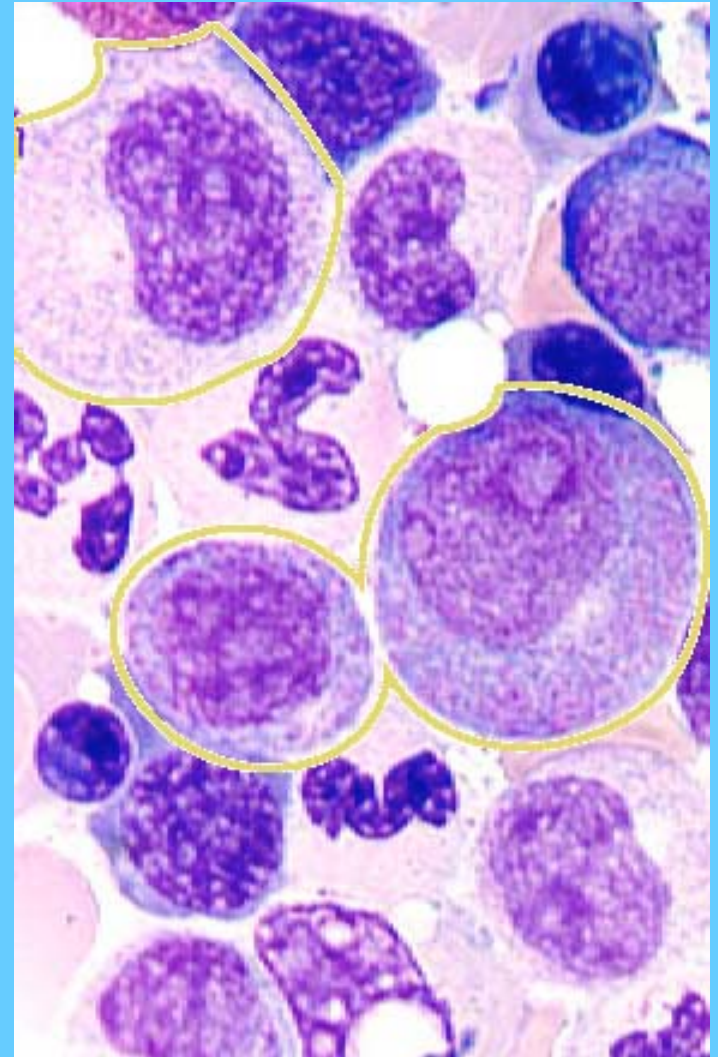
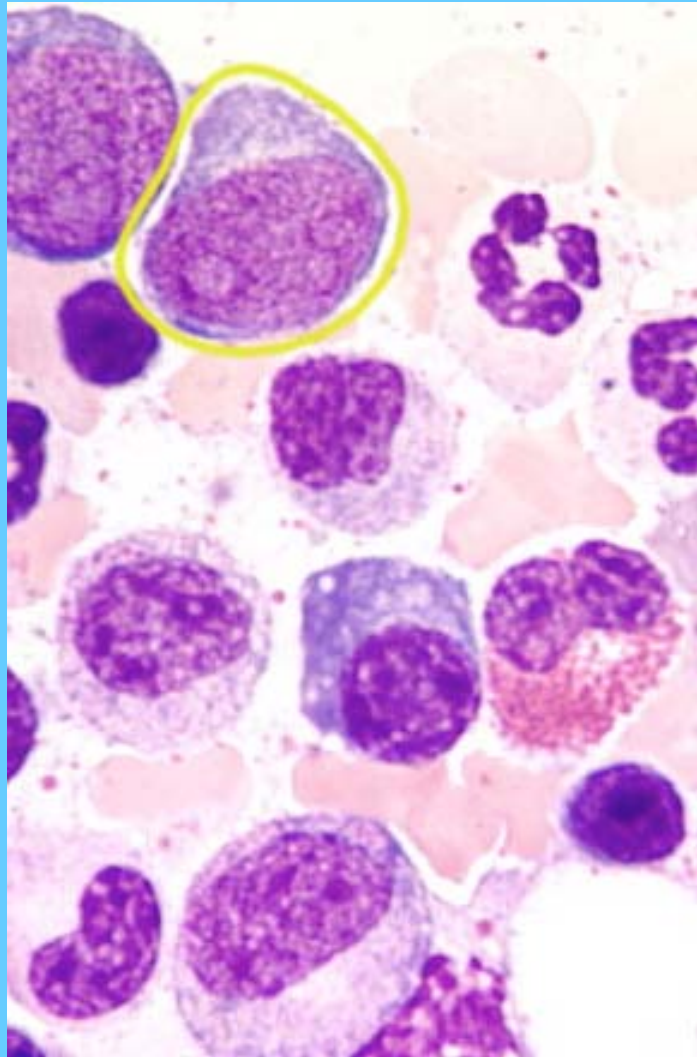
MIELOBLASTO (I) PROMIELOCITO (D)

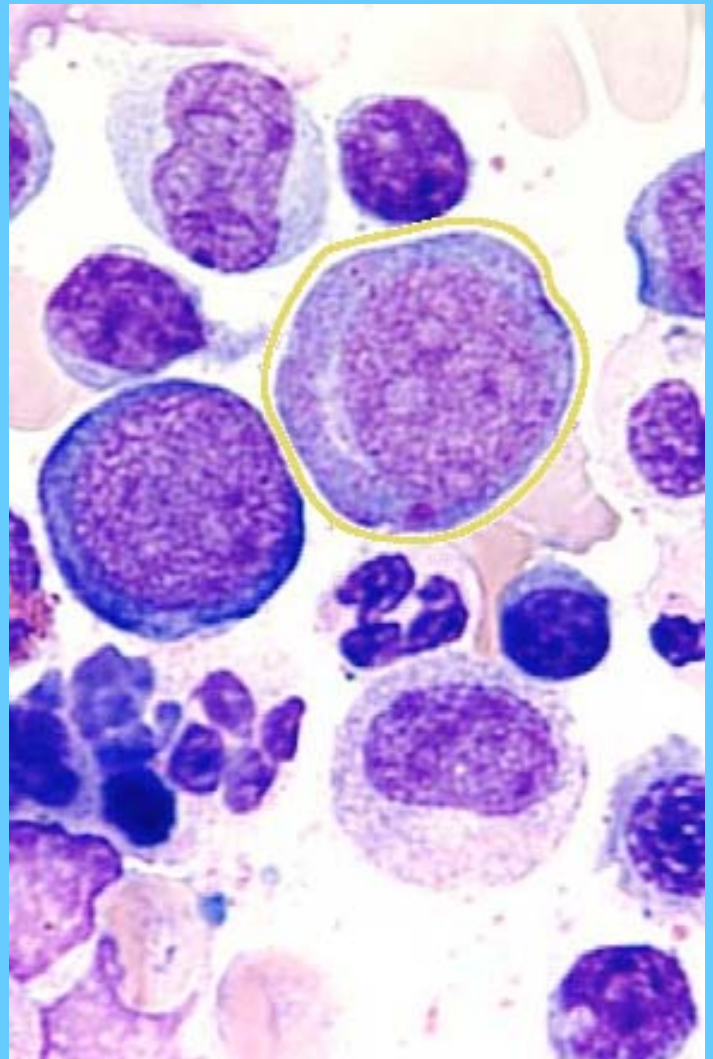
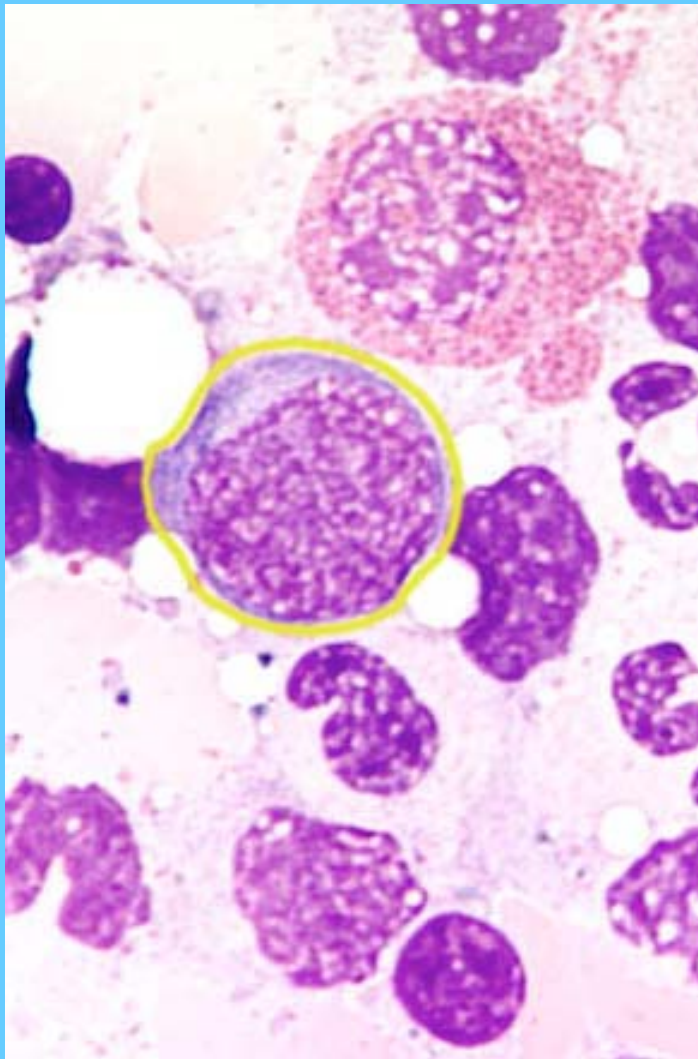


MIELOBLASTO (I) PROMIELOCITO (D)

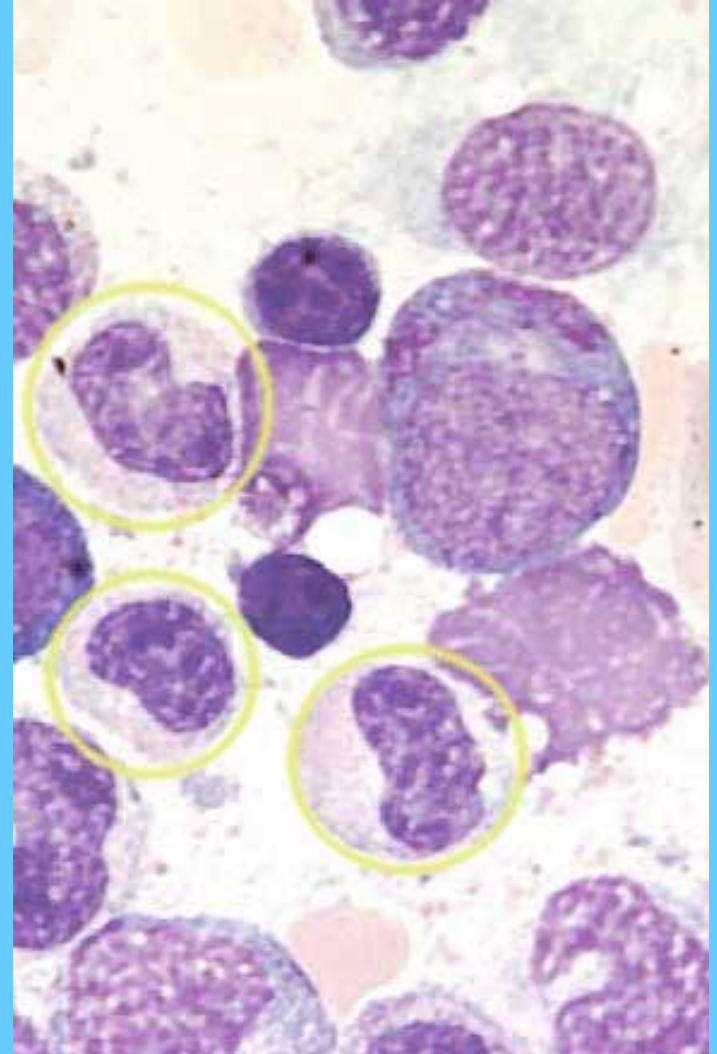
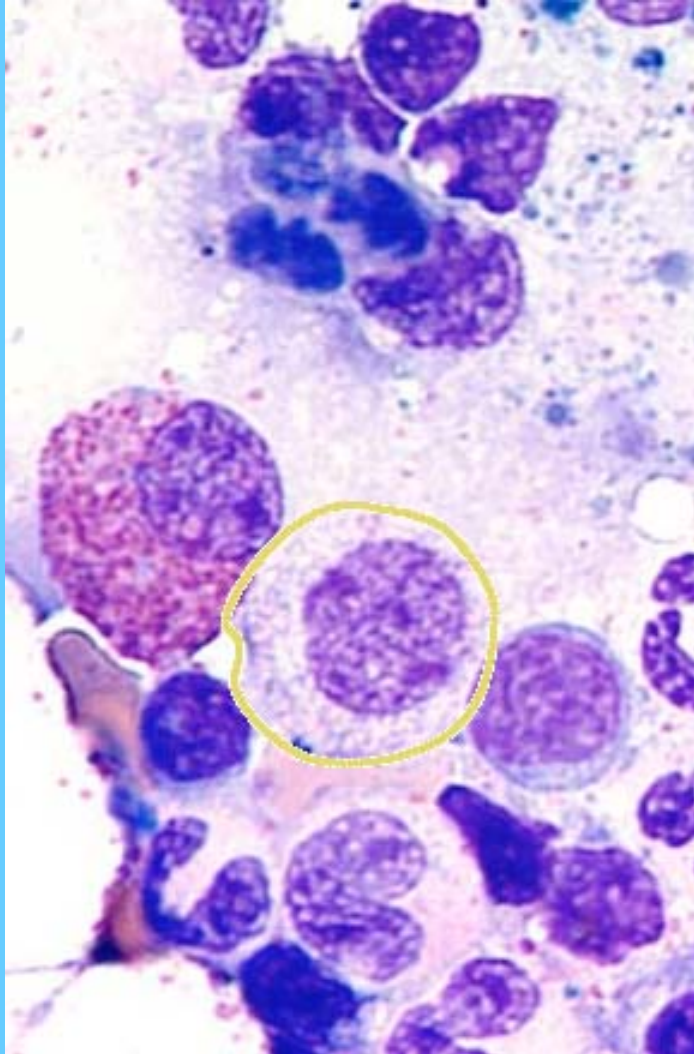


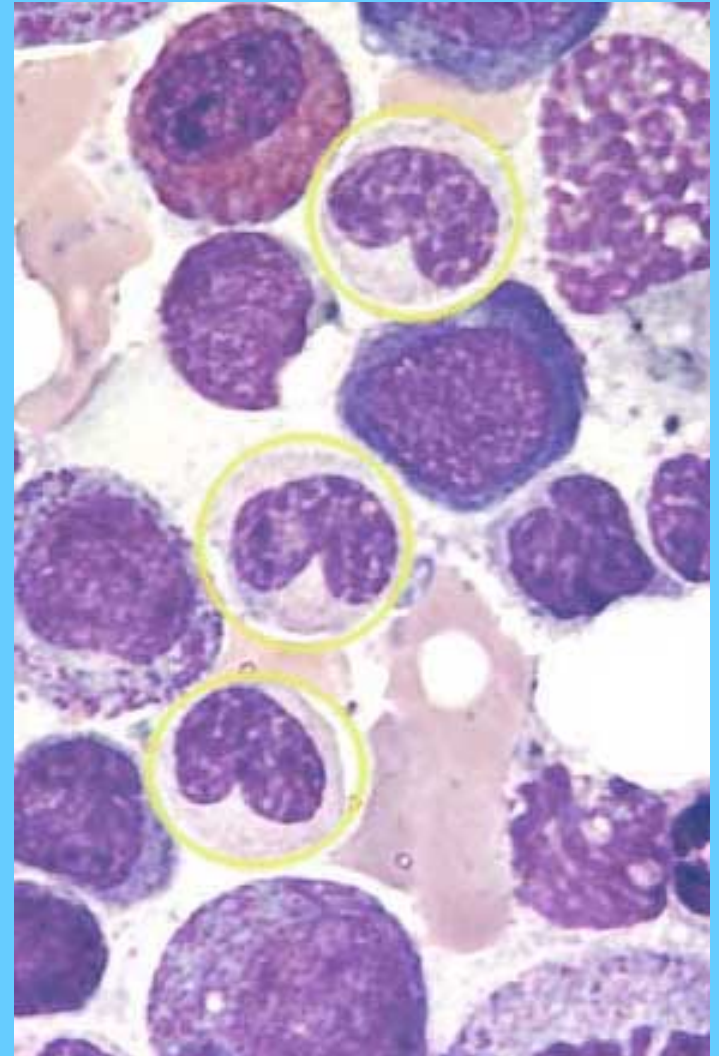
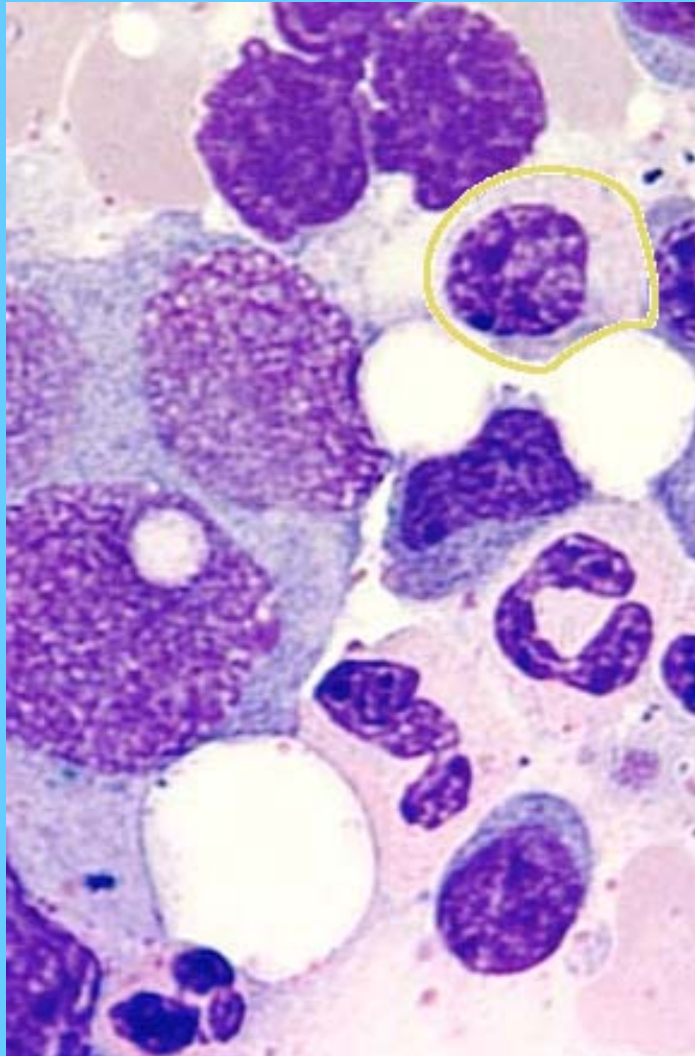


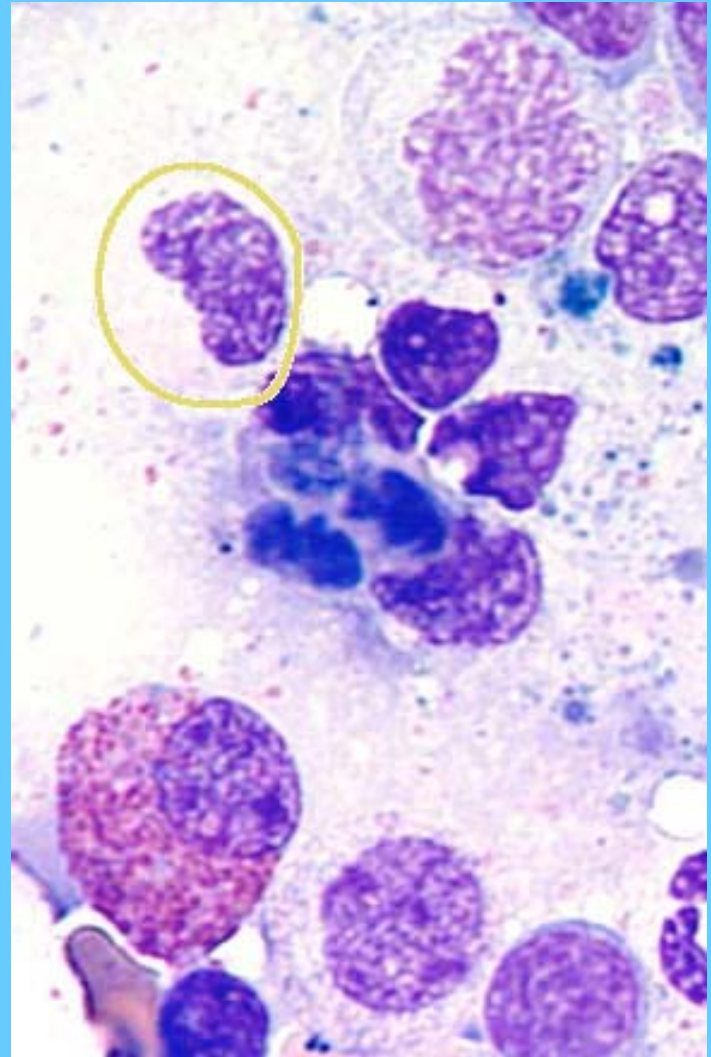
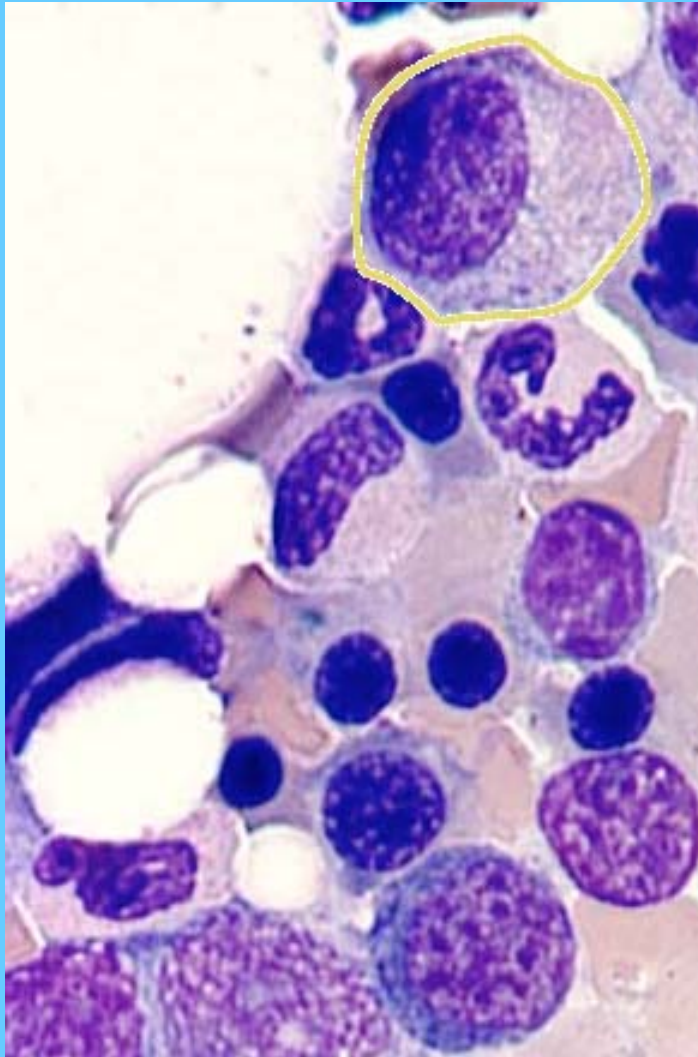


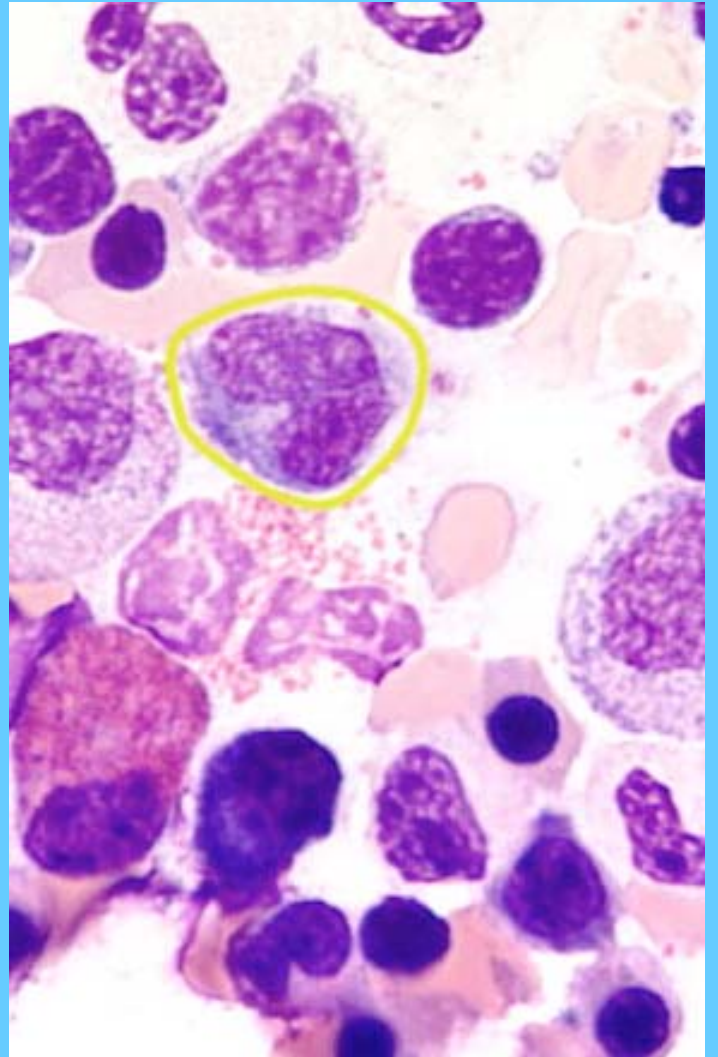
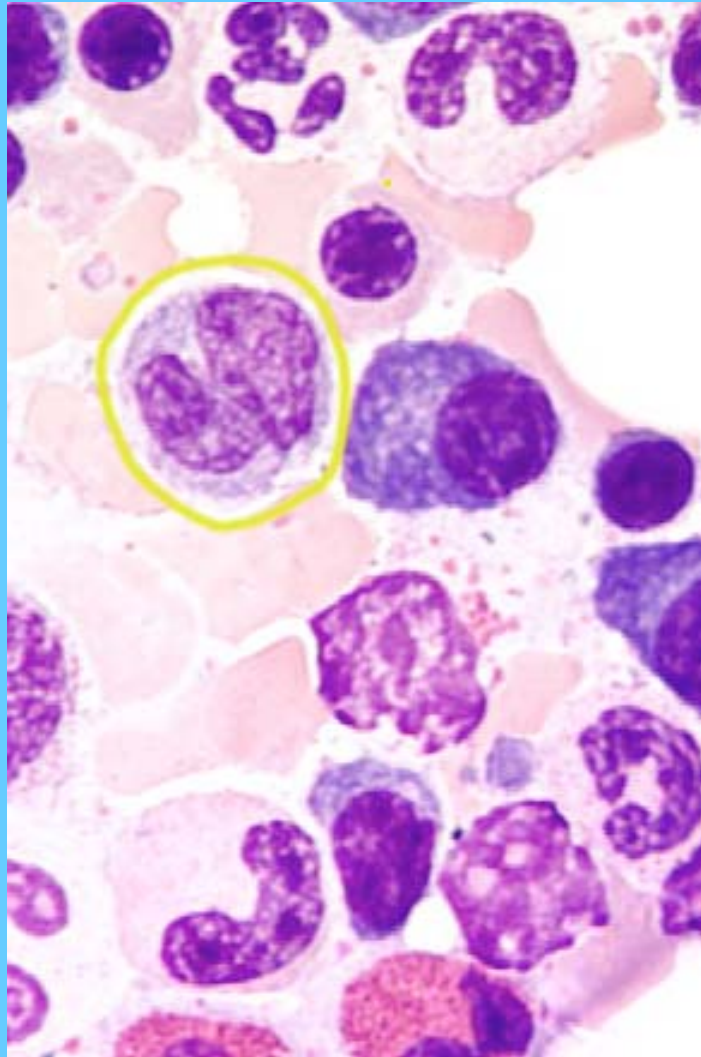


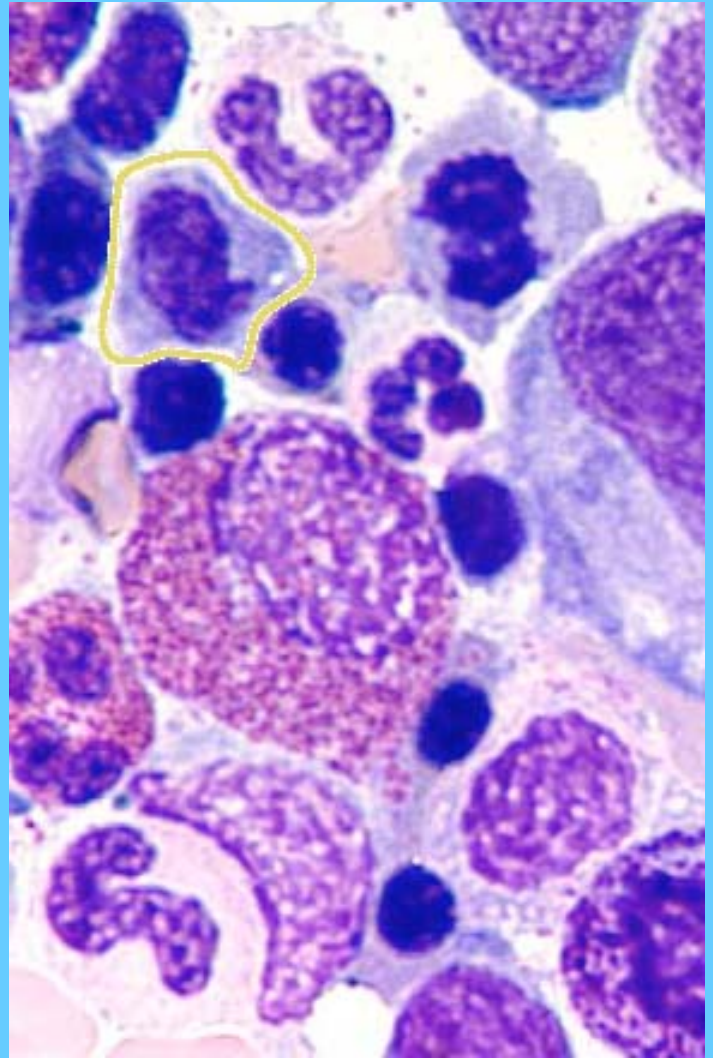
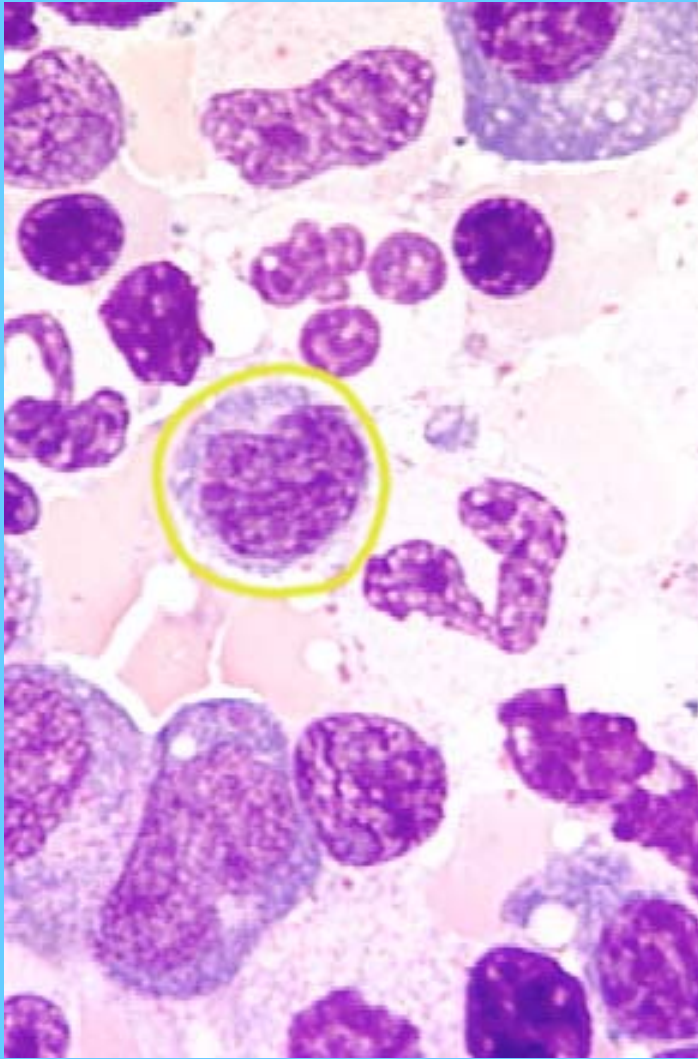
MIELOCITO Y METAMIELOCITOS



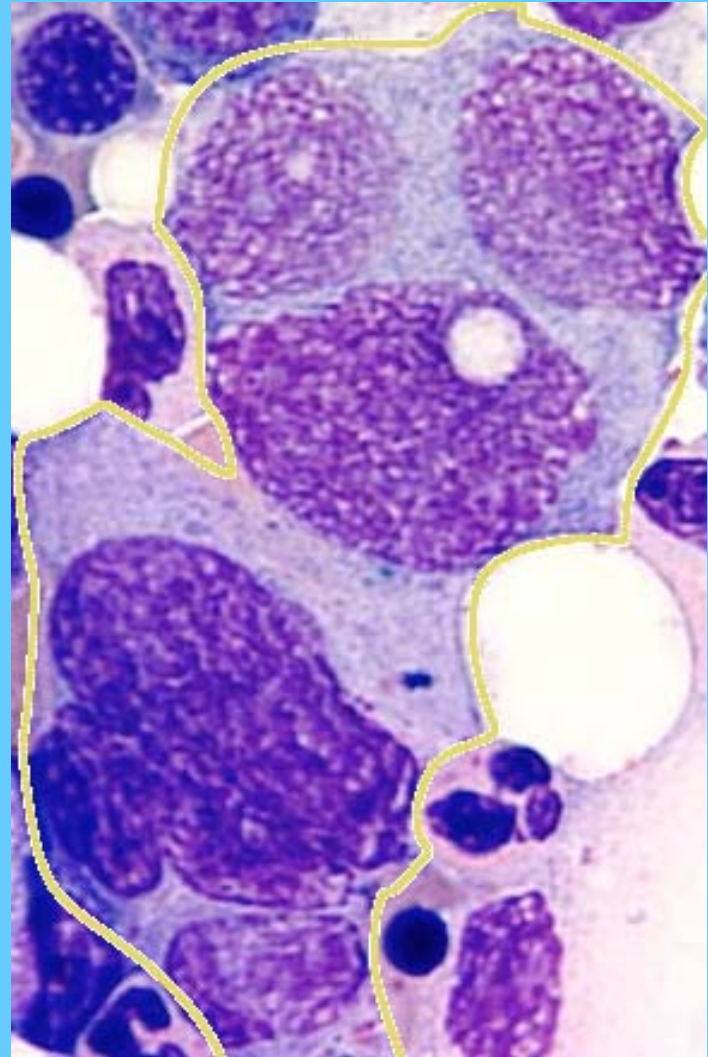
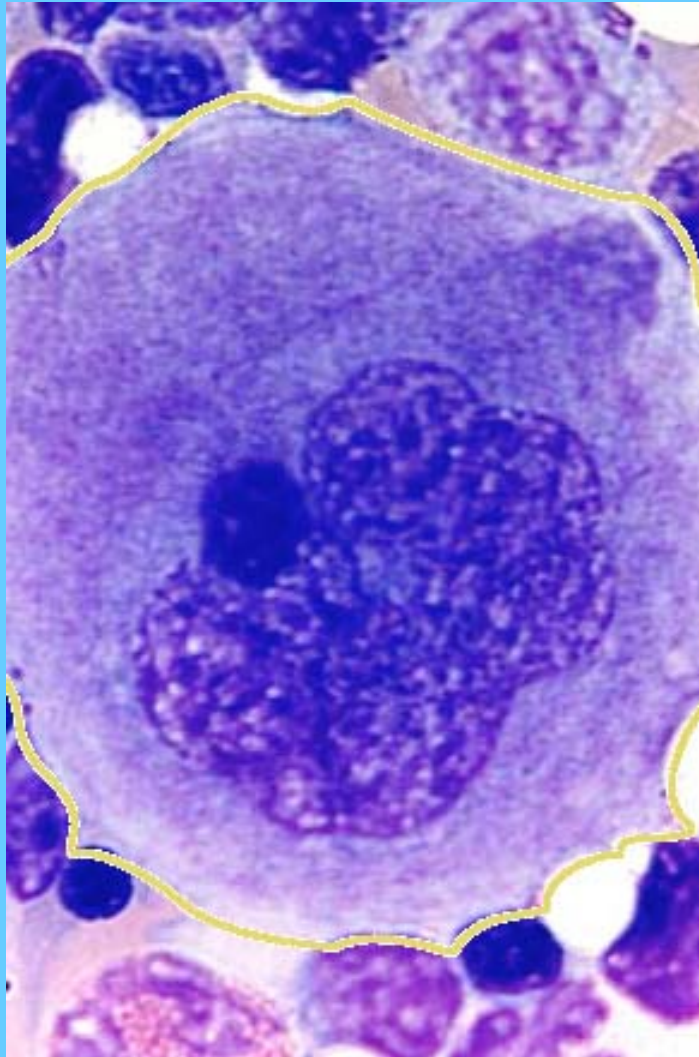


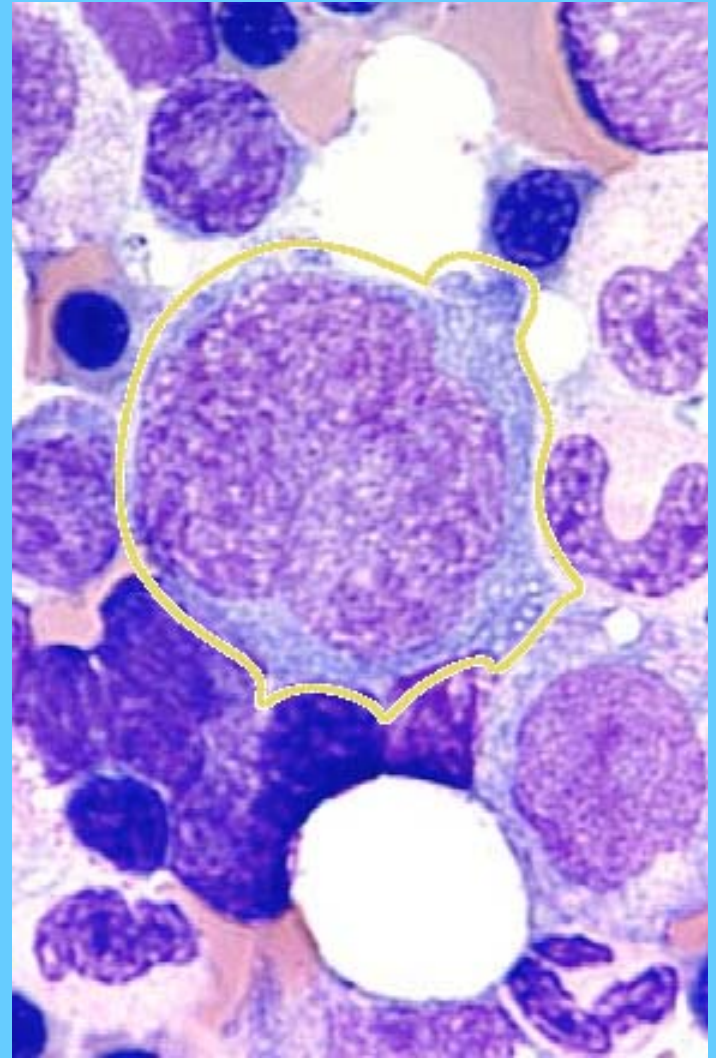
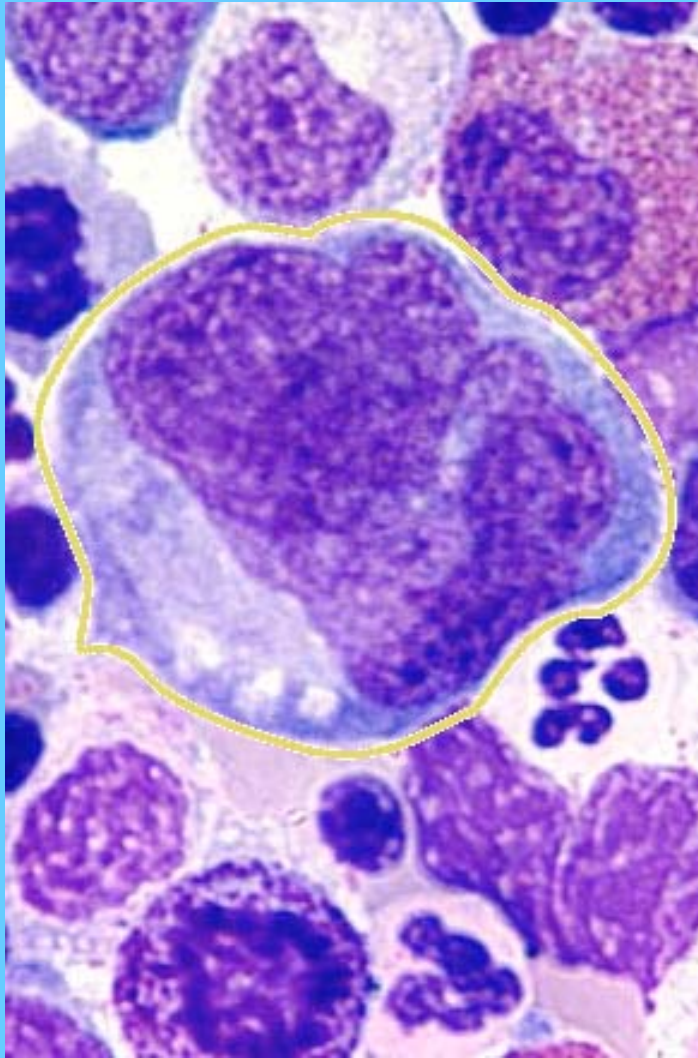




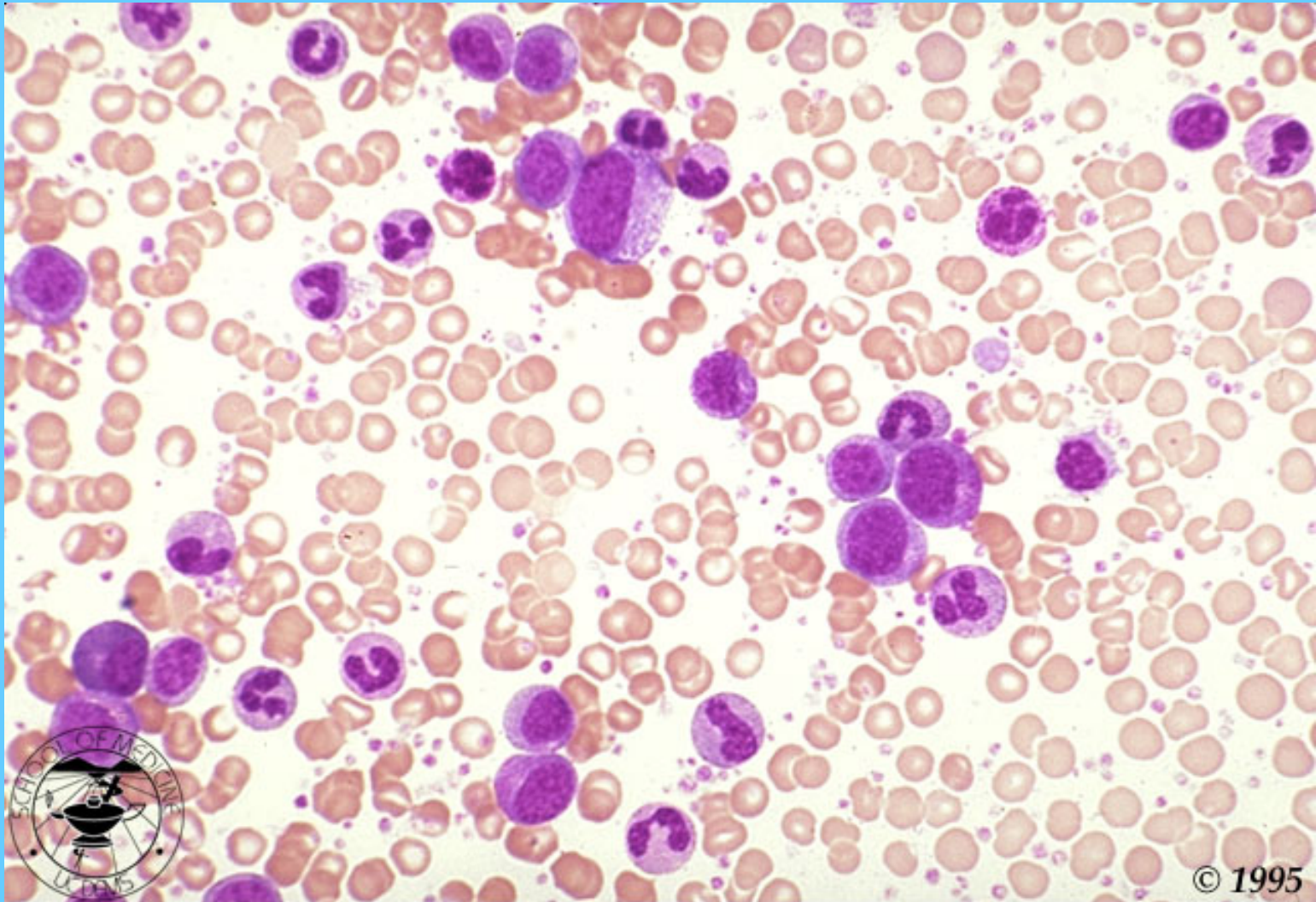


MEGACARIOCITOS

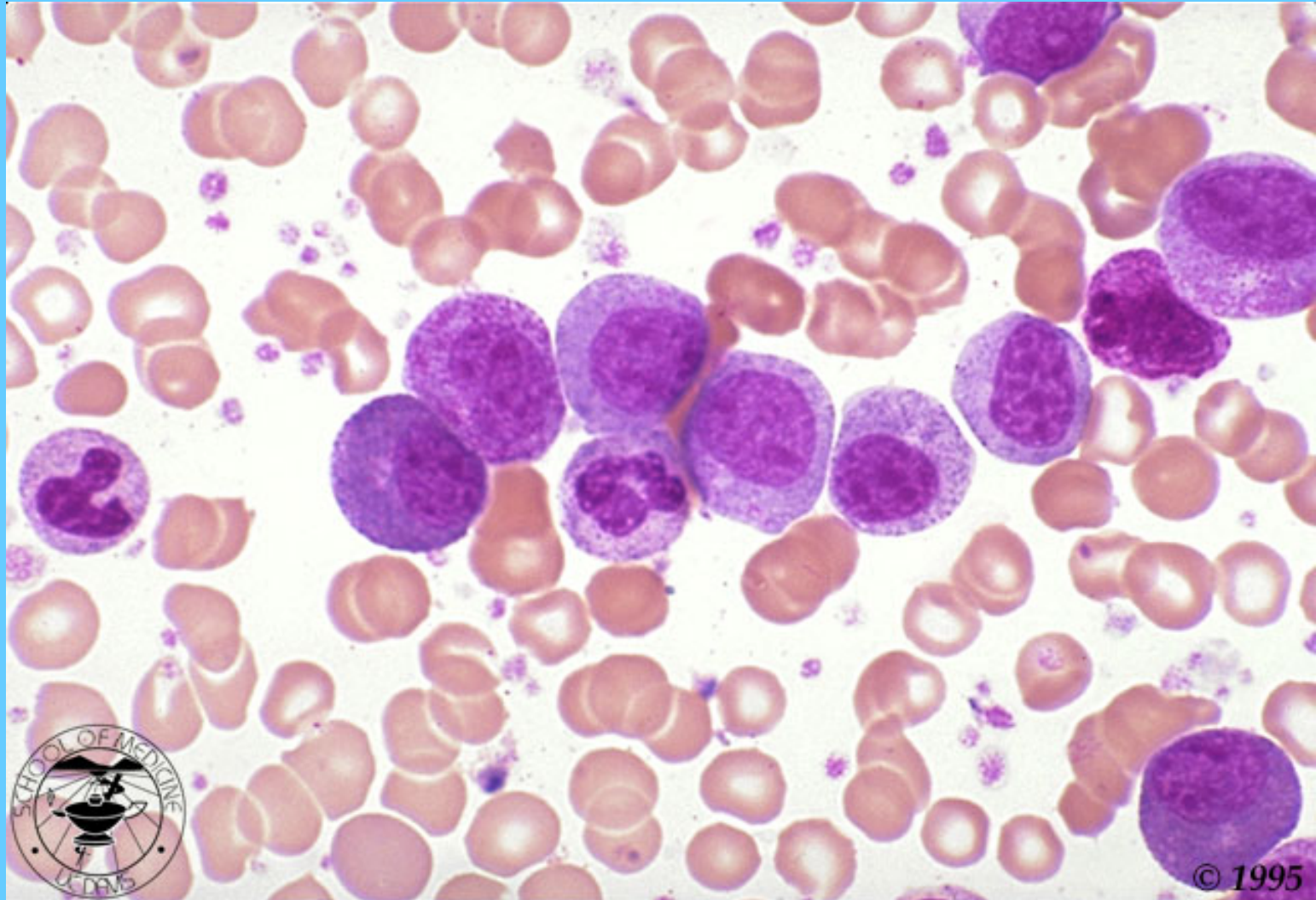




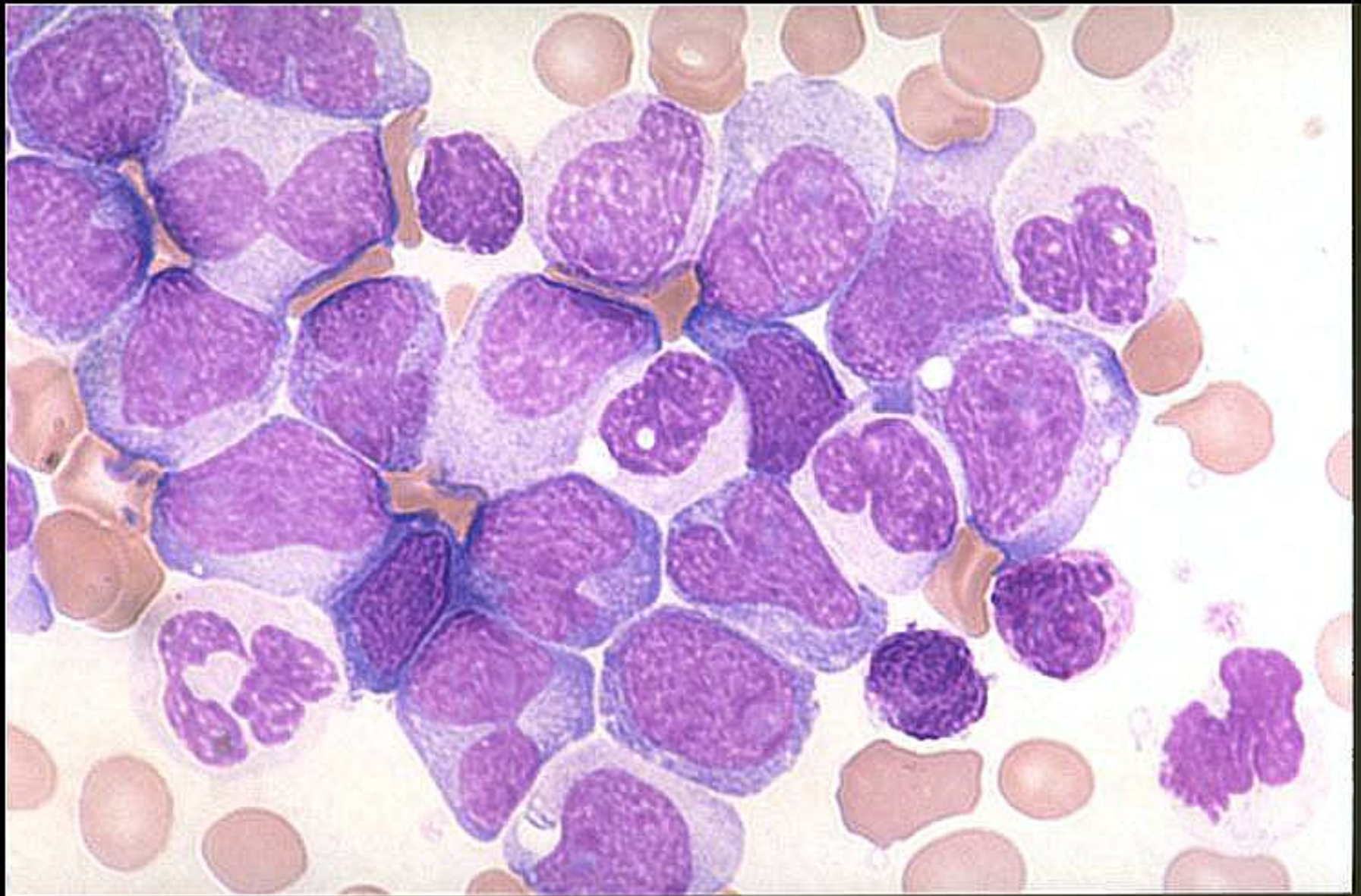
LEUCEMIA GRANULOCÍTICA CRÓNICA



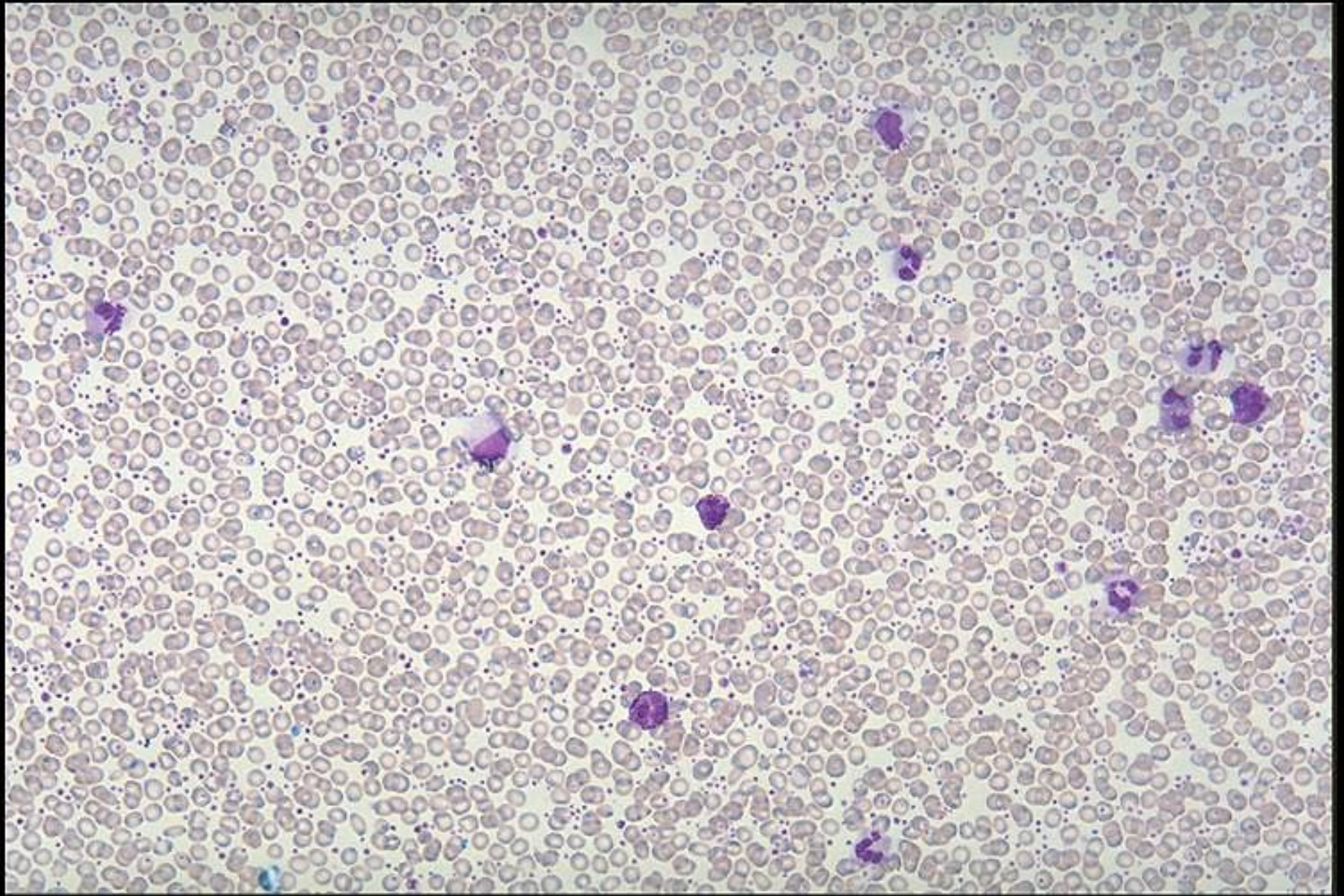
LEUCEMIA GRANULOCÍTICA CRÓNICA



LGC

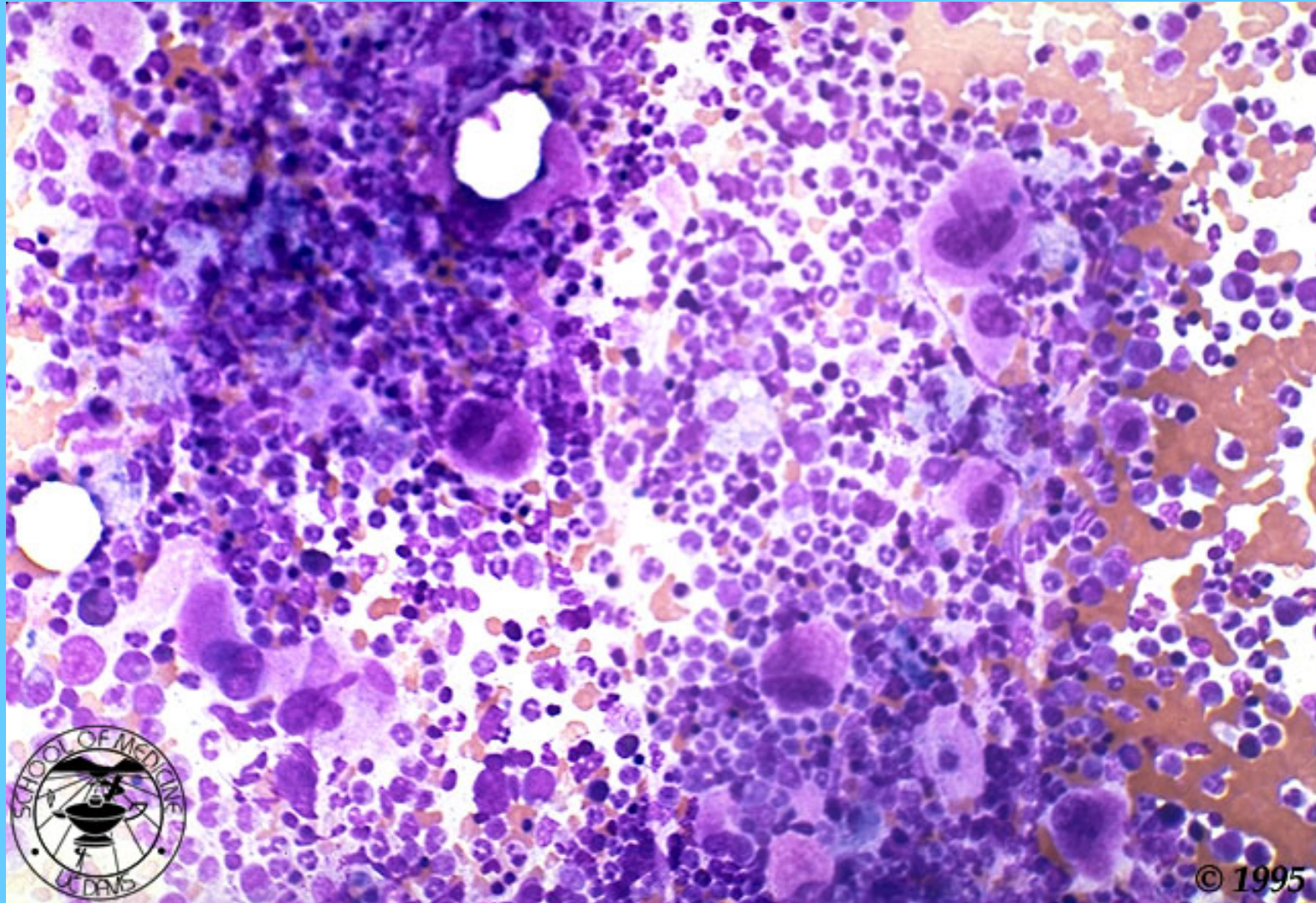


LGC, TROMBOCITOSIS



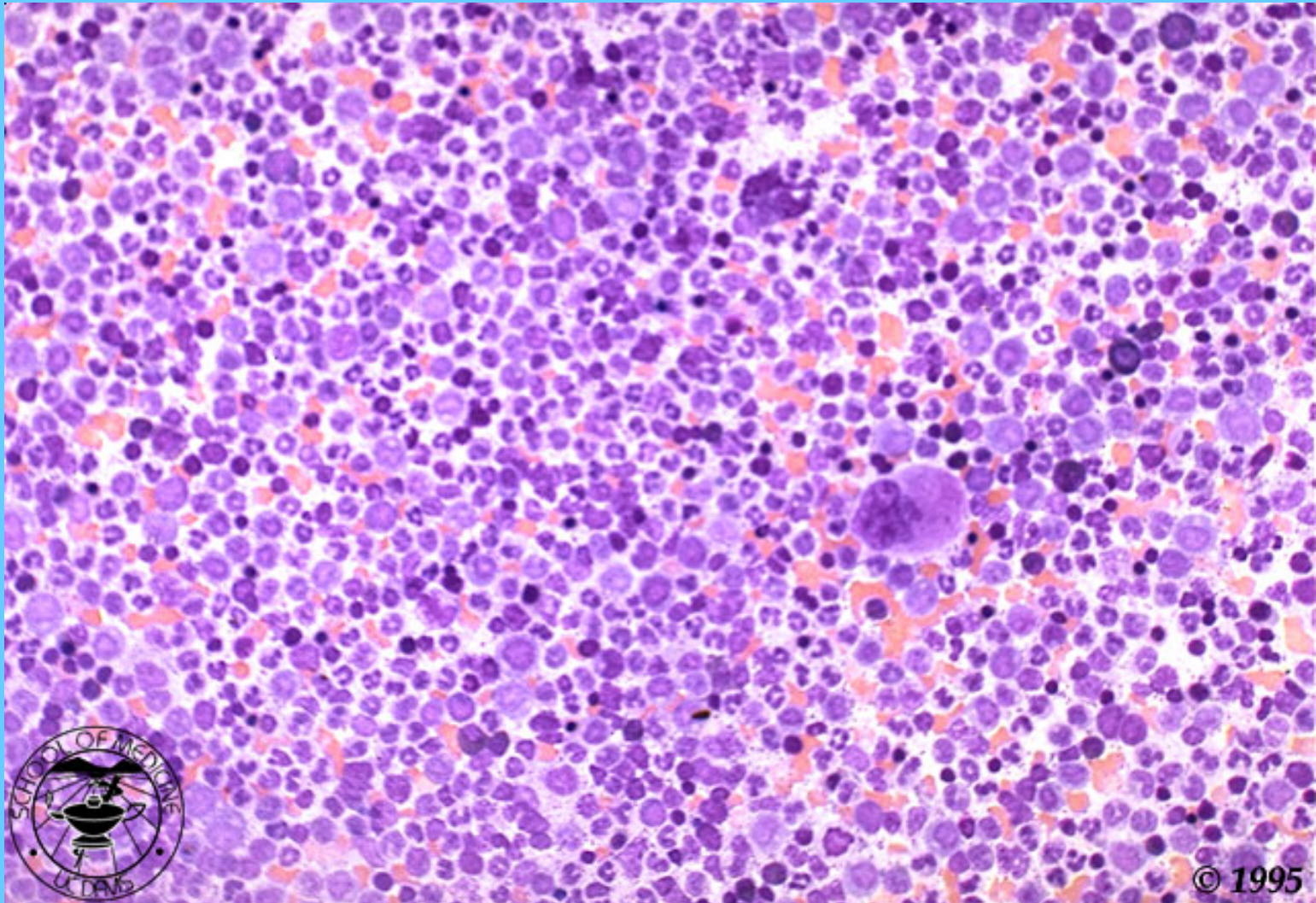
LGC ASPIRADO DE M.O.

HIPERCELULAR Y MARCADO AUMENTO DE MAGACARIOCITOS

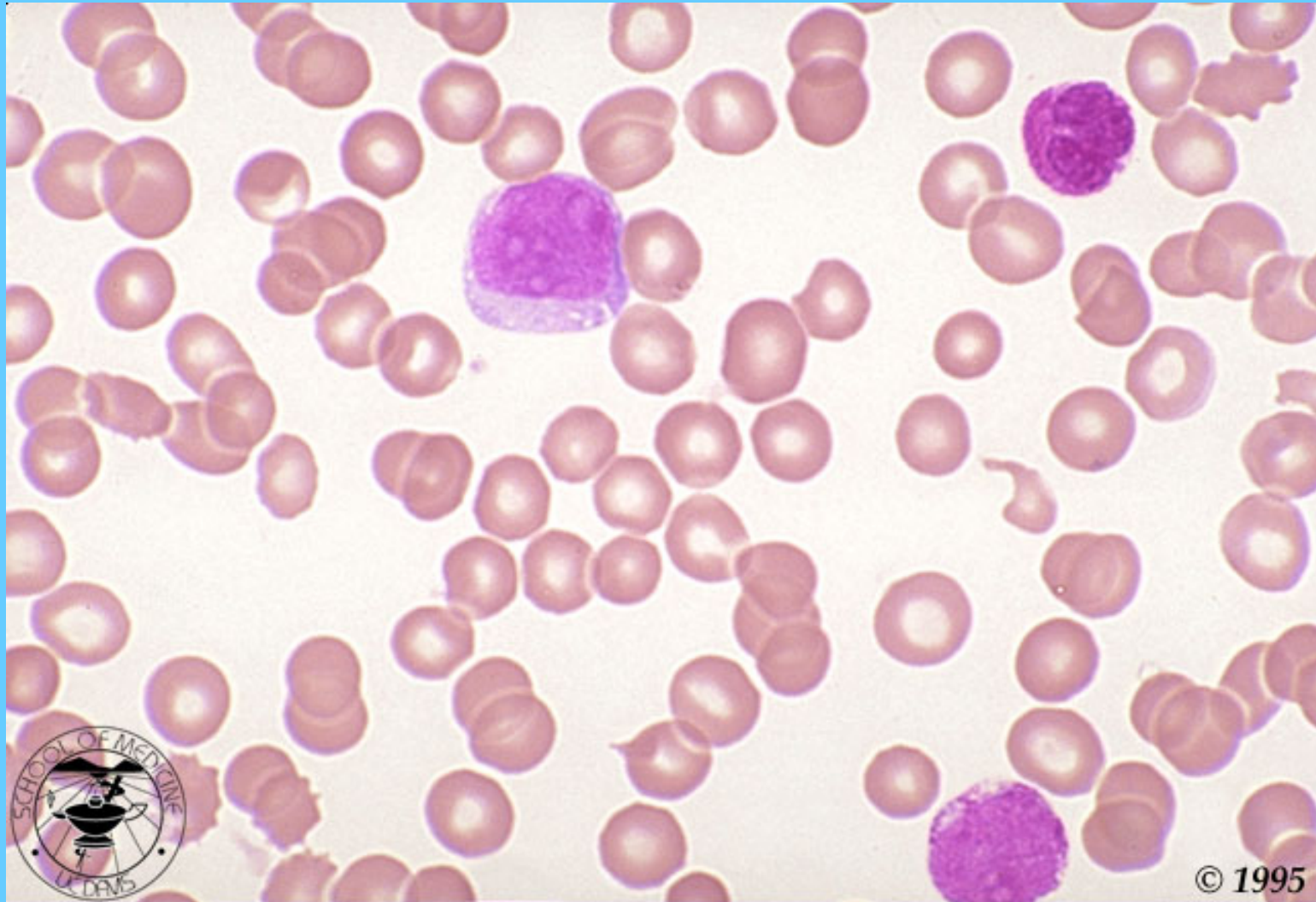


M.O. DE LGC

HIPERPLASIA GRANULOCÍTICA

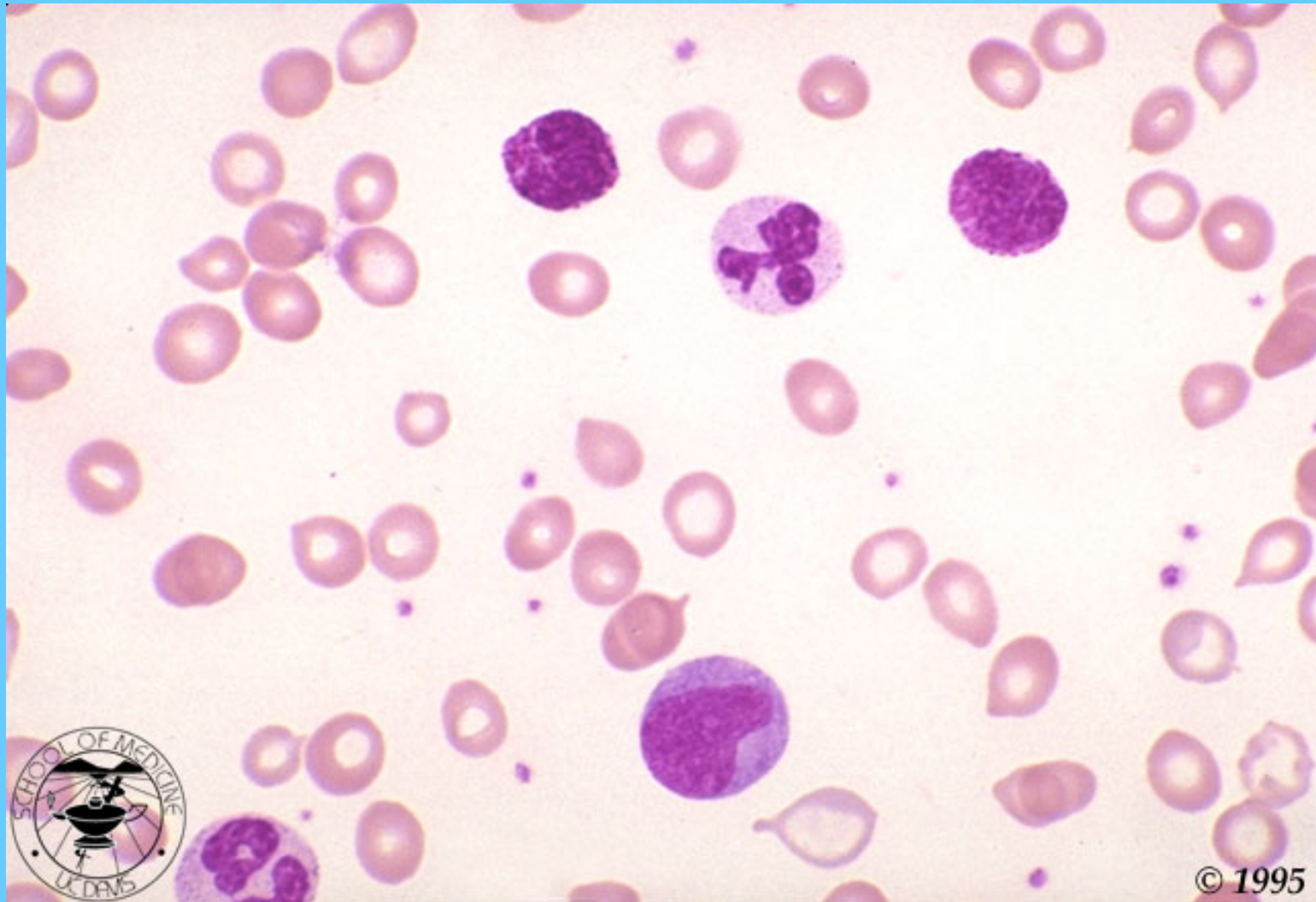


CRISIS BLÁSTICA EN UN PACIENTE CON LGC

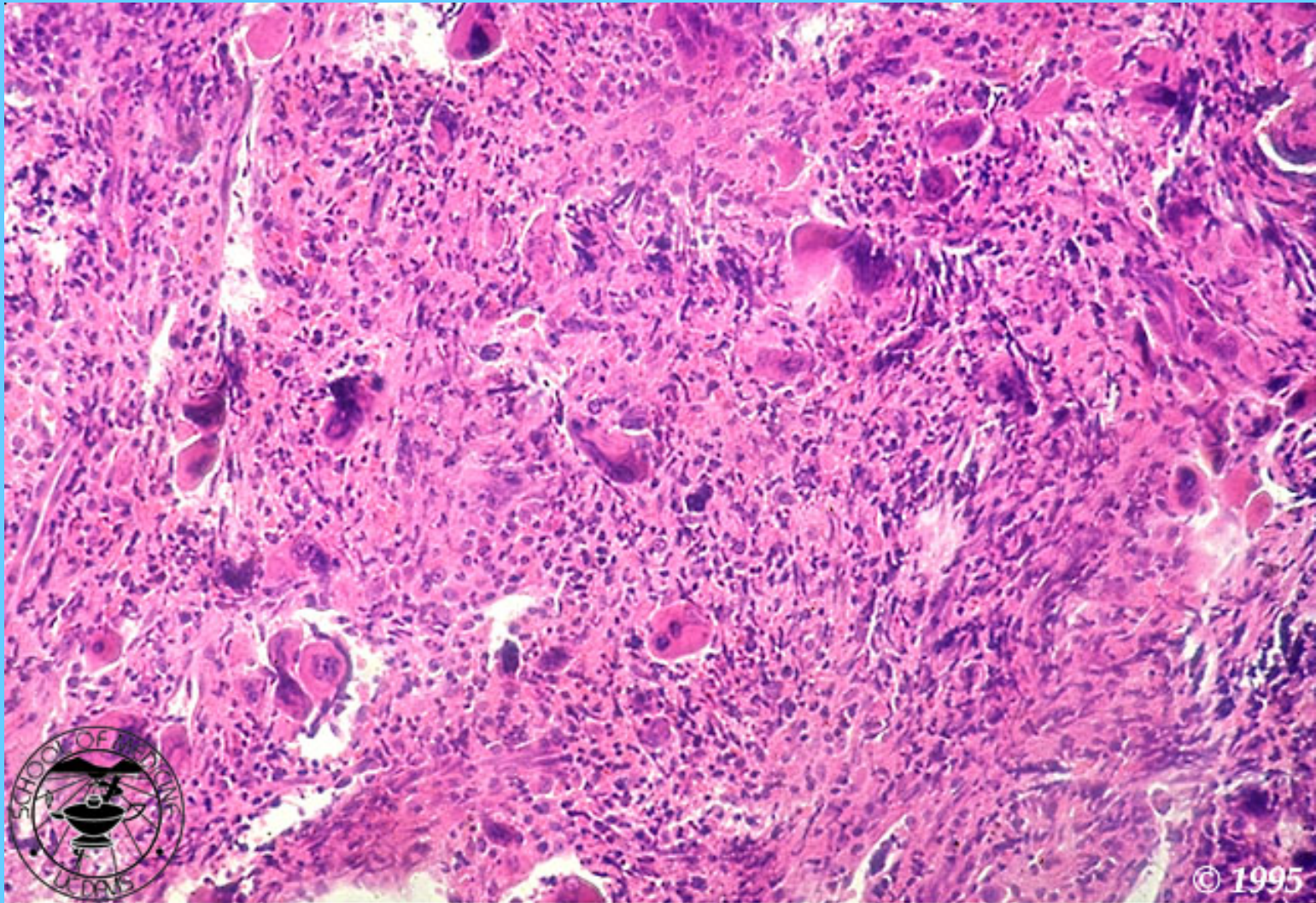


MIELOFIBROSIS CON METAPLASIA MIELOIDE

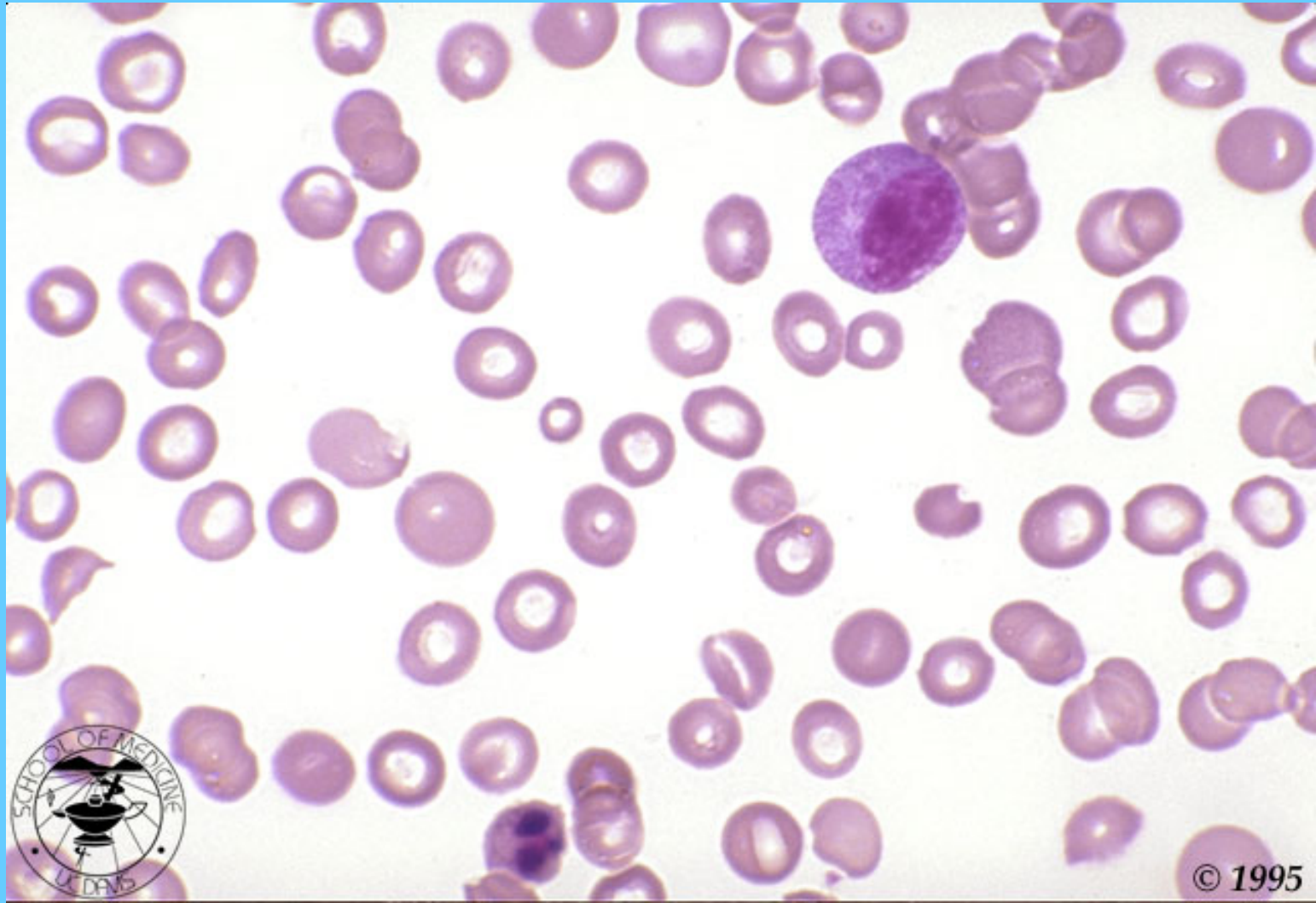(DACRIOCITOS, Y PRECURSORES DE NEUTRÓFILOS)



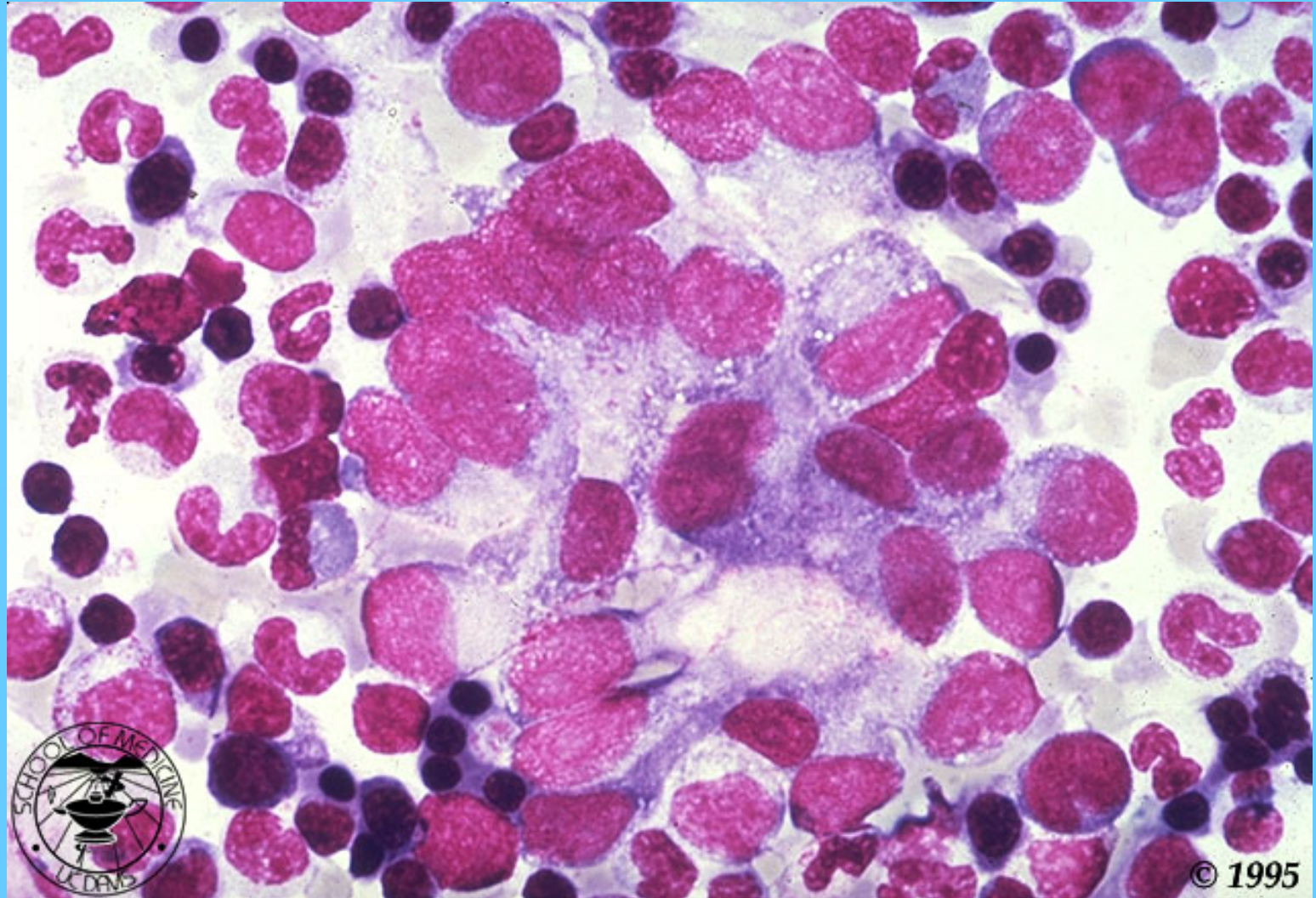
MELOFIBROSIS, M.O.



FROTIS DE SANFRE PERIFÉRICA DE UN CASO DE C.A. METASTÁSICO A M.O.

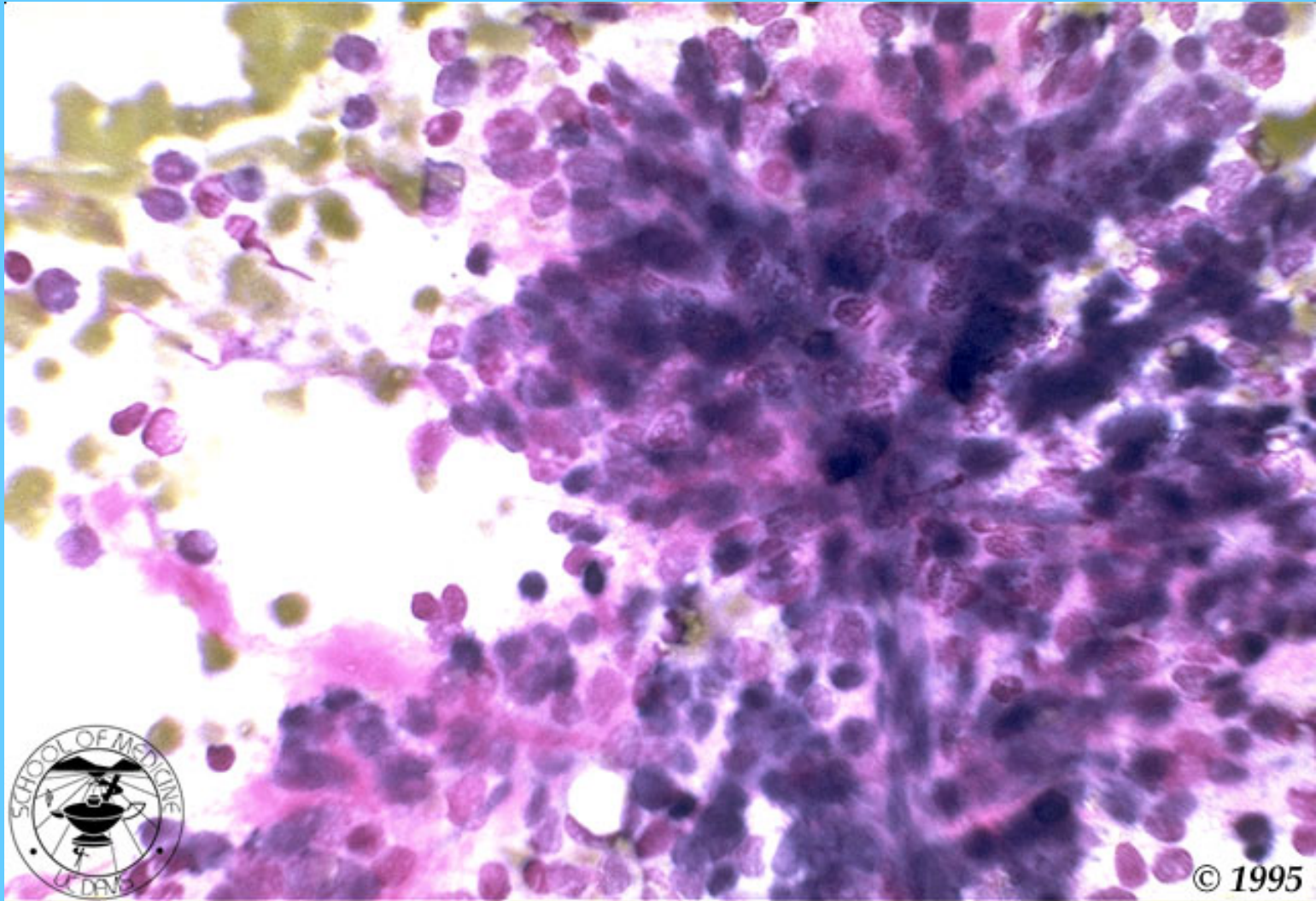


CANCER CON METÁSTASIS A M.O.

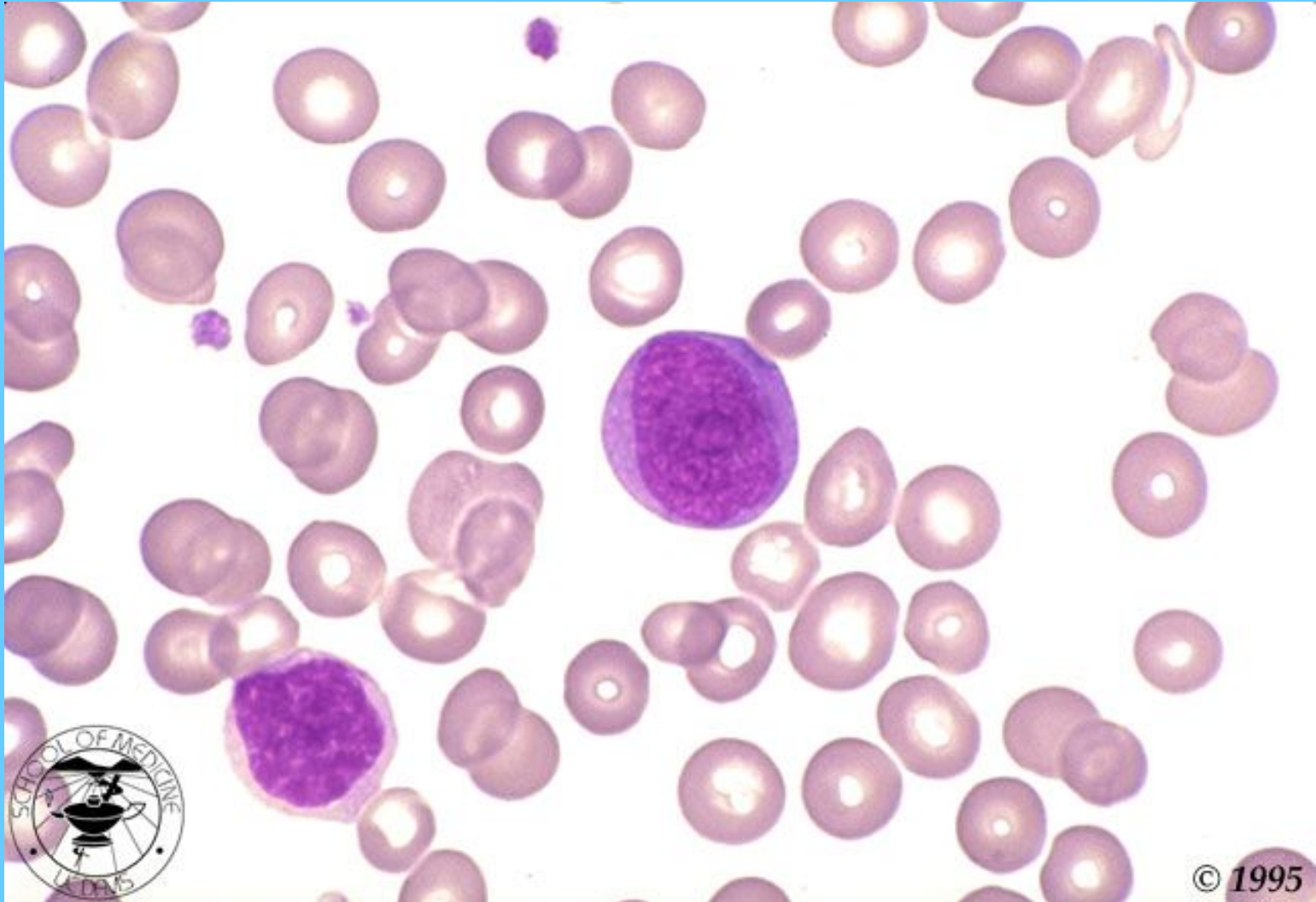


© 1995

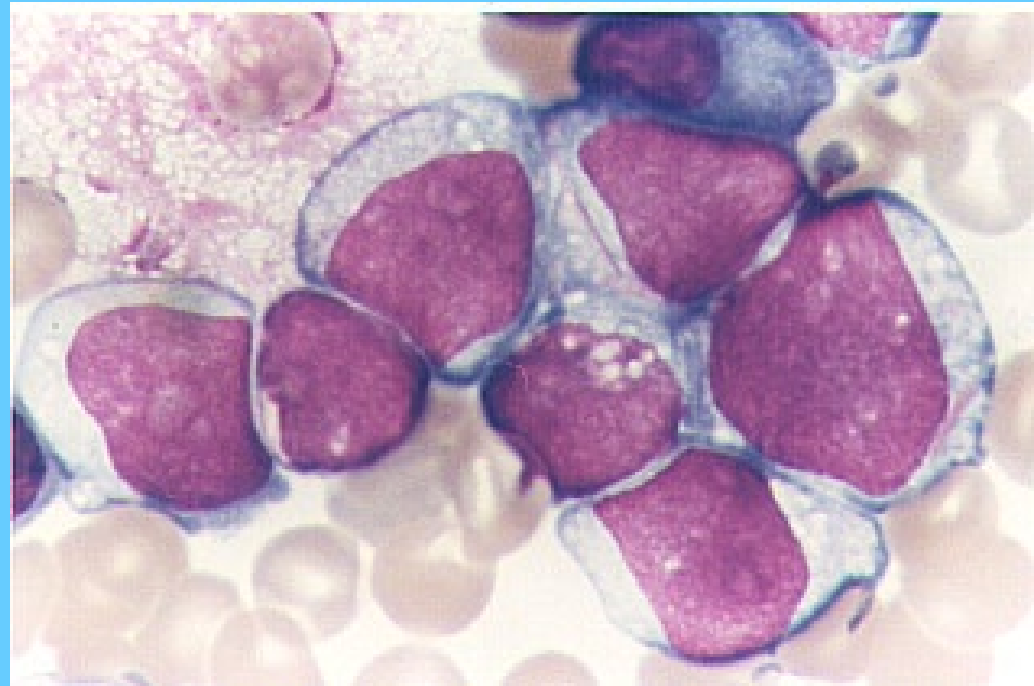
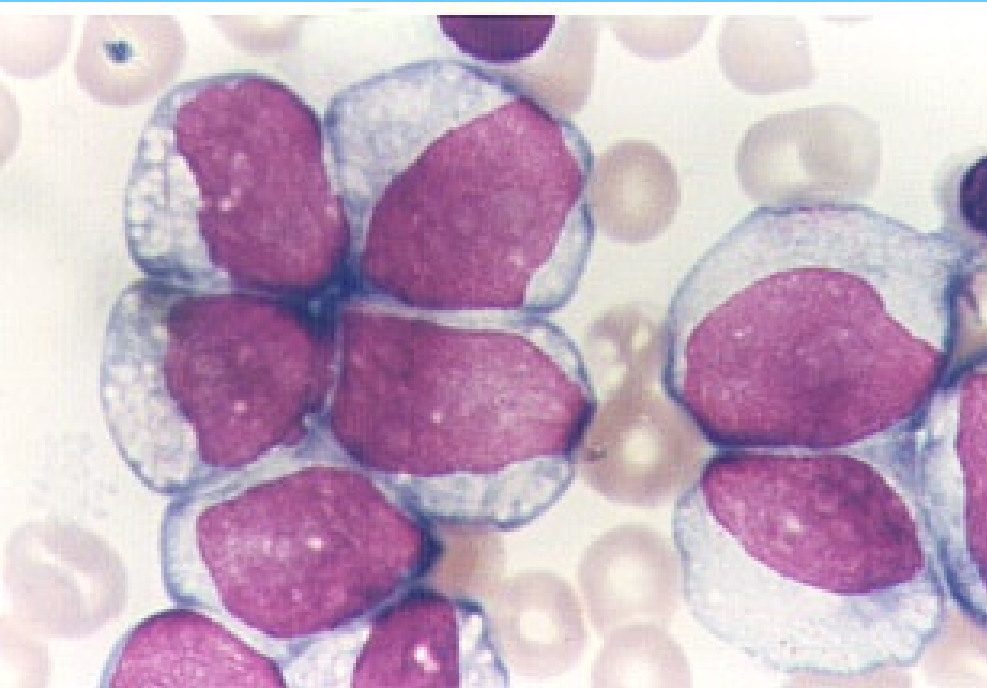
MELANOMA METASTASICO A M.O.



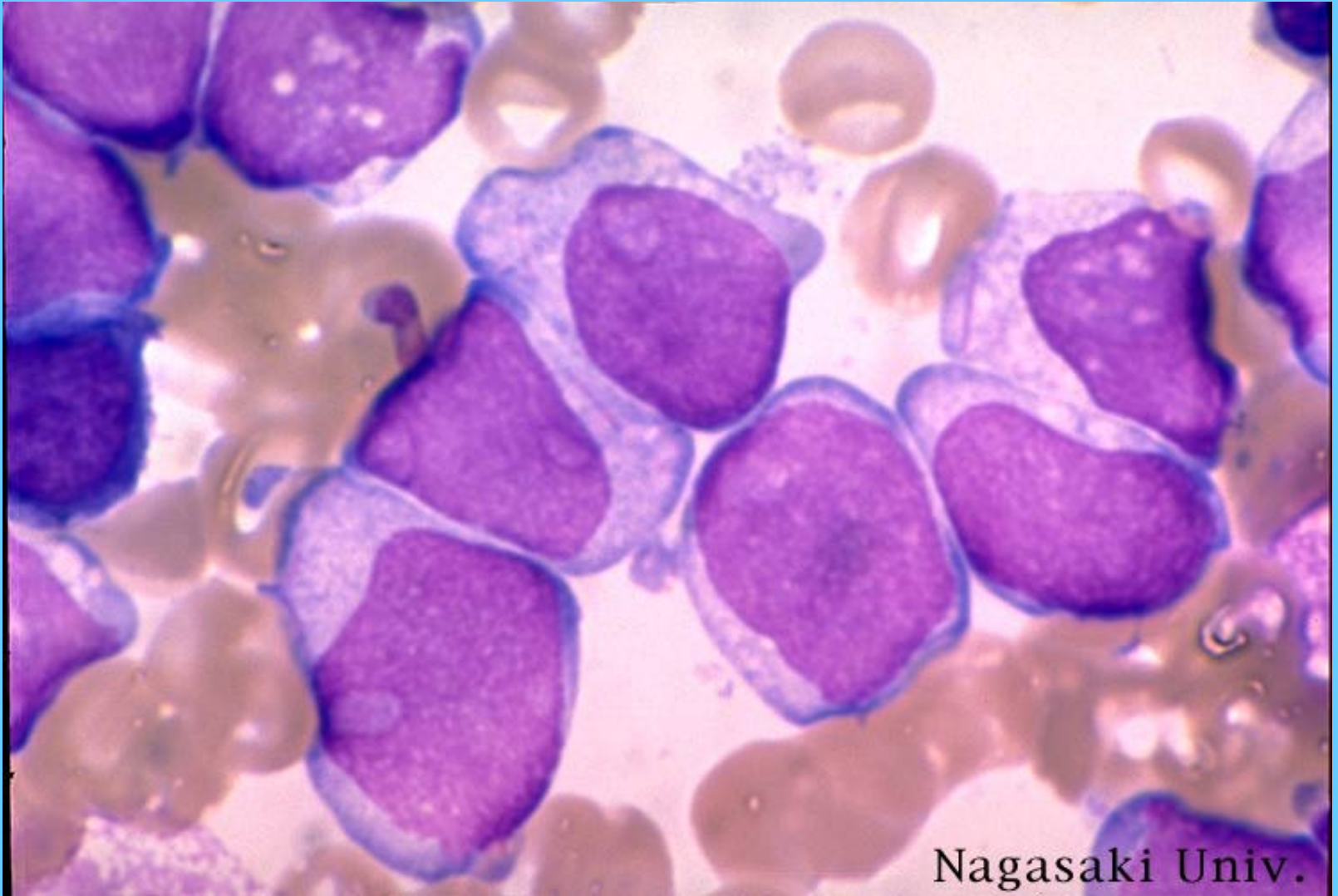
MIELOBLASTO (M1)



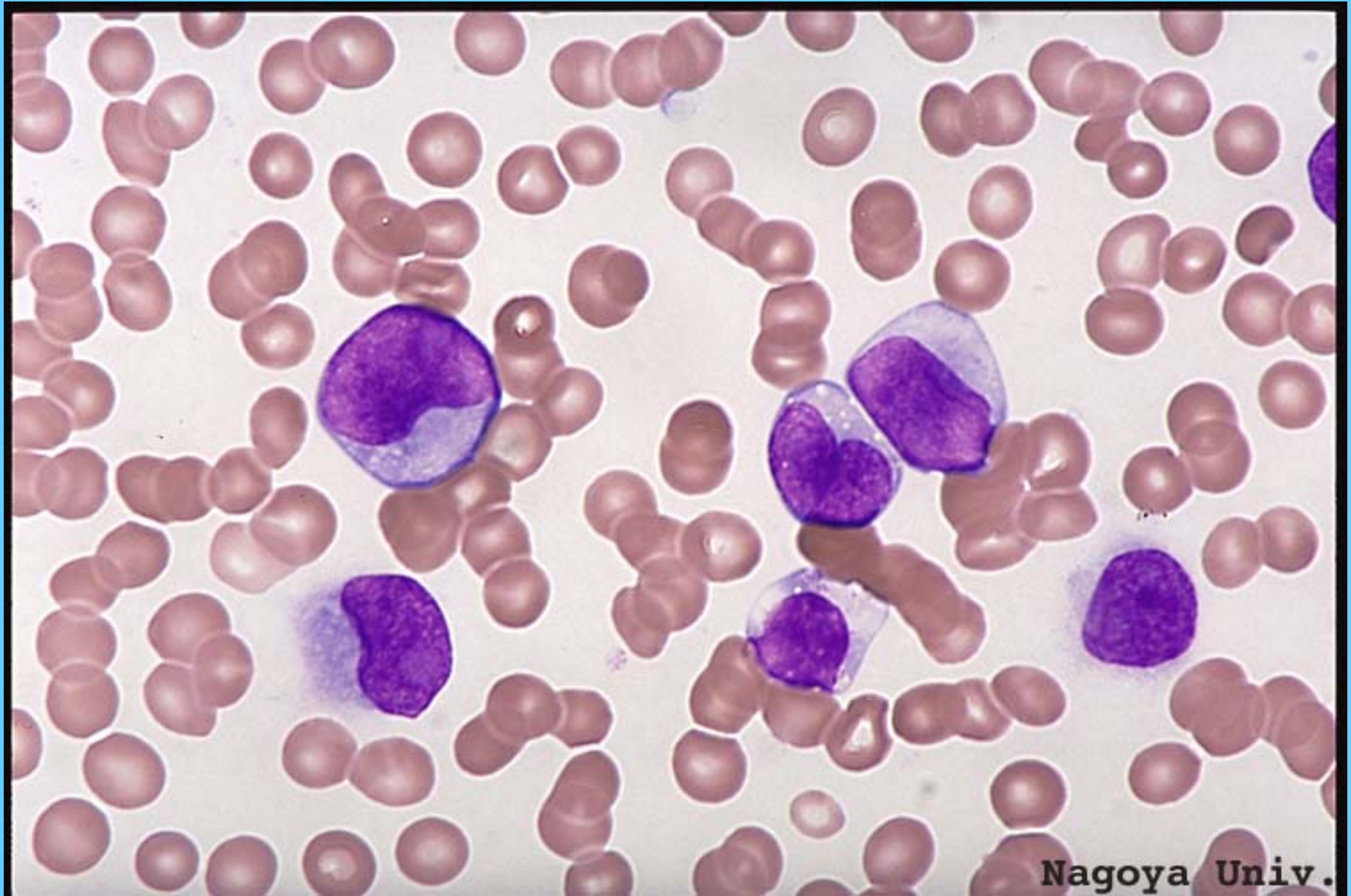
M1, M.O.



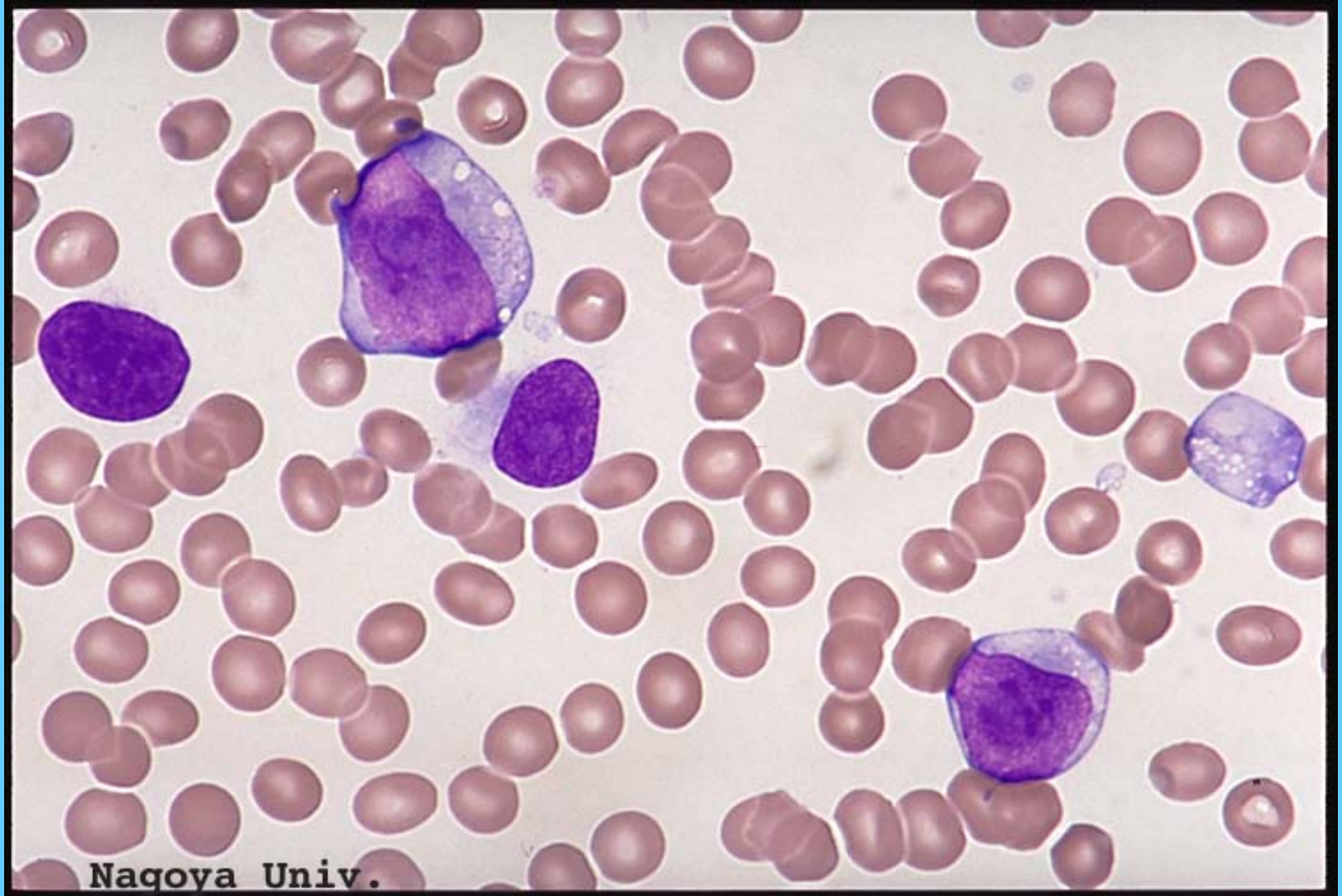M1, M.O.



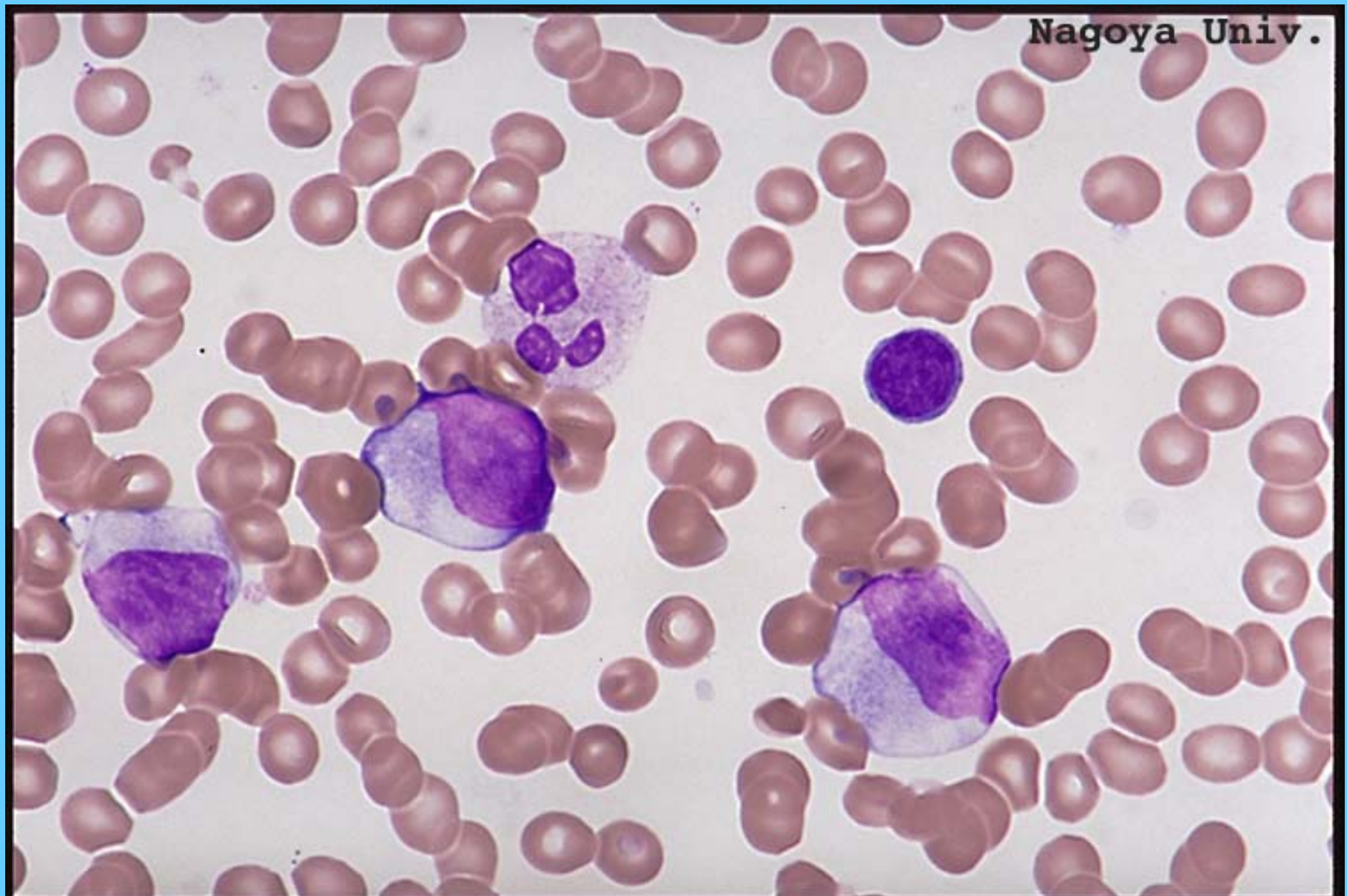
M2, SANGRE PERIFÉRICA



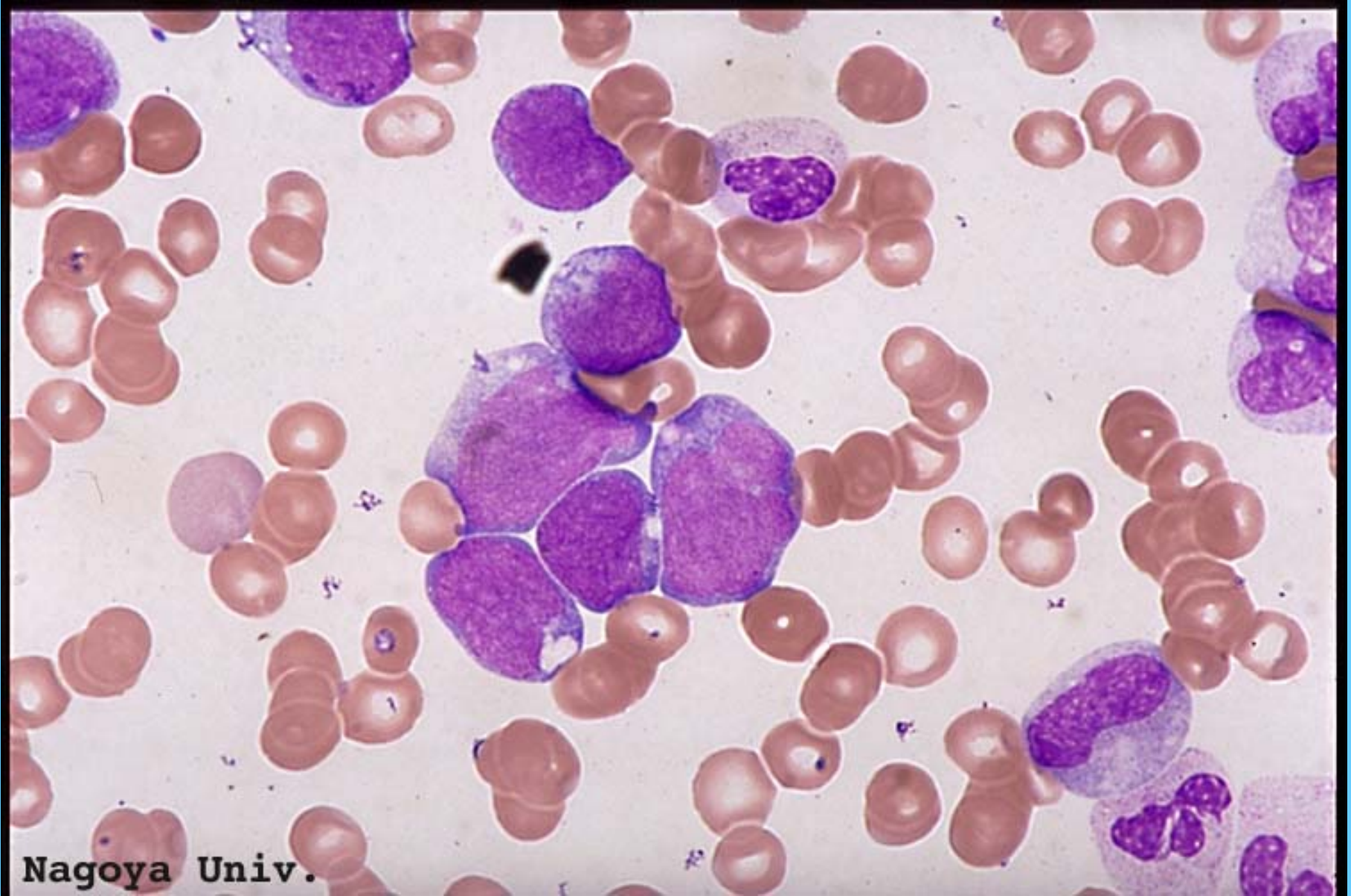
M2, SANGRE PERIFÉRICA



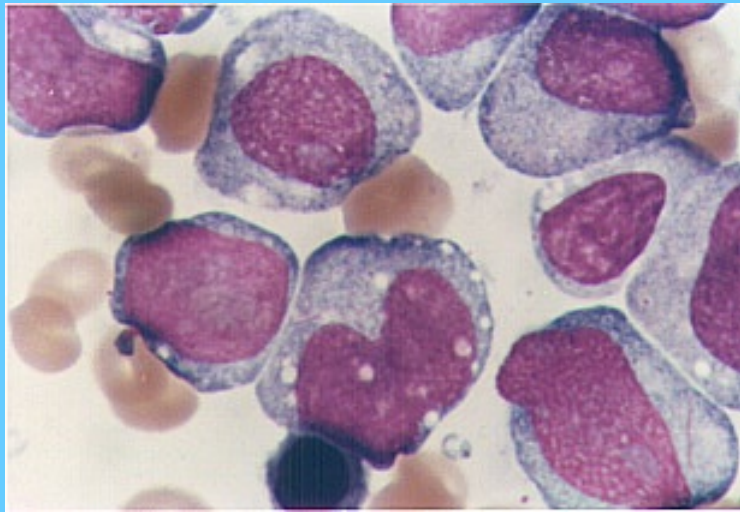
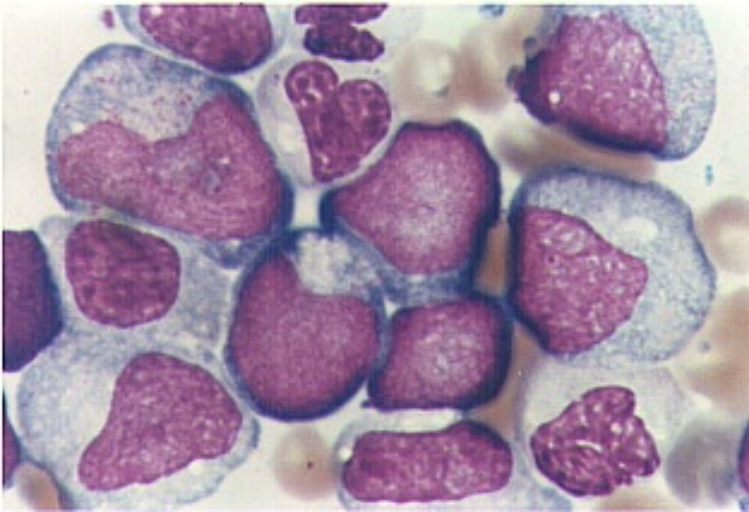
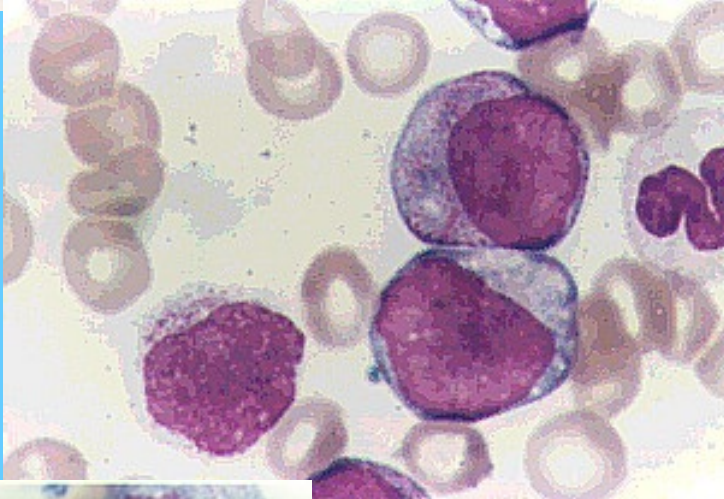
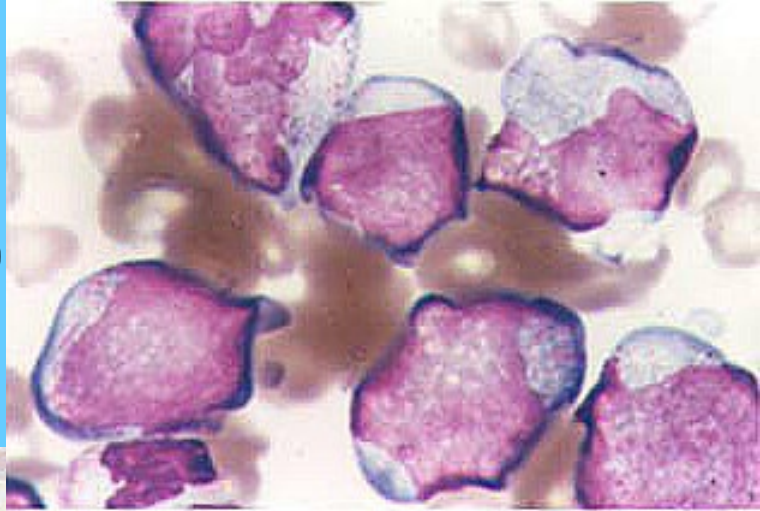
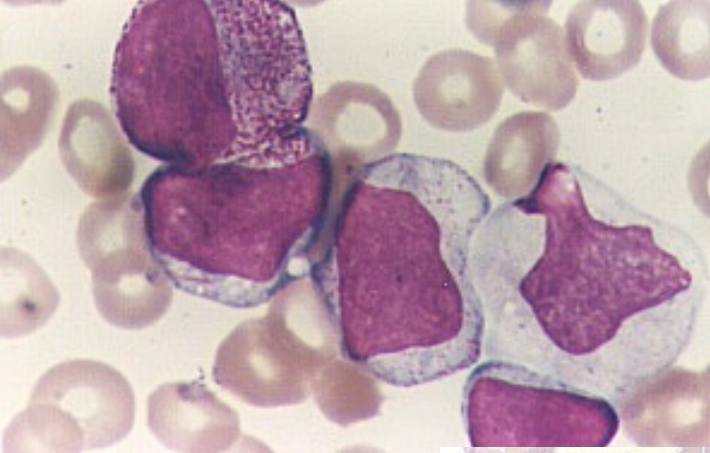
M2, SANGRE PERIFÉRICA



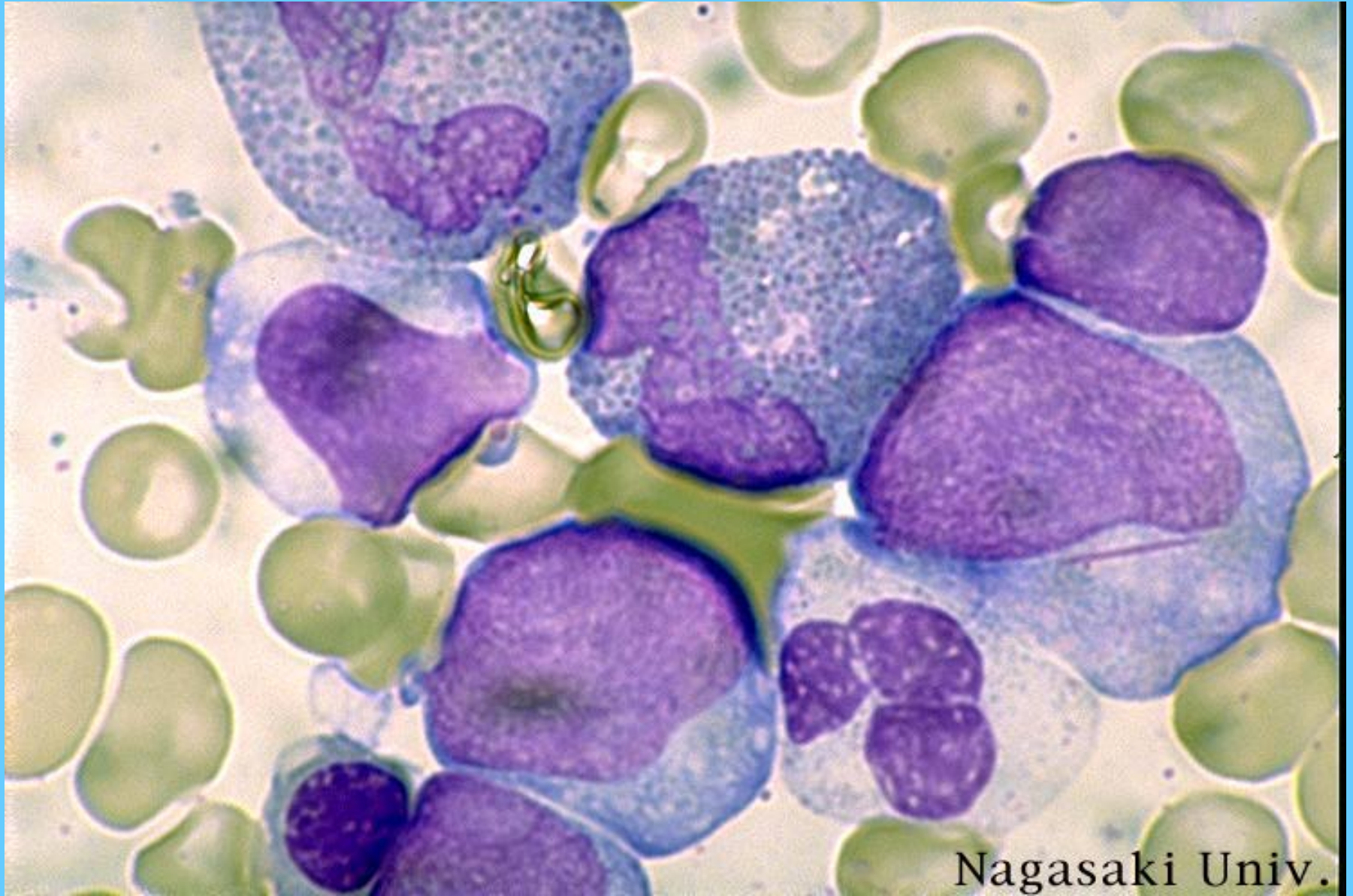
M2, M.O.



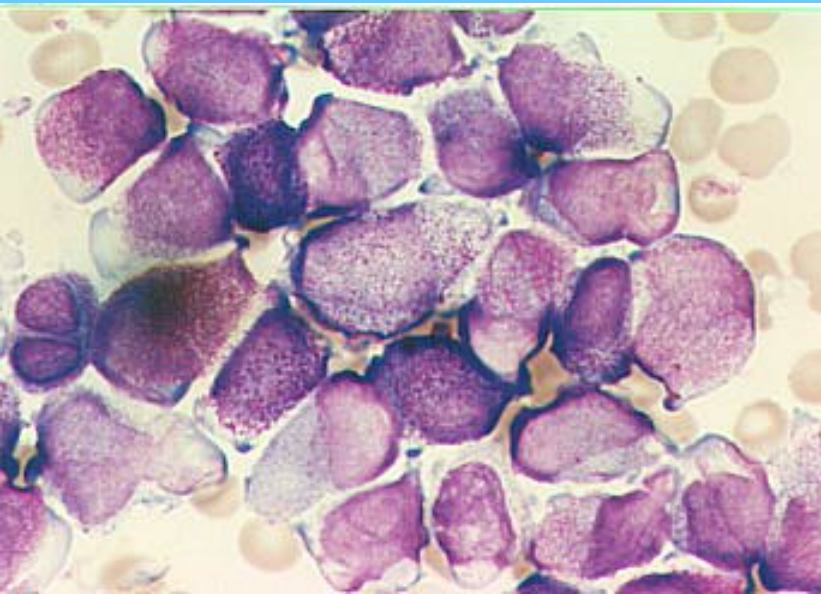
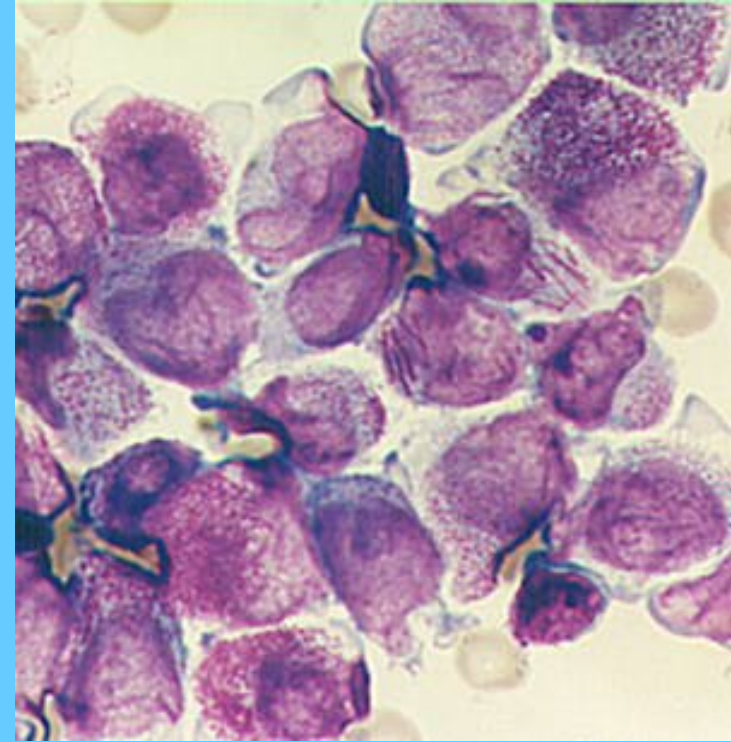
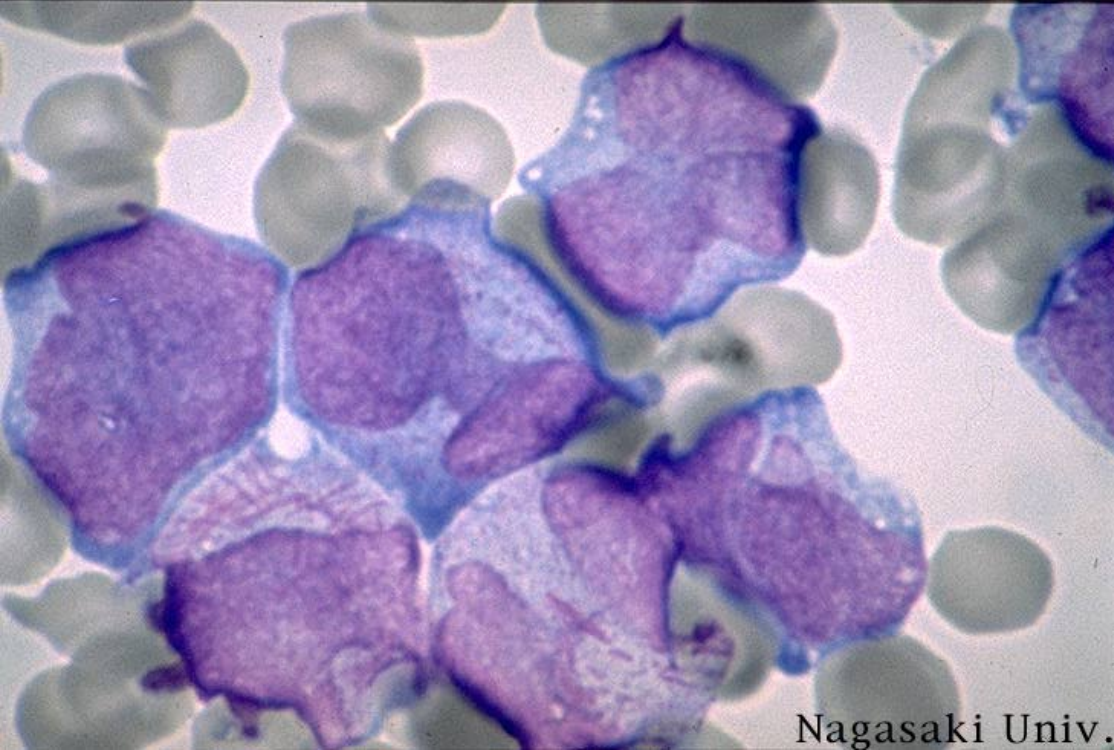
M2, M.O



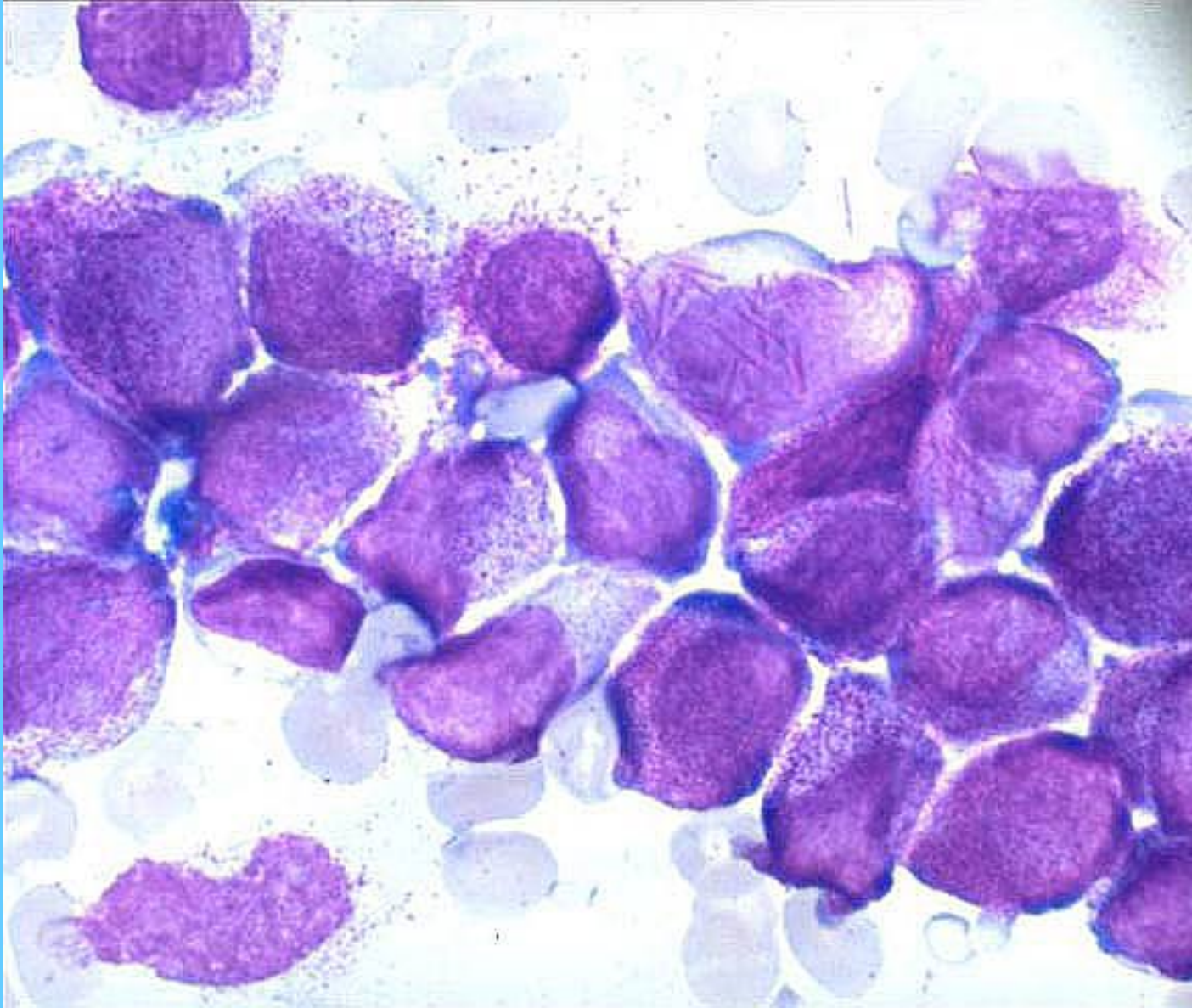
M2 CON EOSINOFILIA



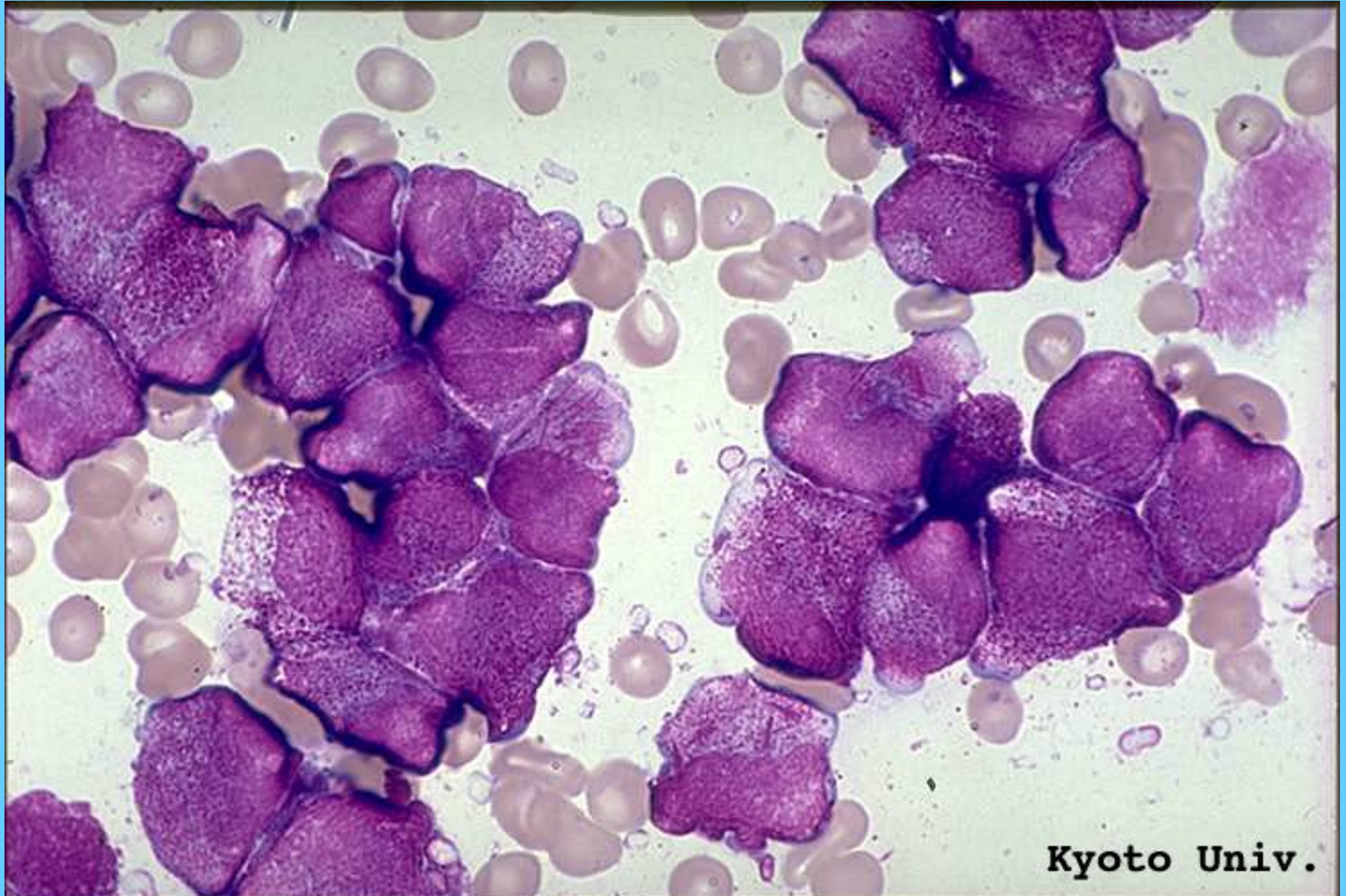
M3, M.O.



M3, M.O.

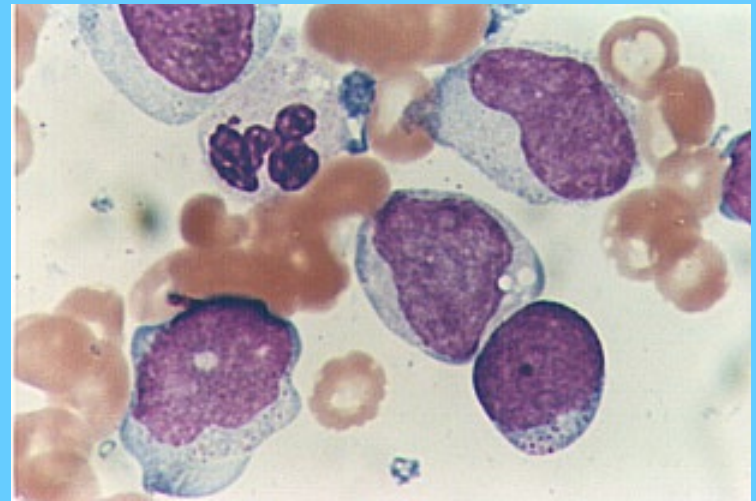
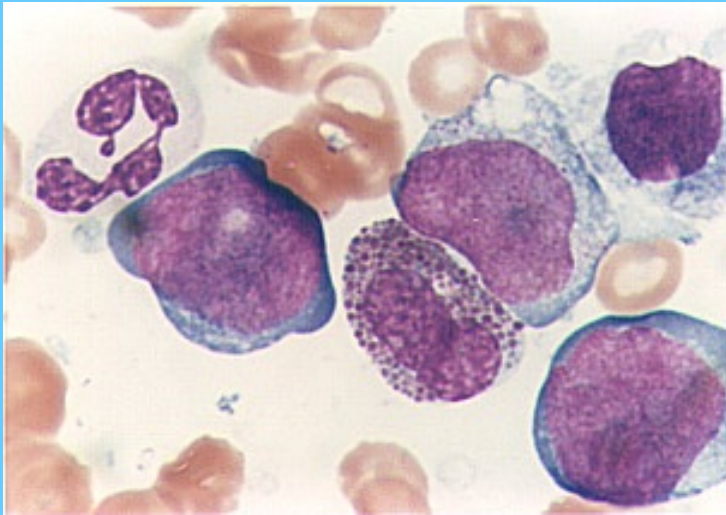


M3, M.O.

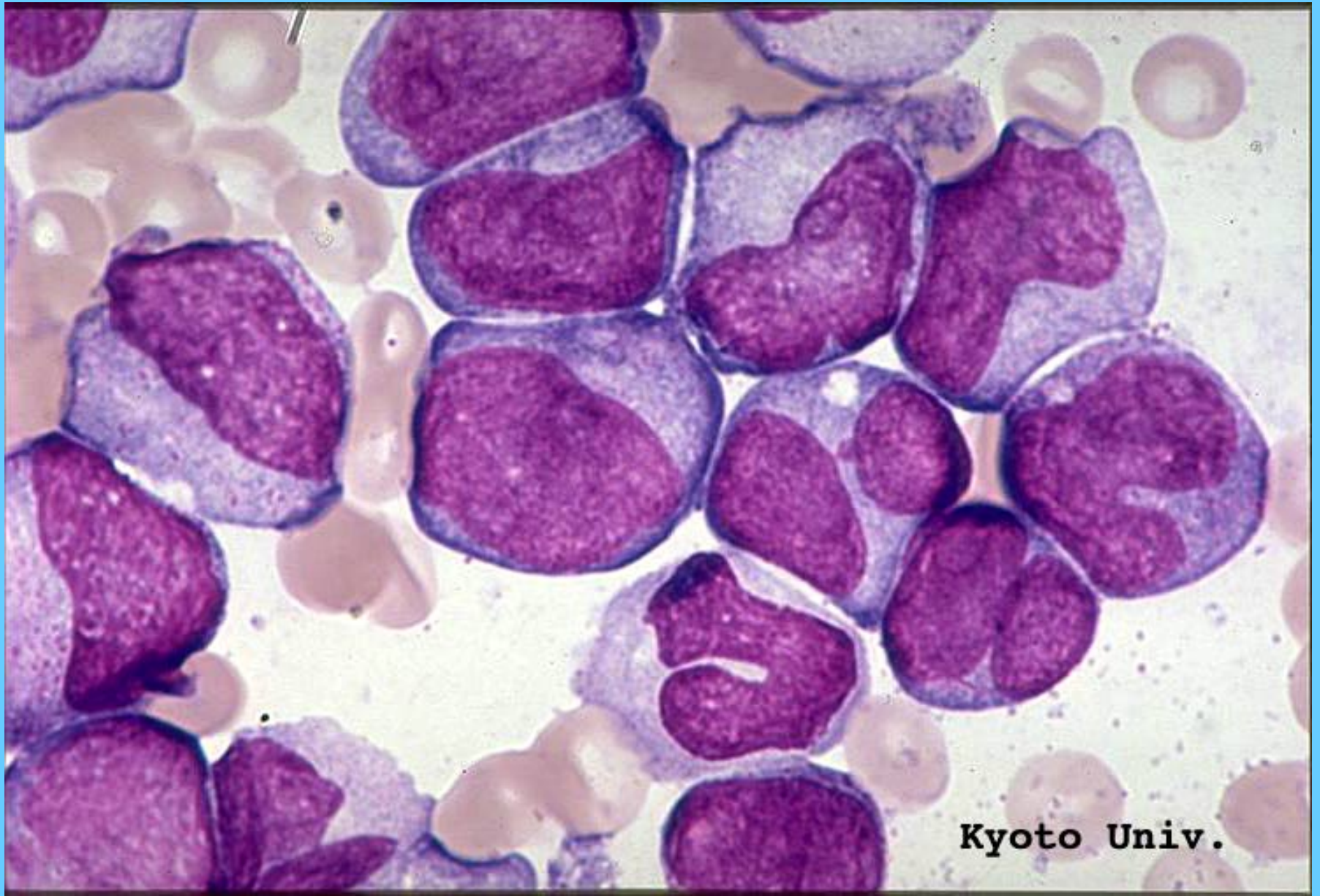

Kyoto Univ.

M4, M.O.

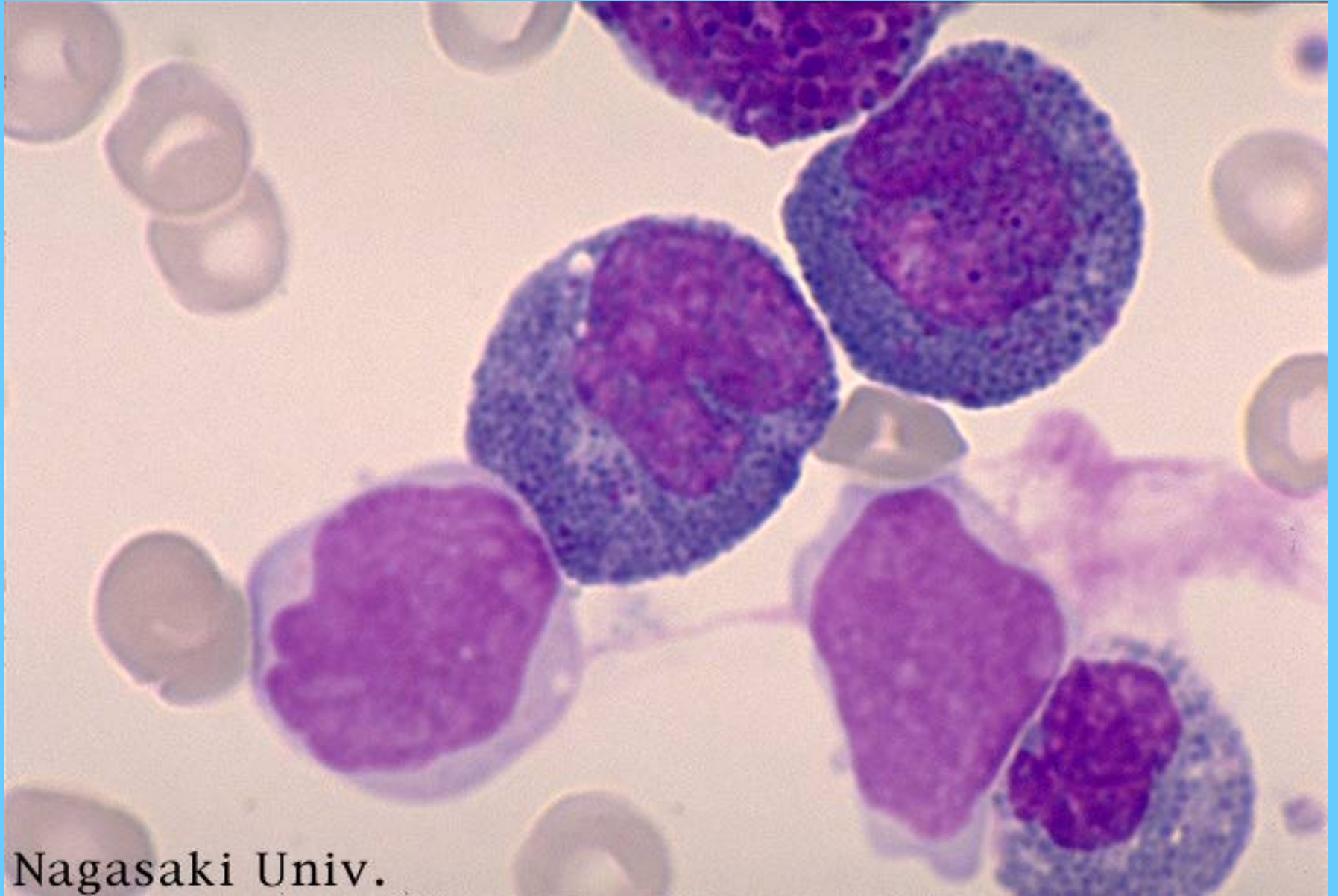


M4, M.O.

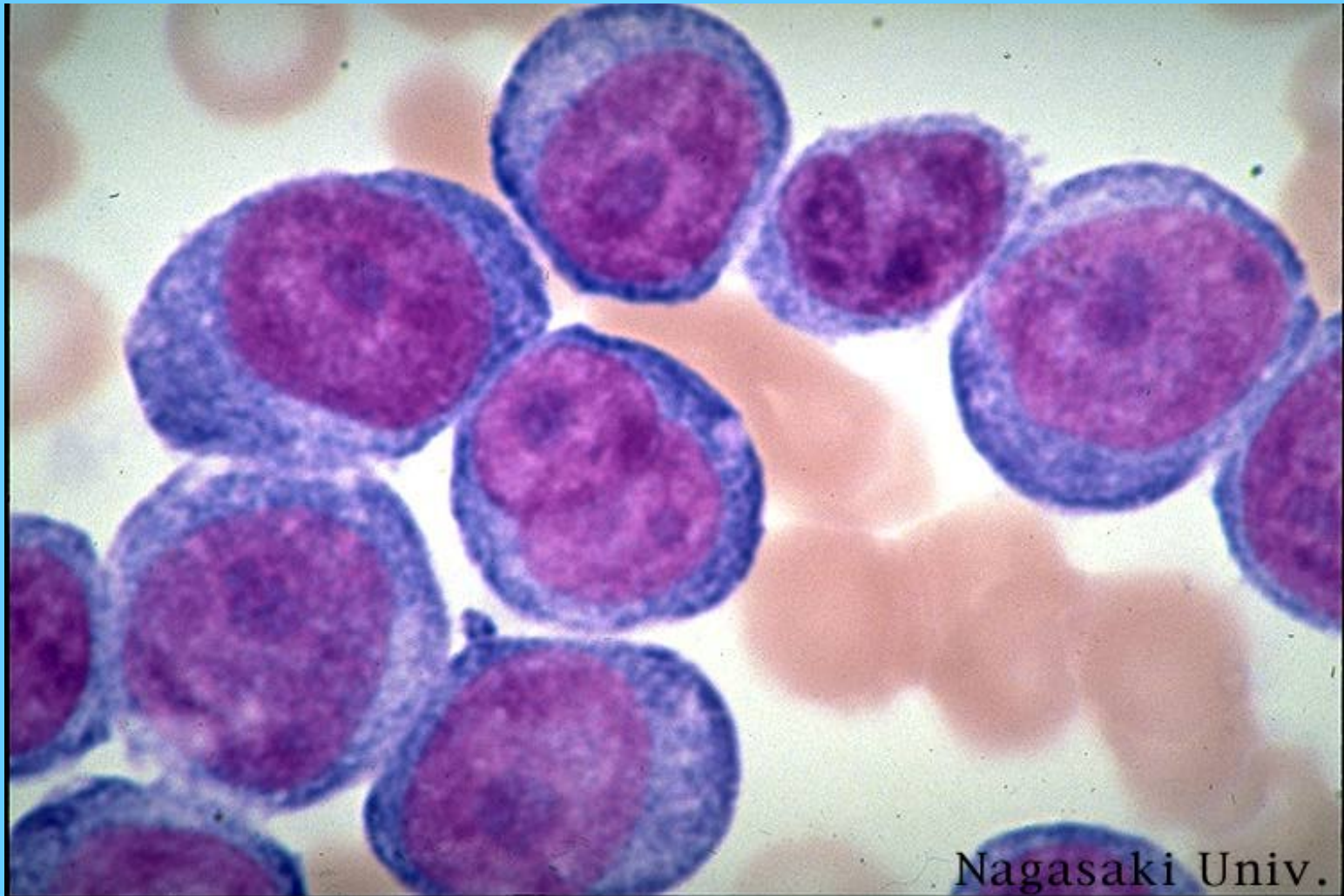


Kyoto Univ.

M4, CON EOSINOFILIA, M.O.

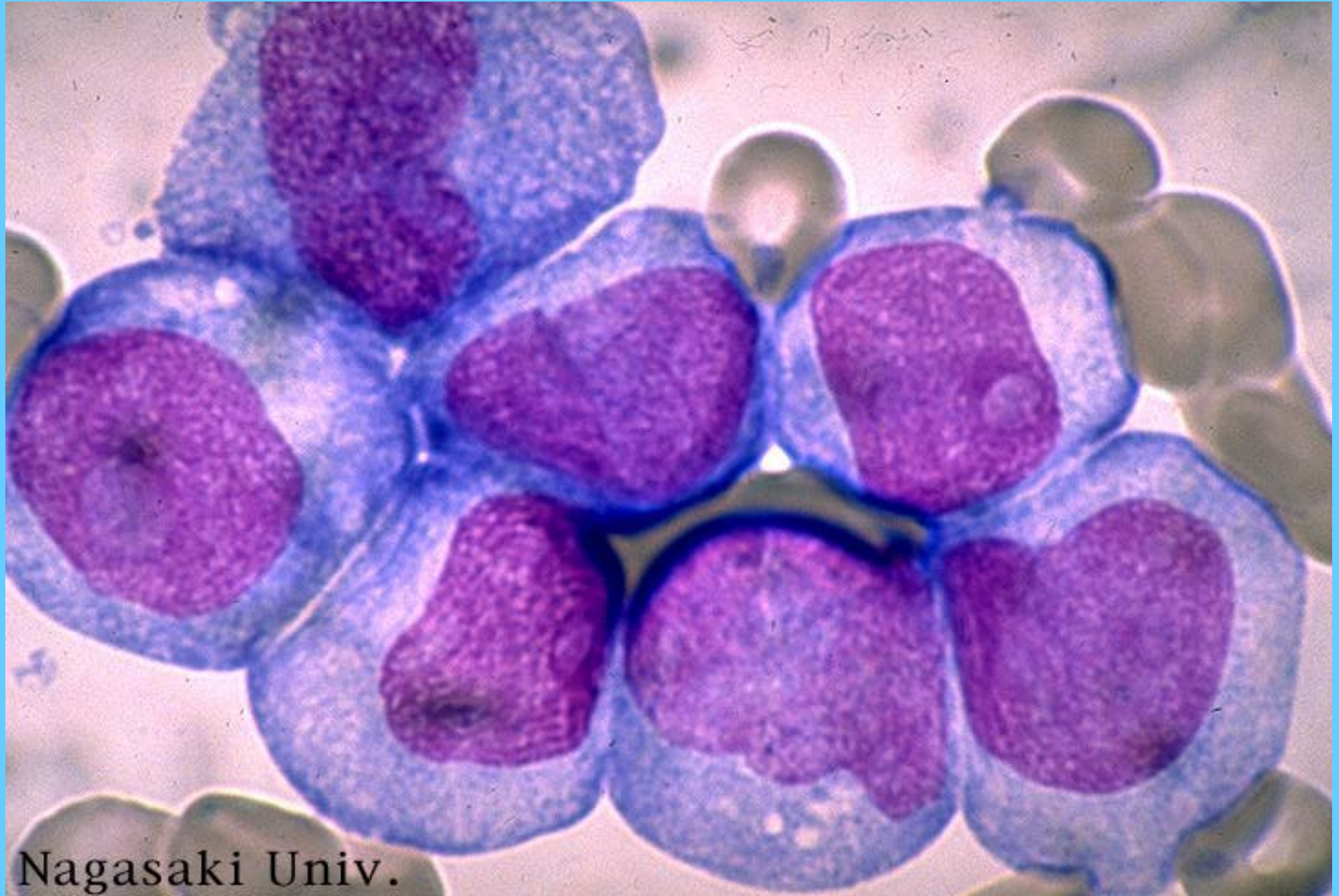


M5a

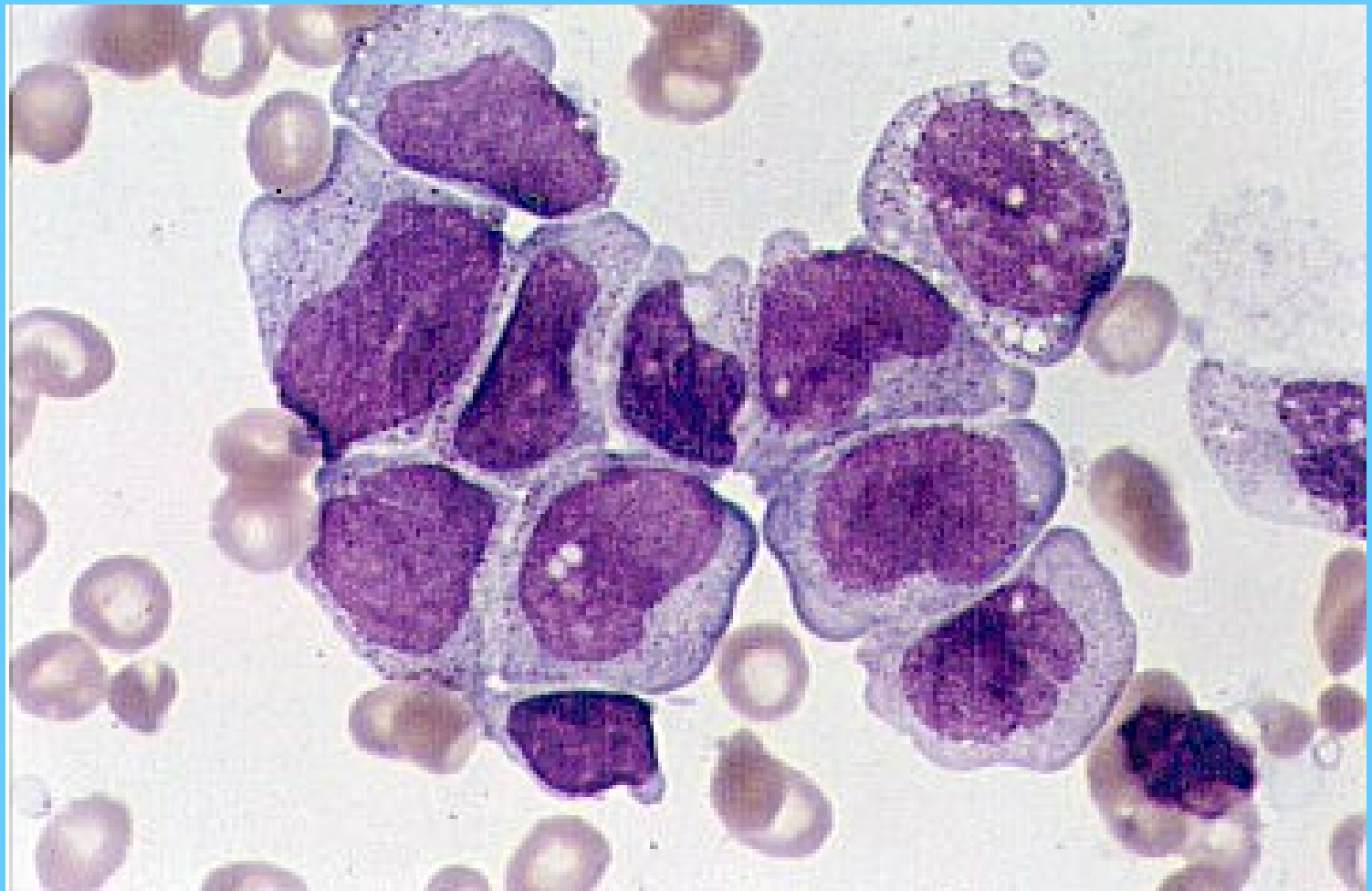


Nagasaki Univ.

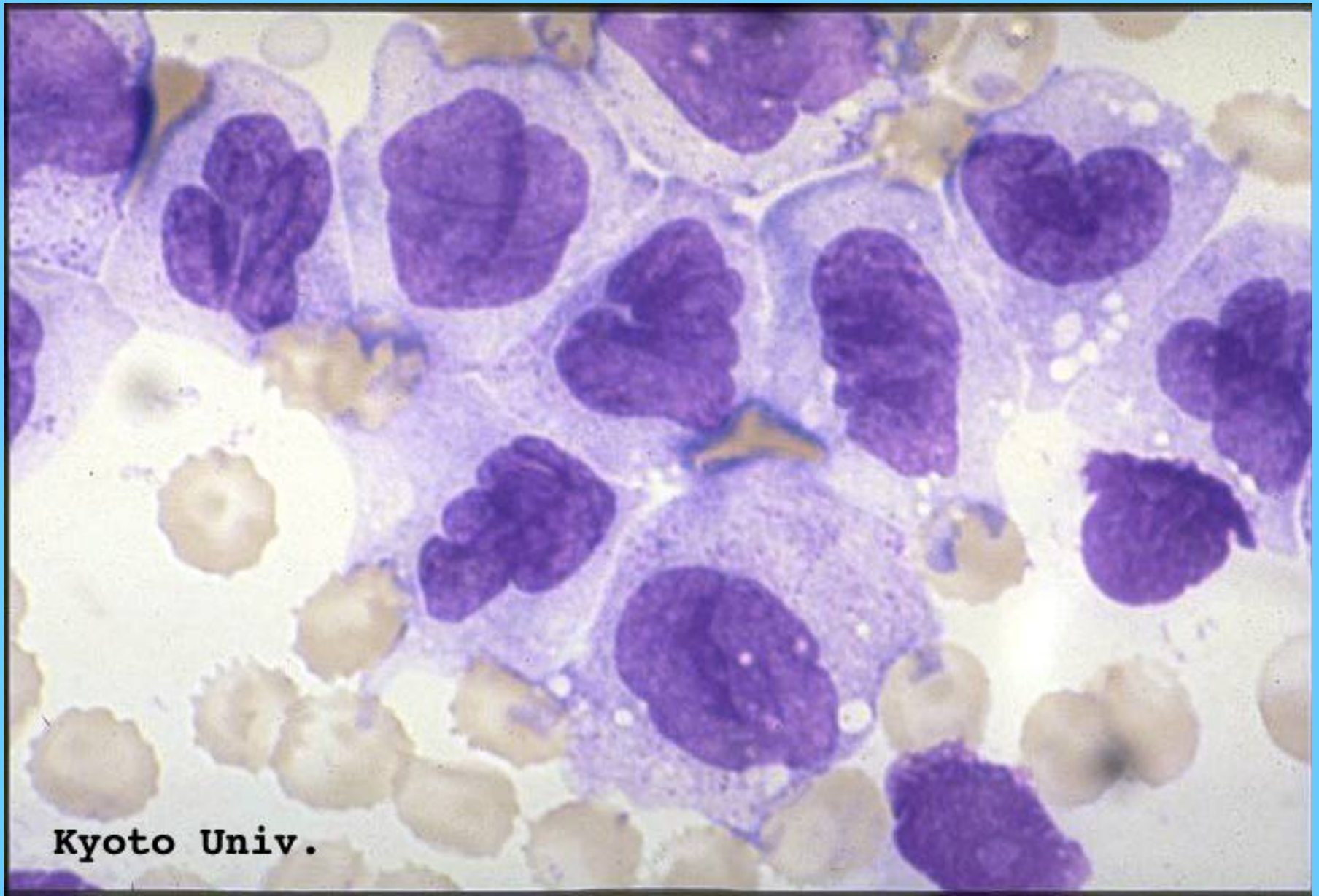
M5b



M5

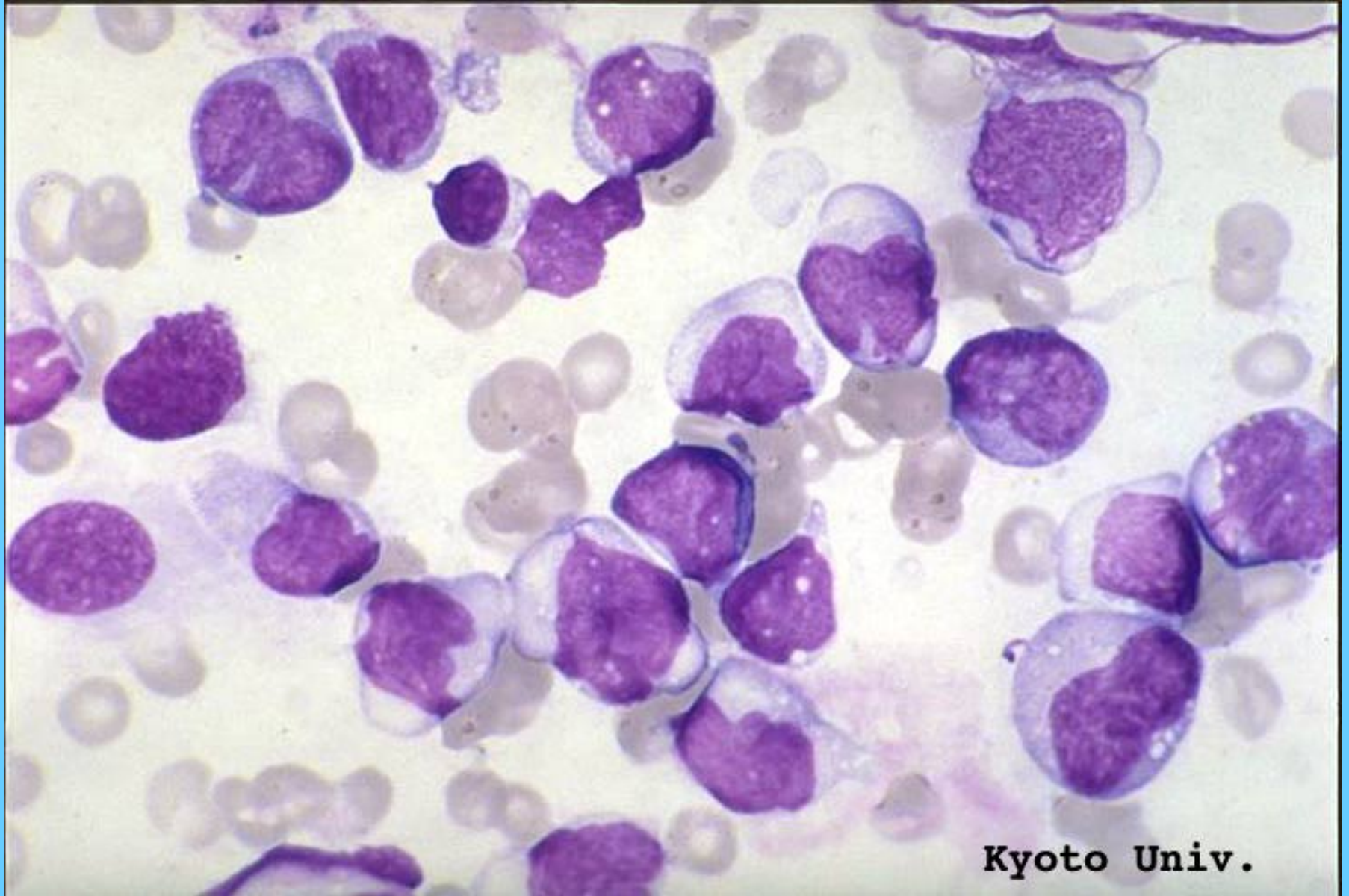


M5



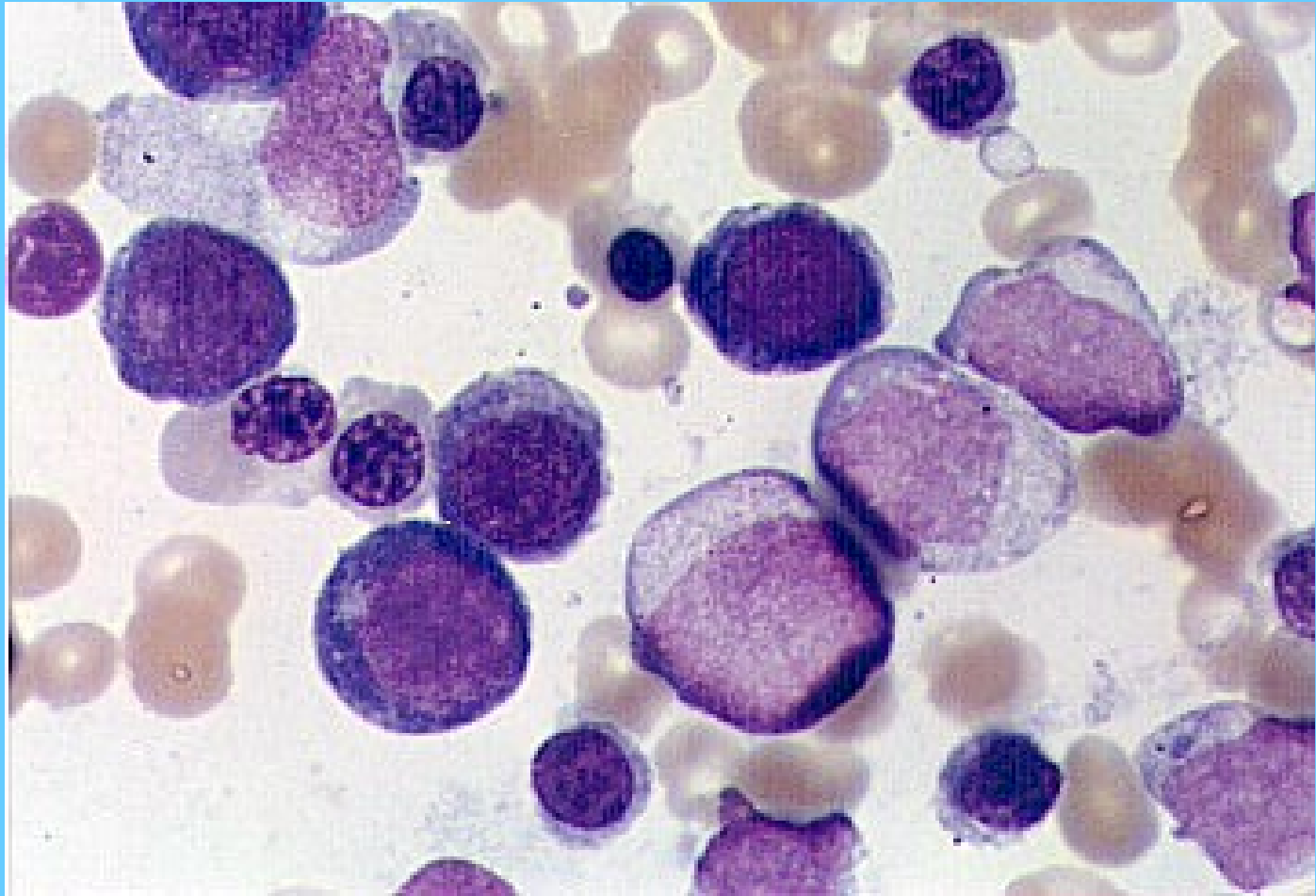
Kyoto Univ.

M5

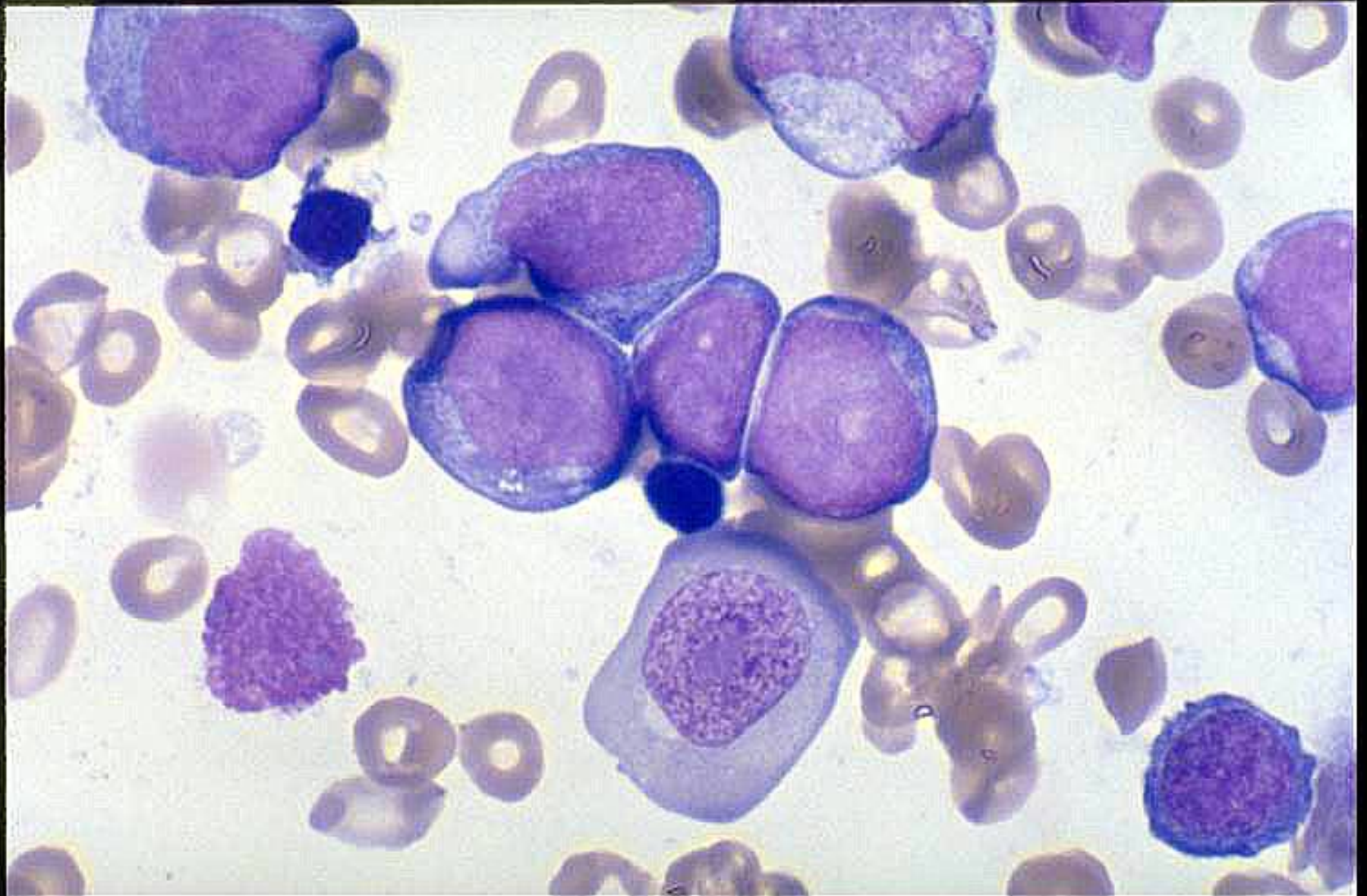


Kyoto Univ.

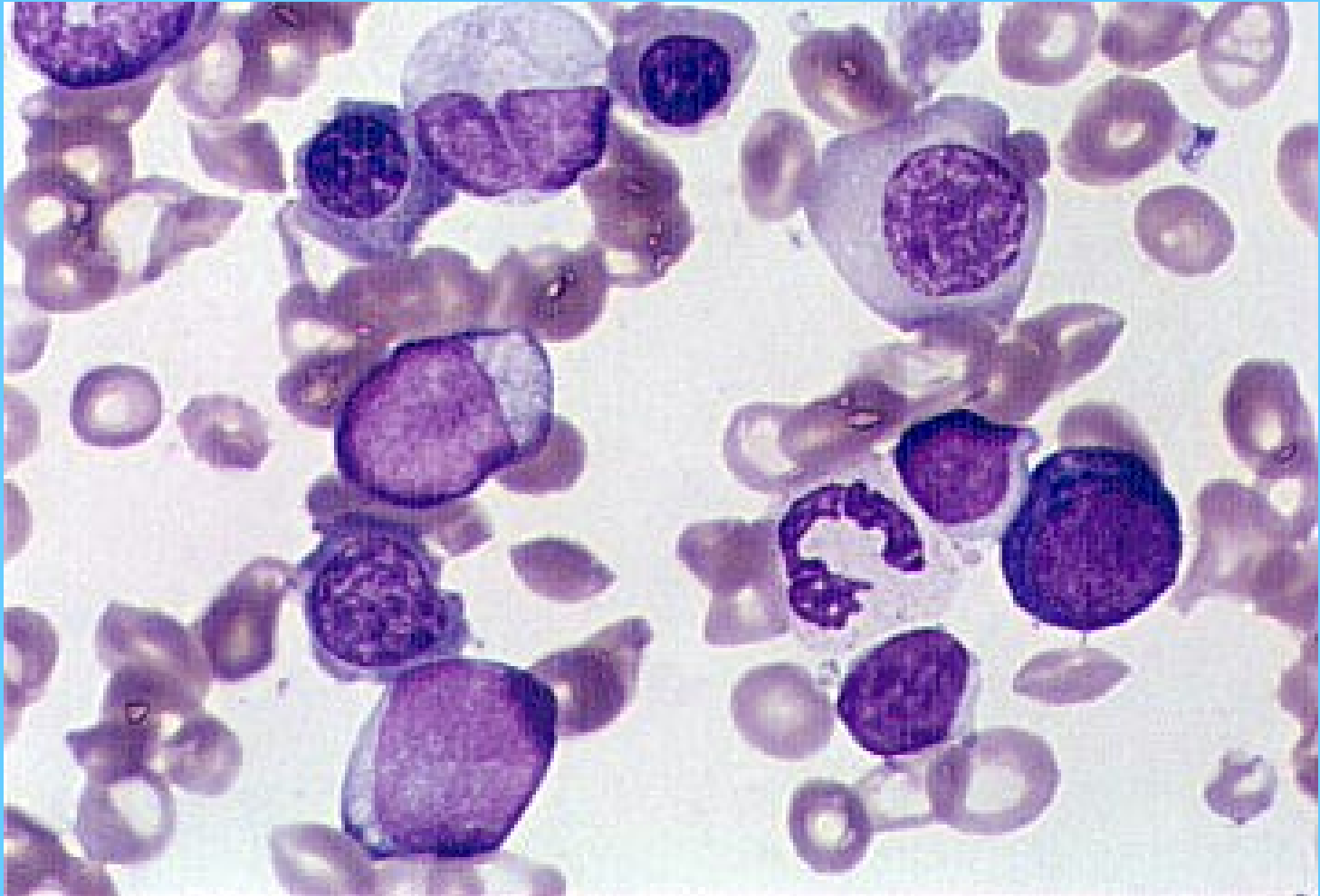
M6



M6

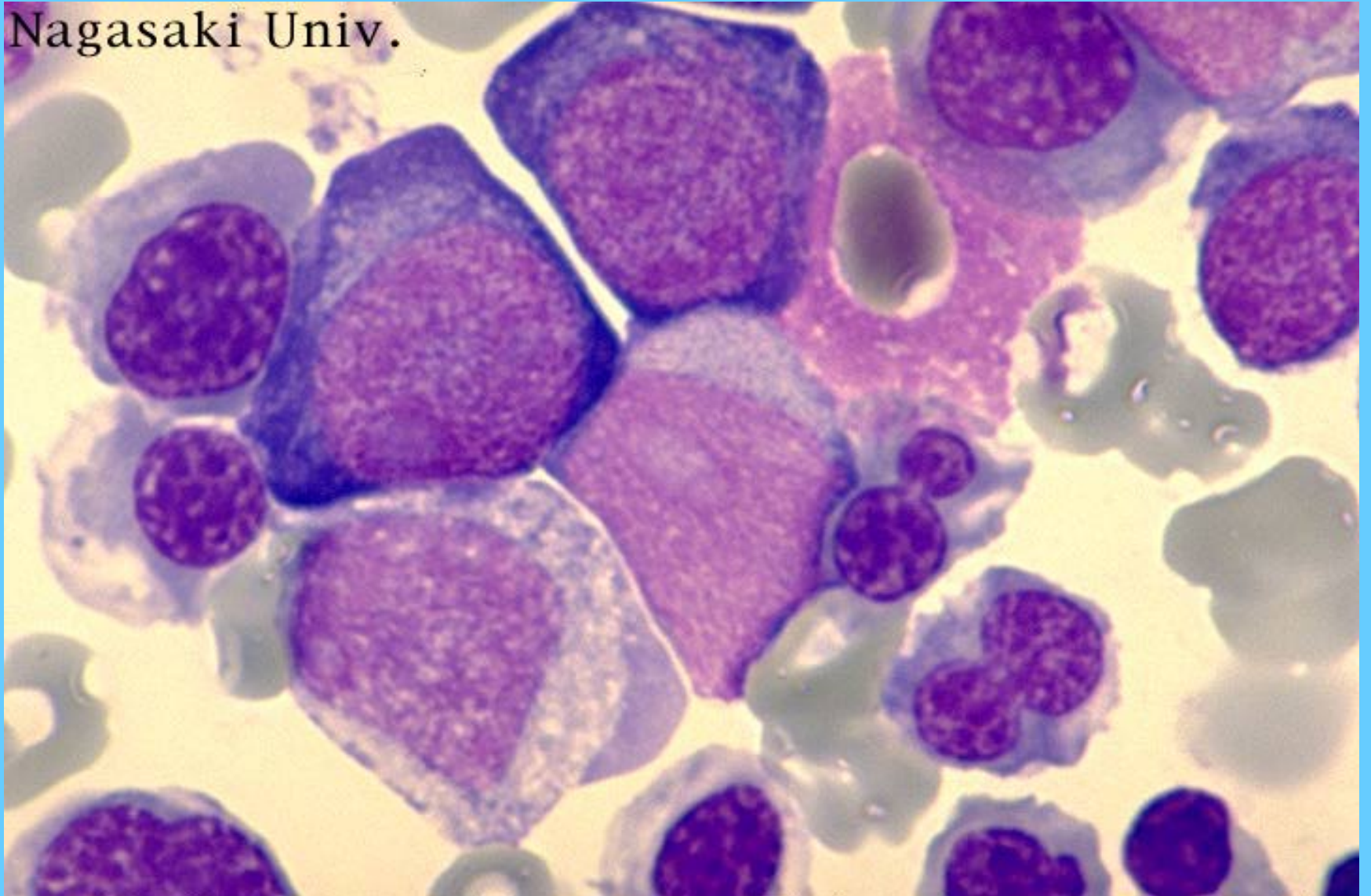


M6

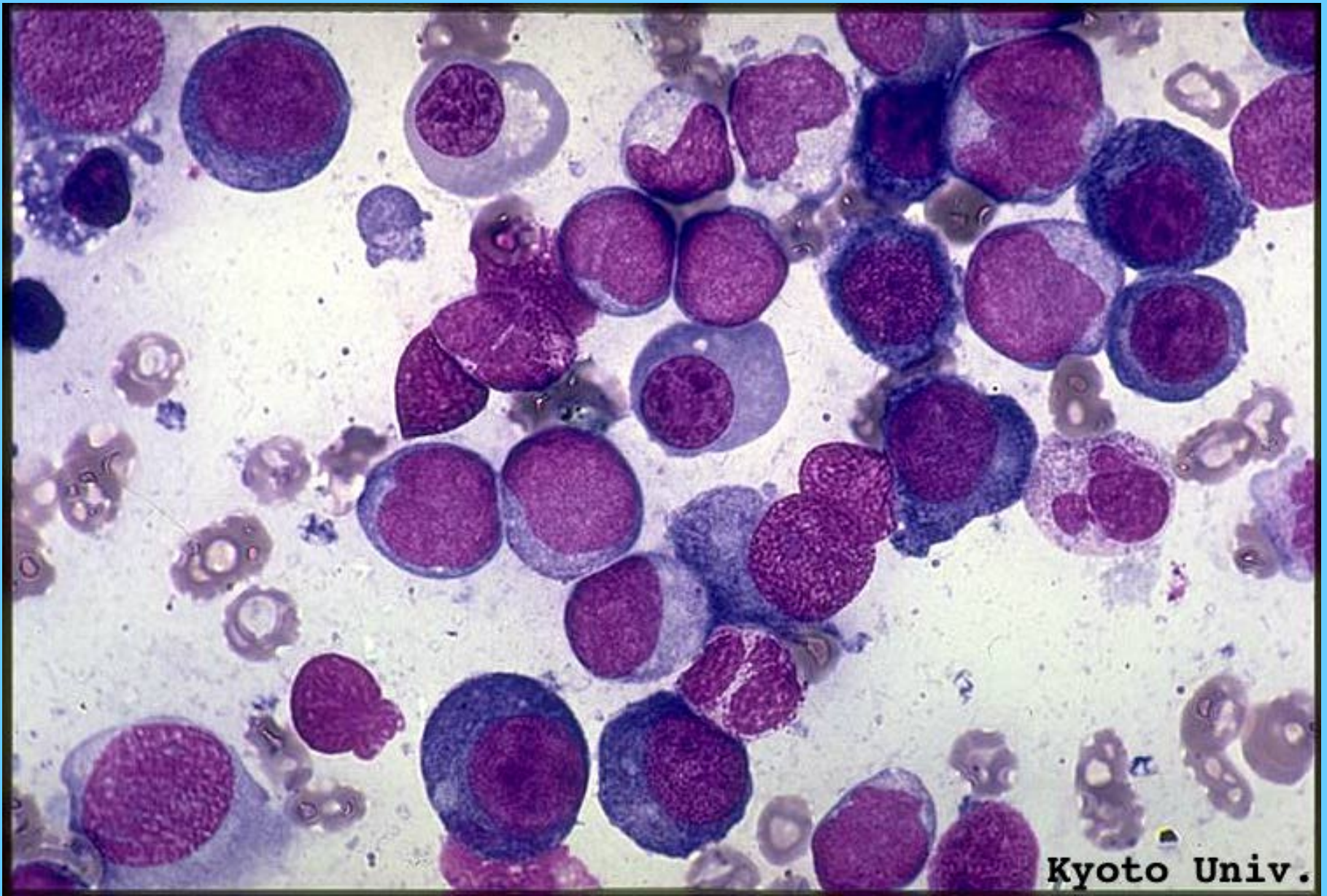

M6

Nagasaki Univ.

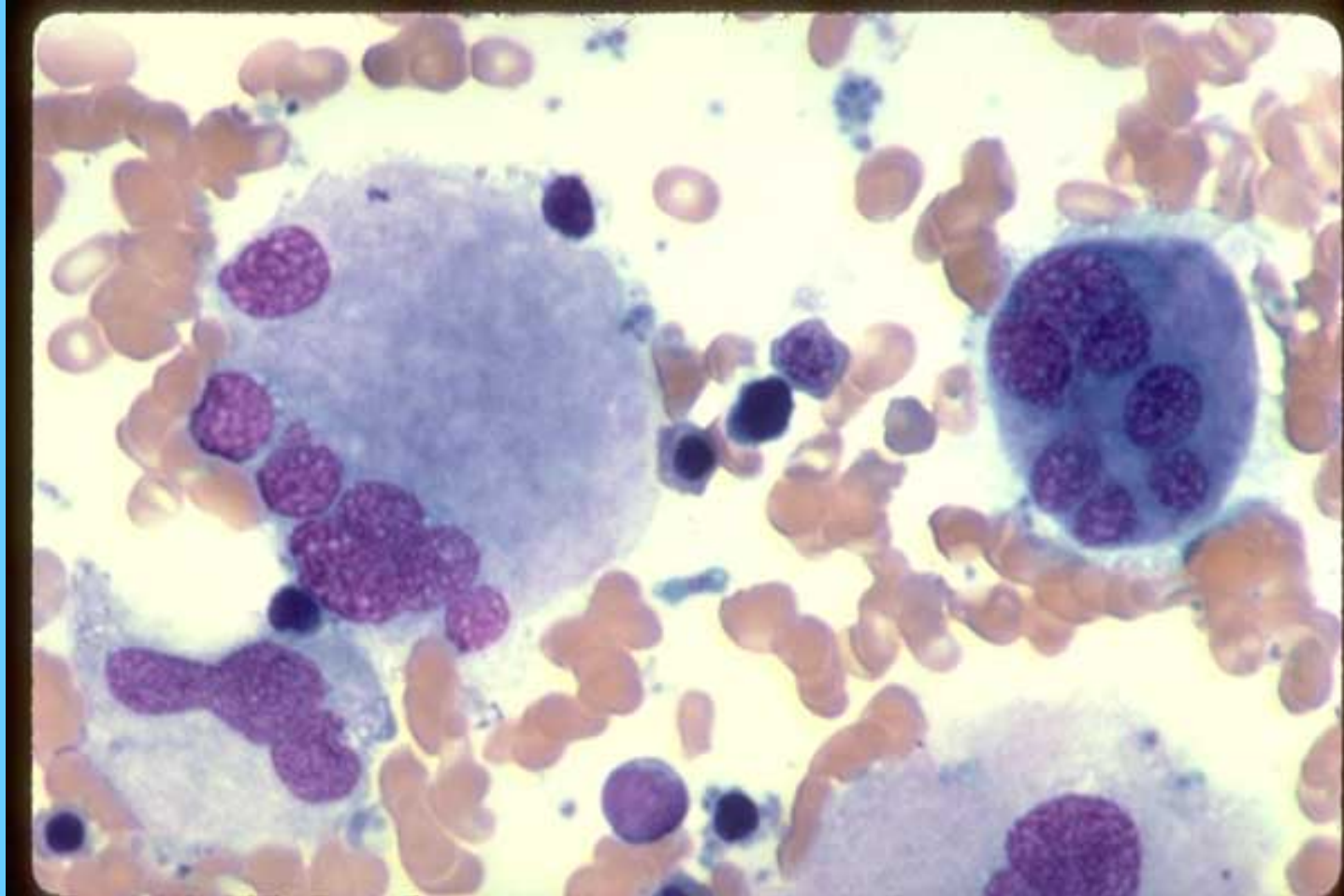


M6

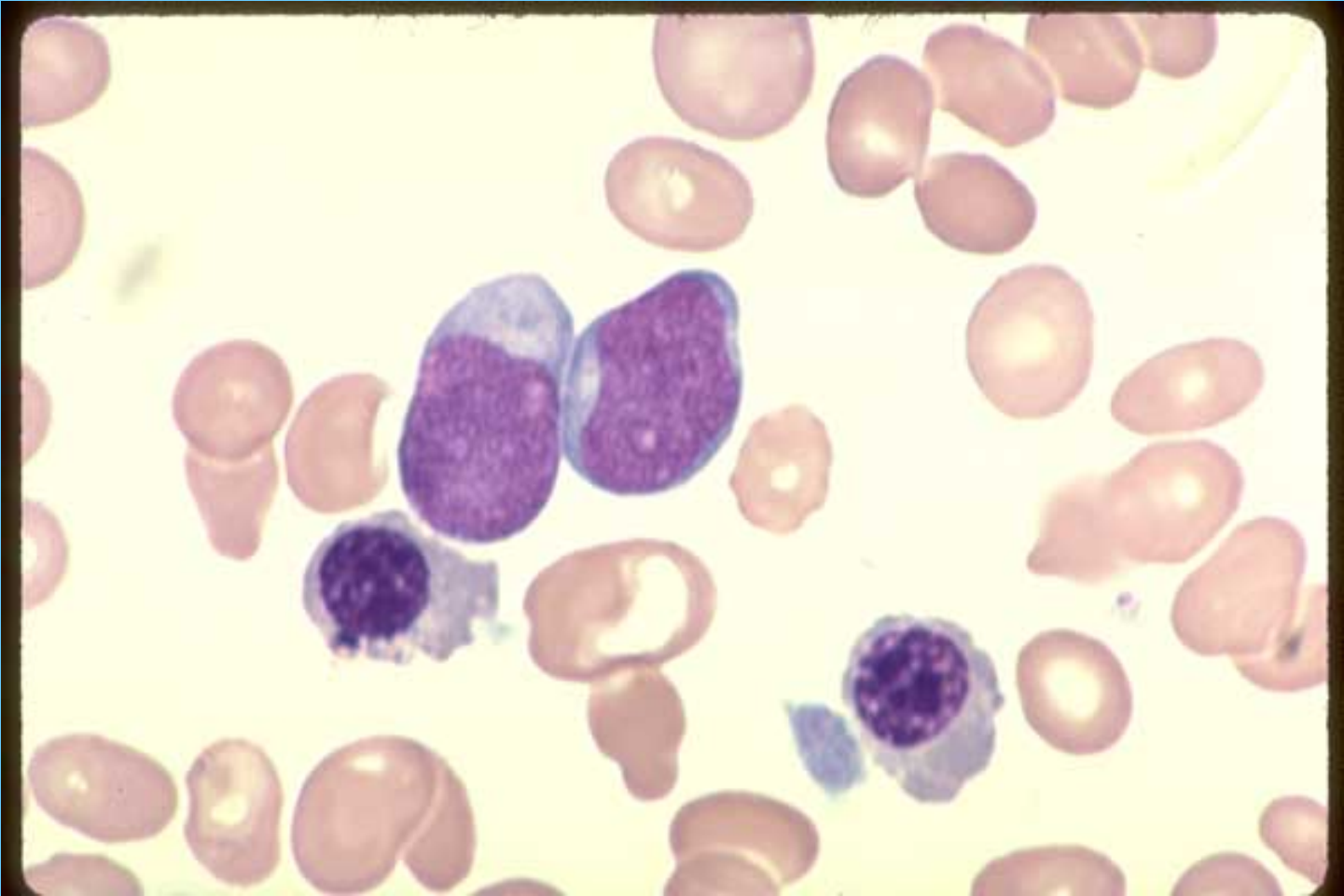


Kyoto Univ.

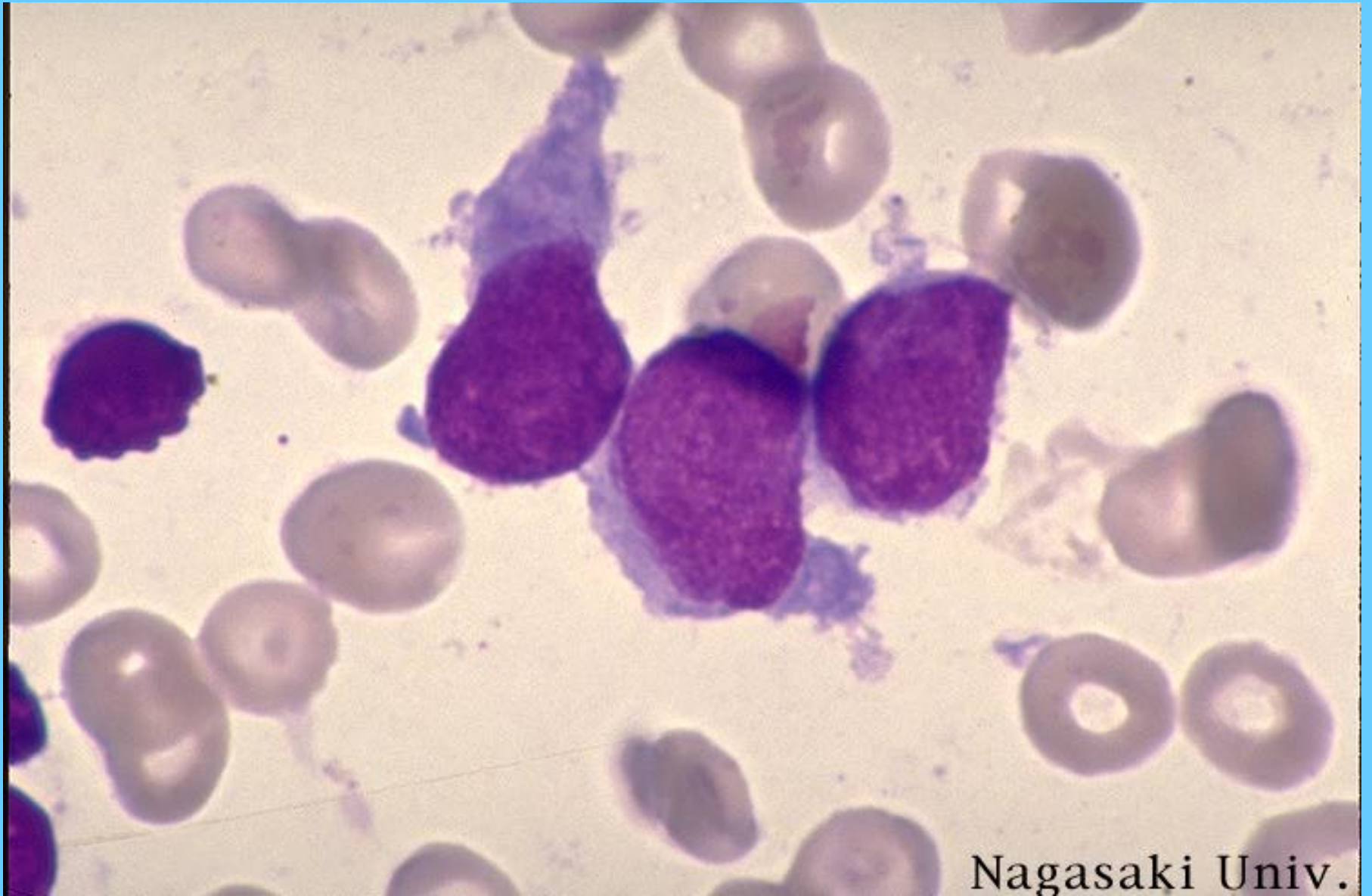
M7, MEGACARIOCITOS MADUROS ANORMALES



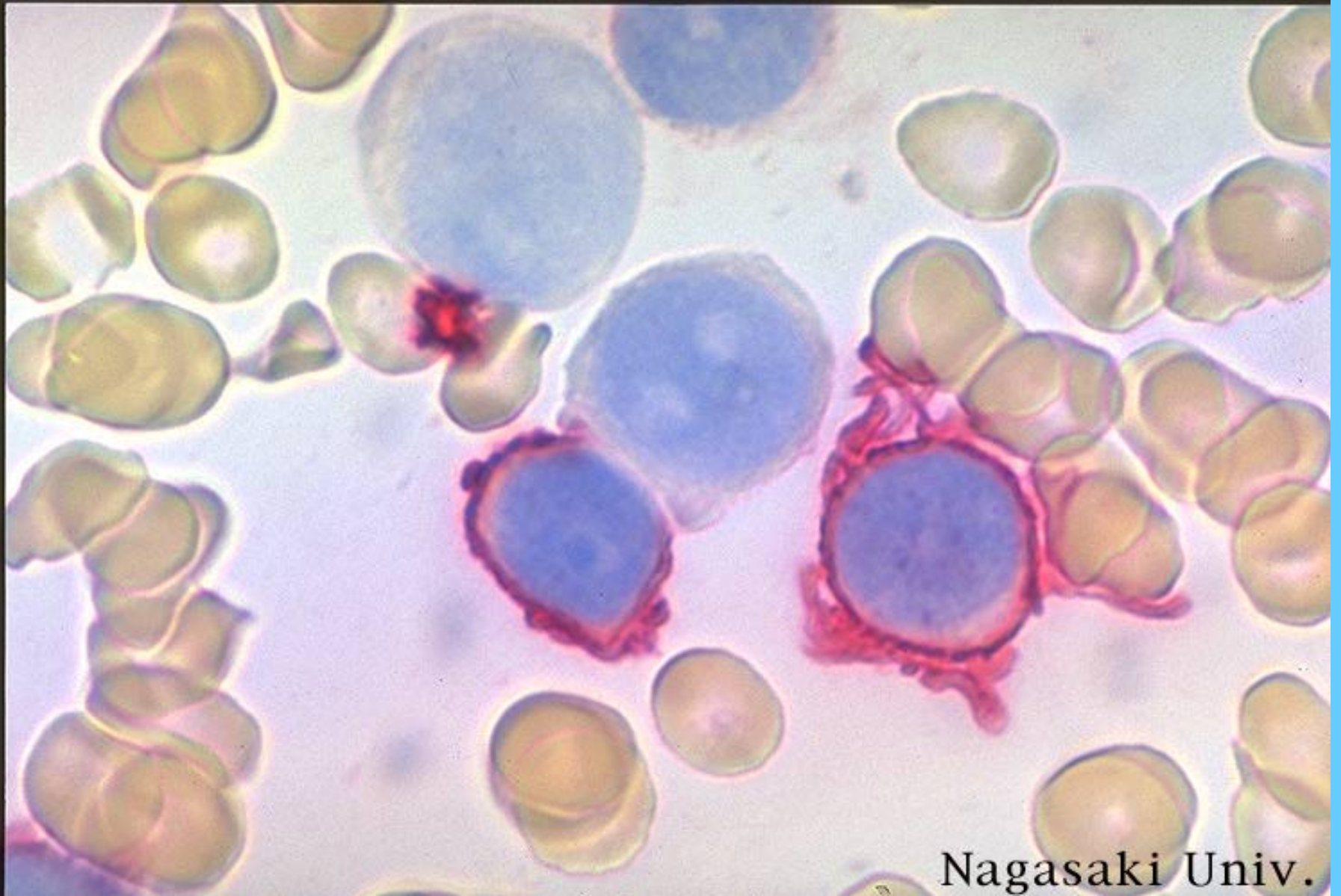
M7, M.O.



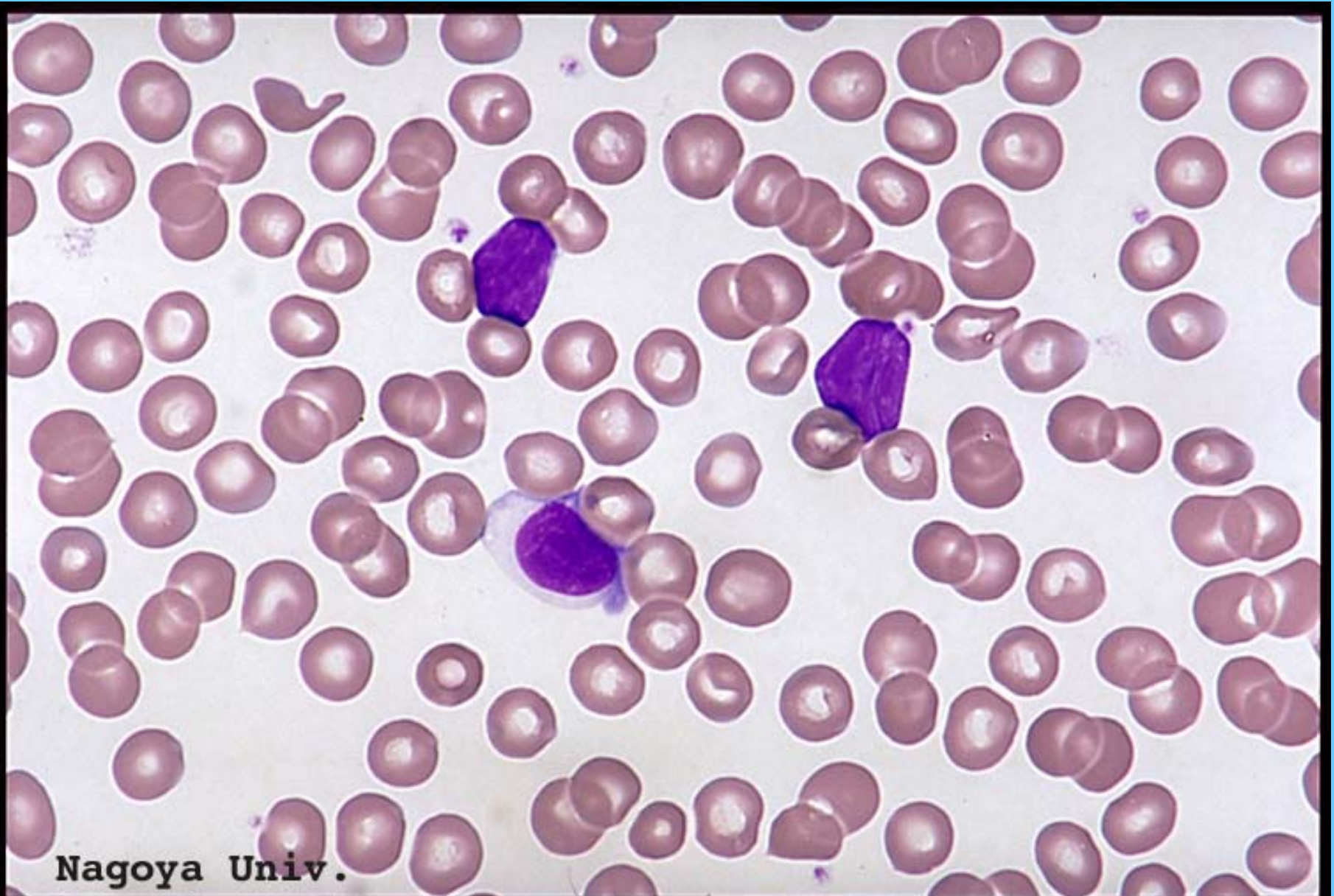M7



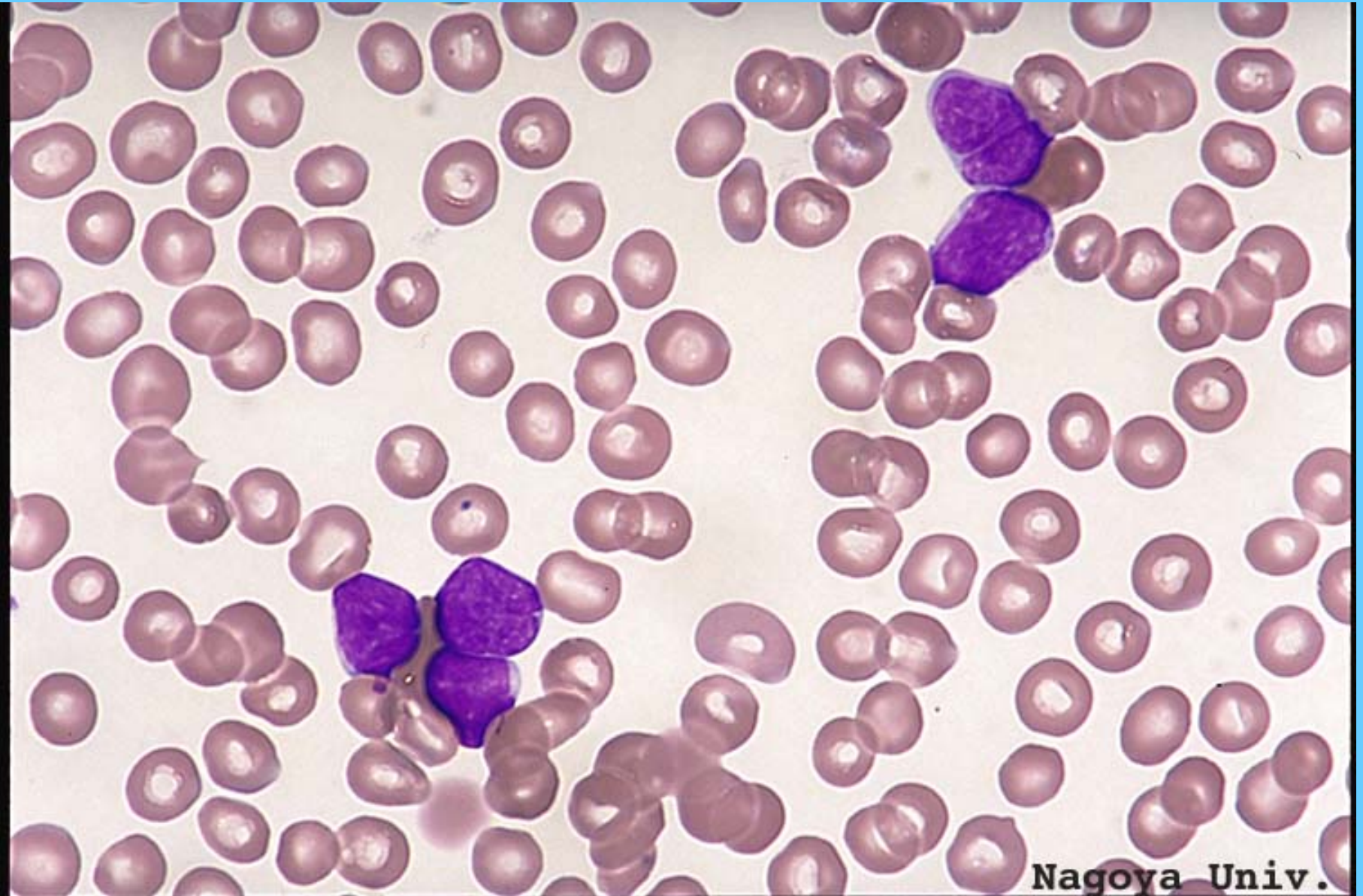
M7, M.O. TINCIÓN CON CD41



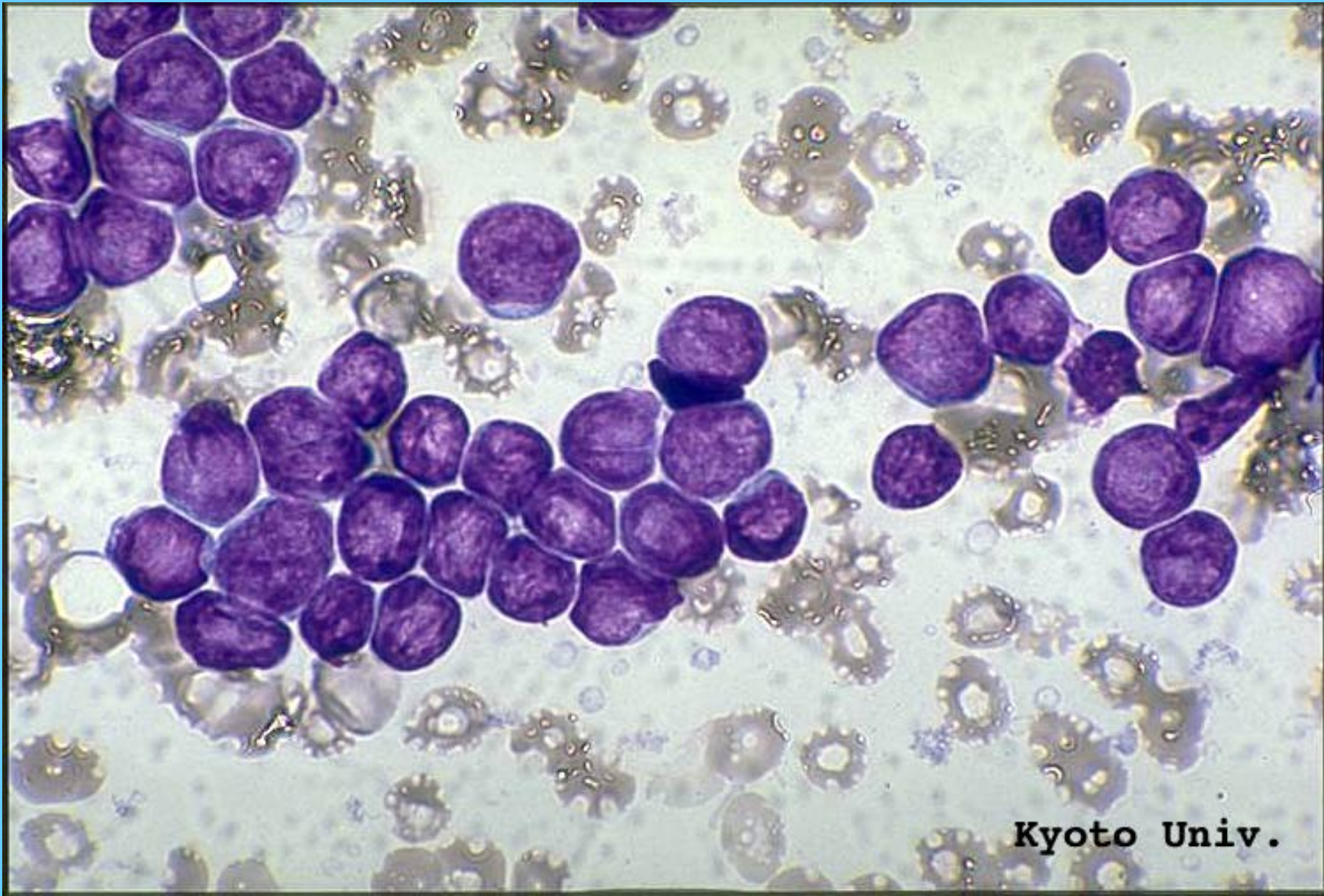
L1, SANGRE PERIFÉRICA



L1 SANGRE PERIFÉRICA

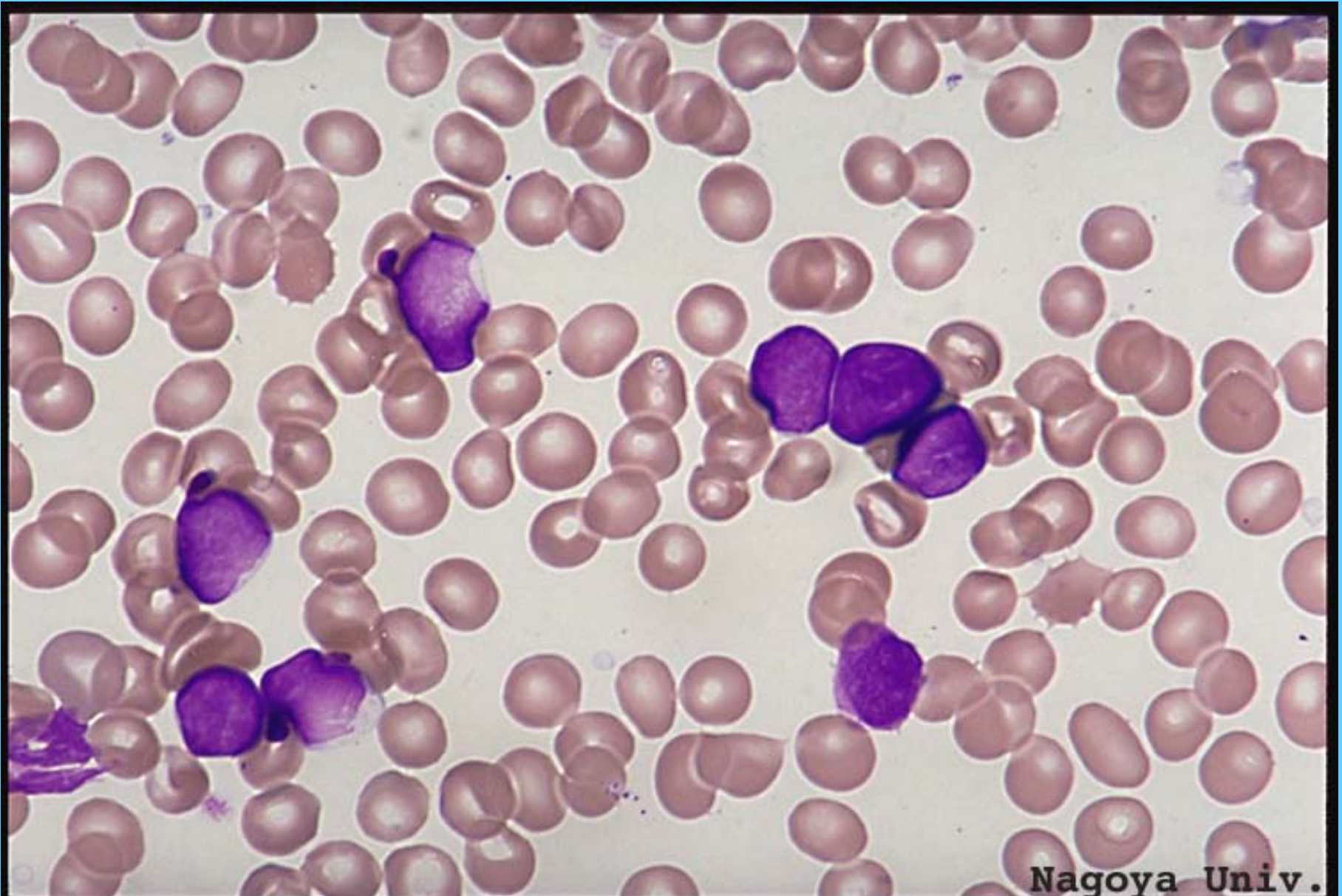

L1, M.O.

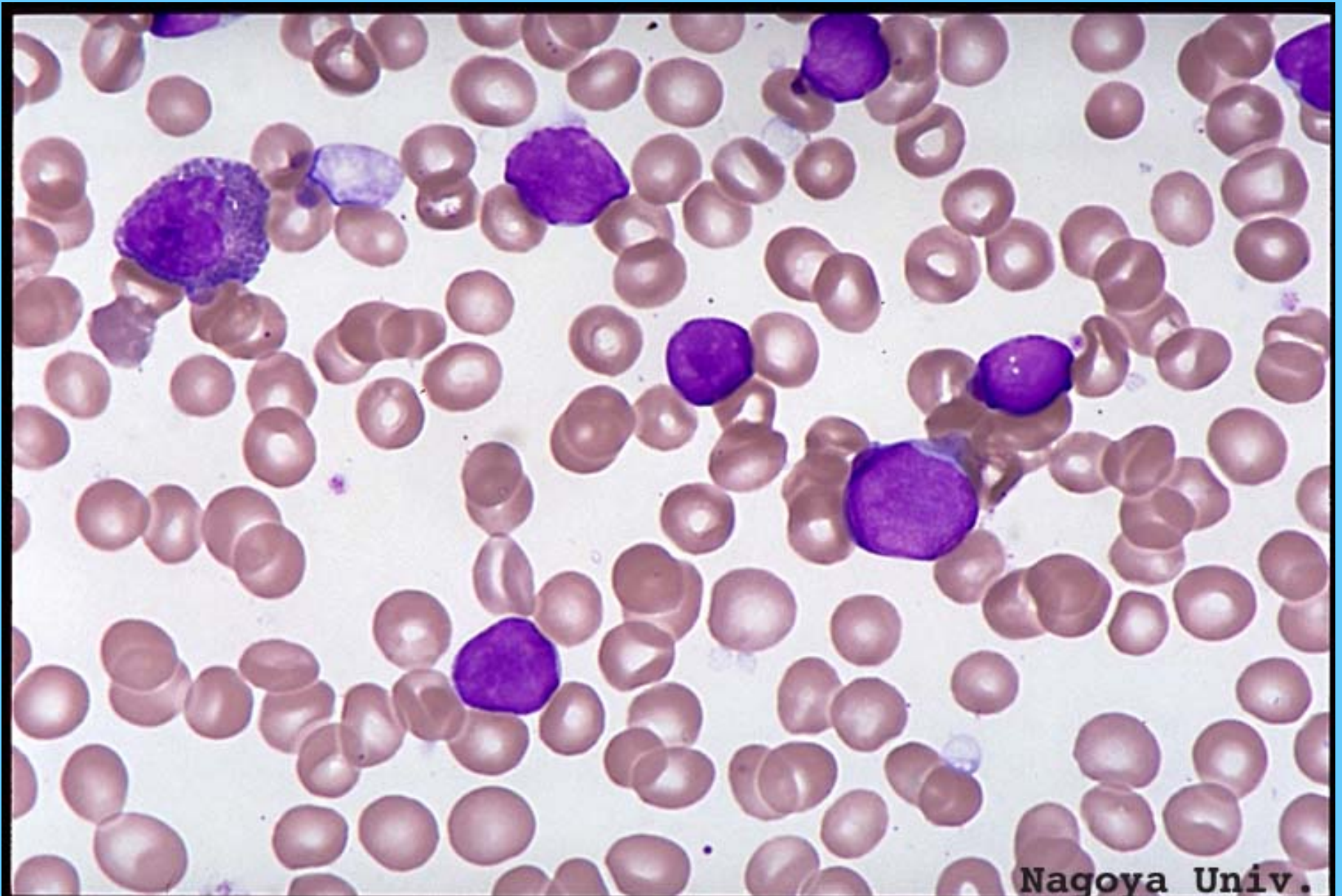


Kyoto Univ.

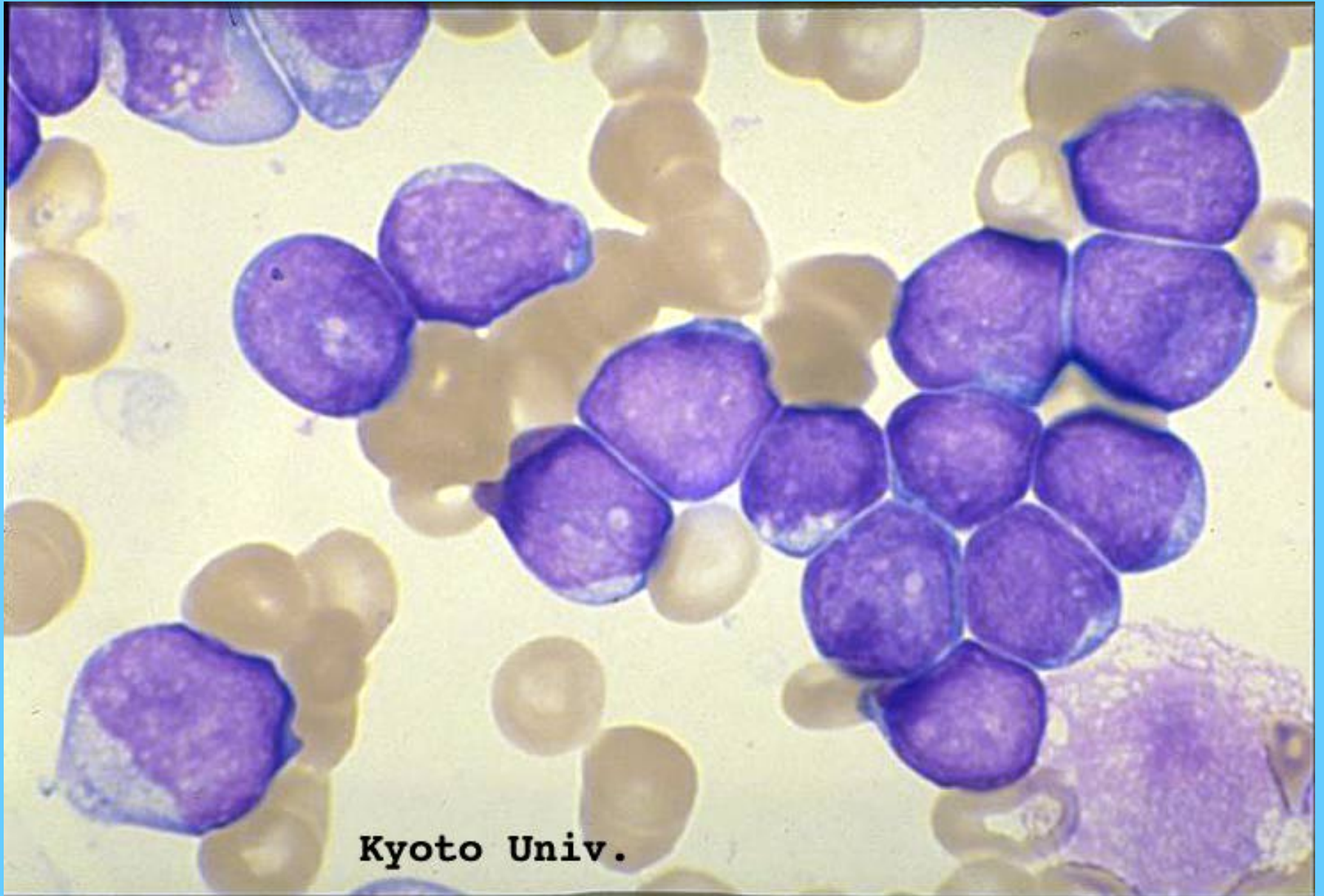
L1



L1

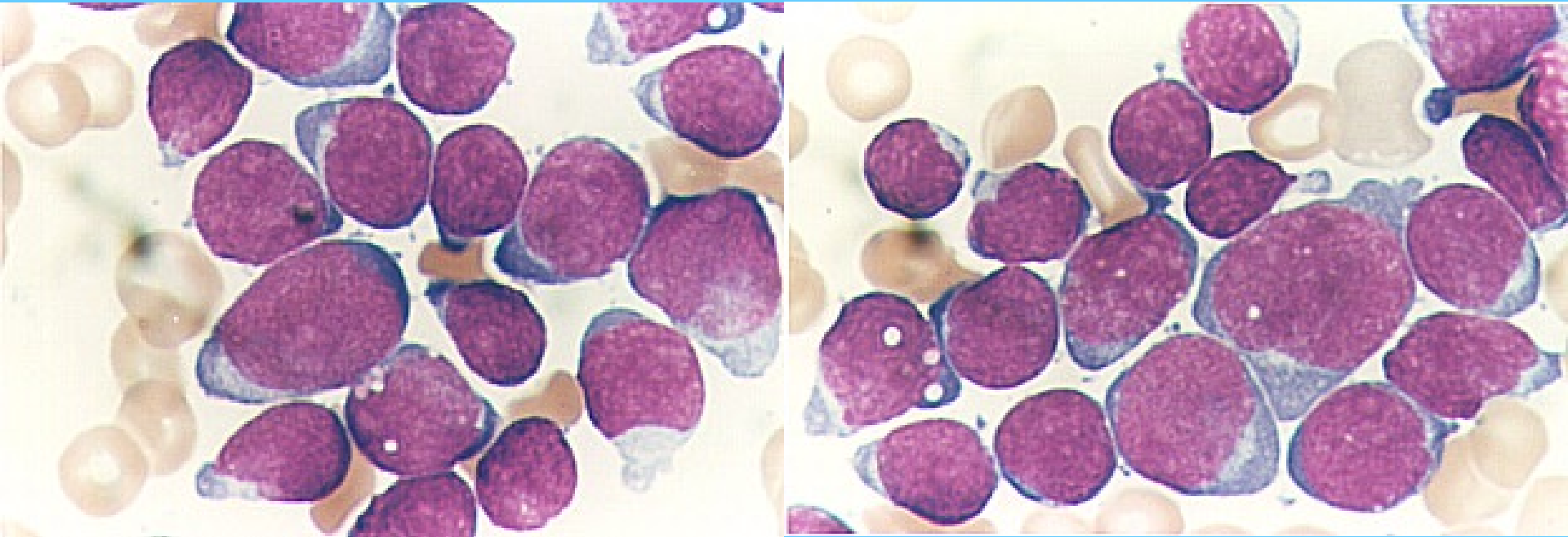


LI

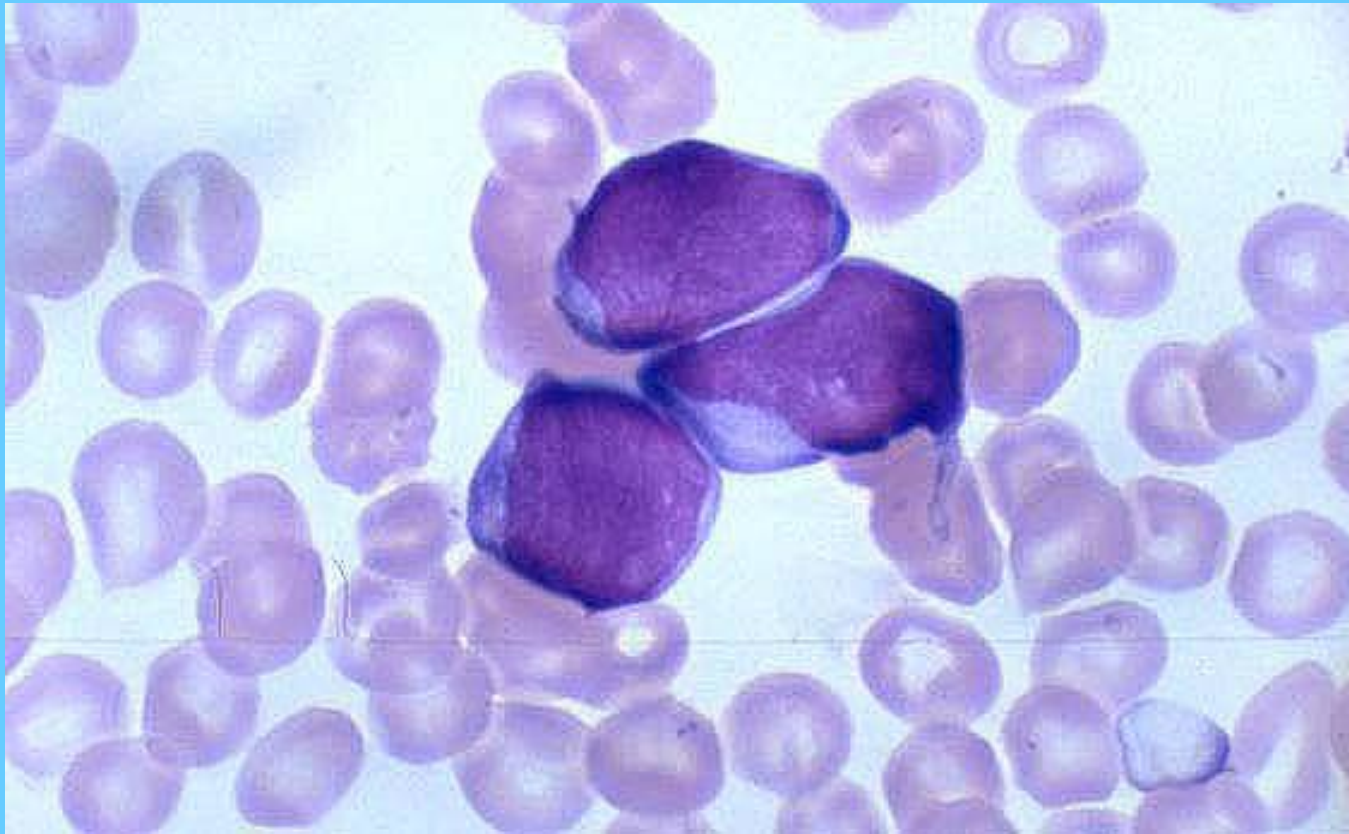


Kyoto Univ.

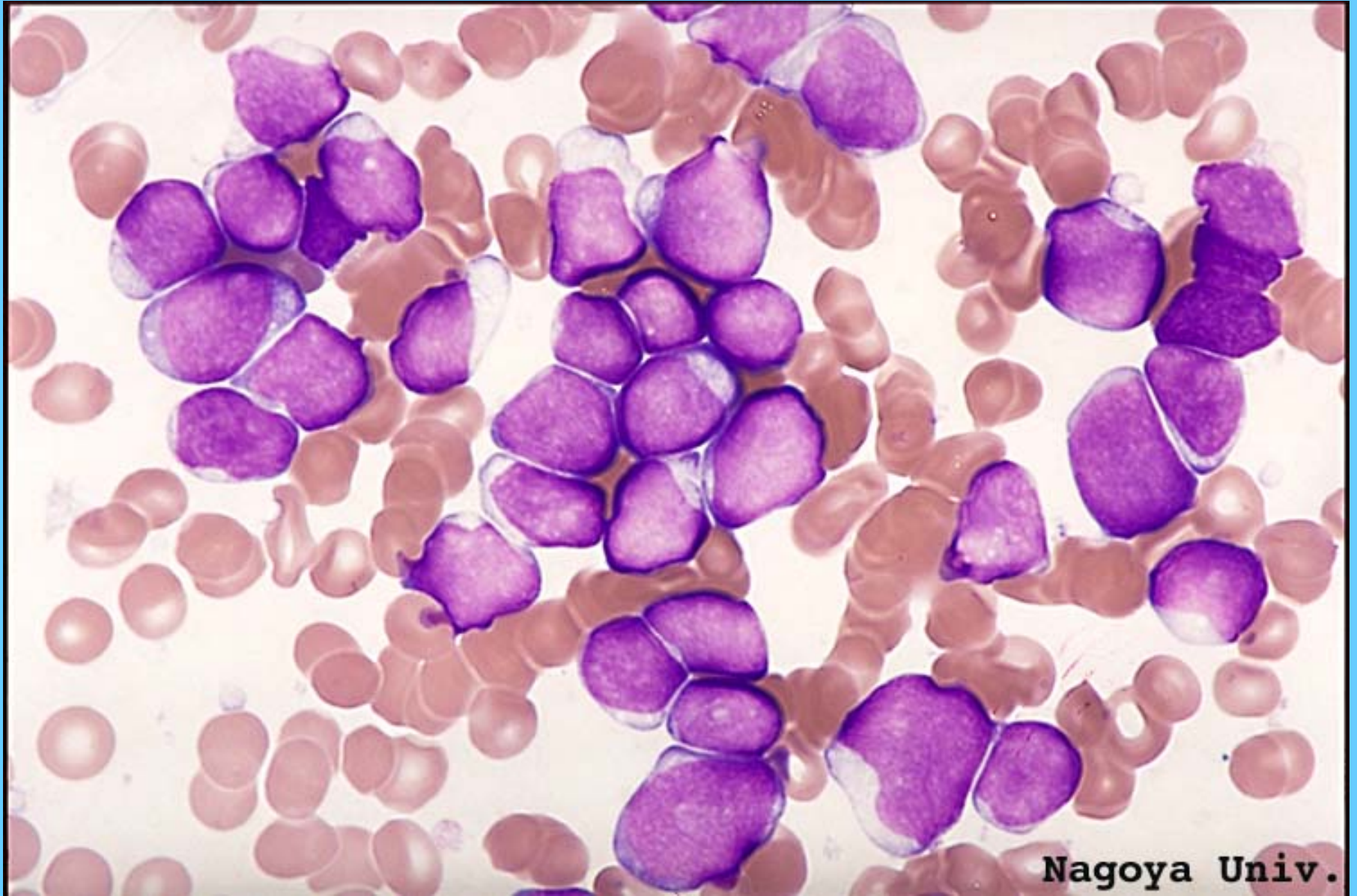
L2



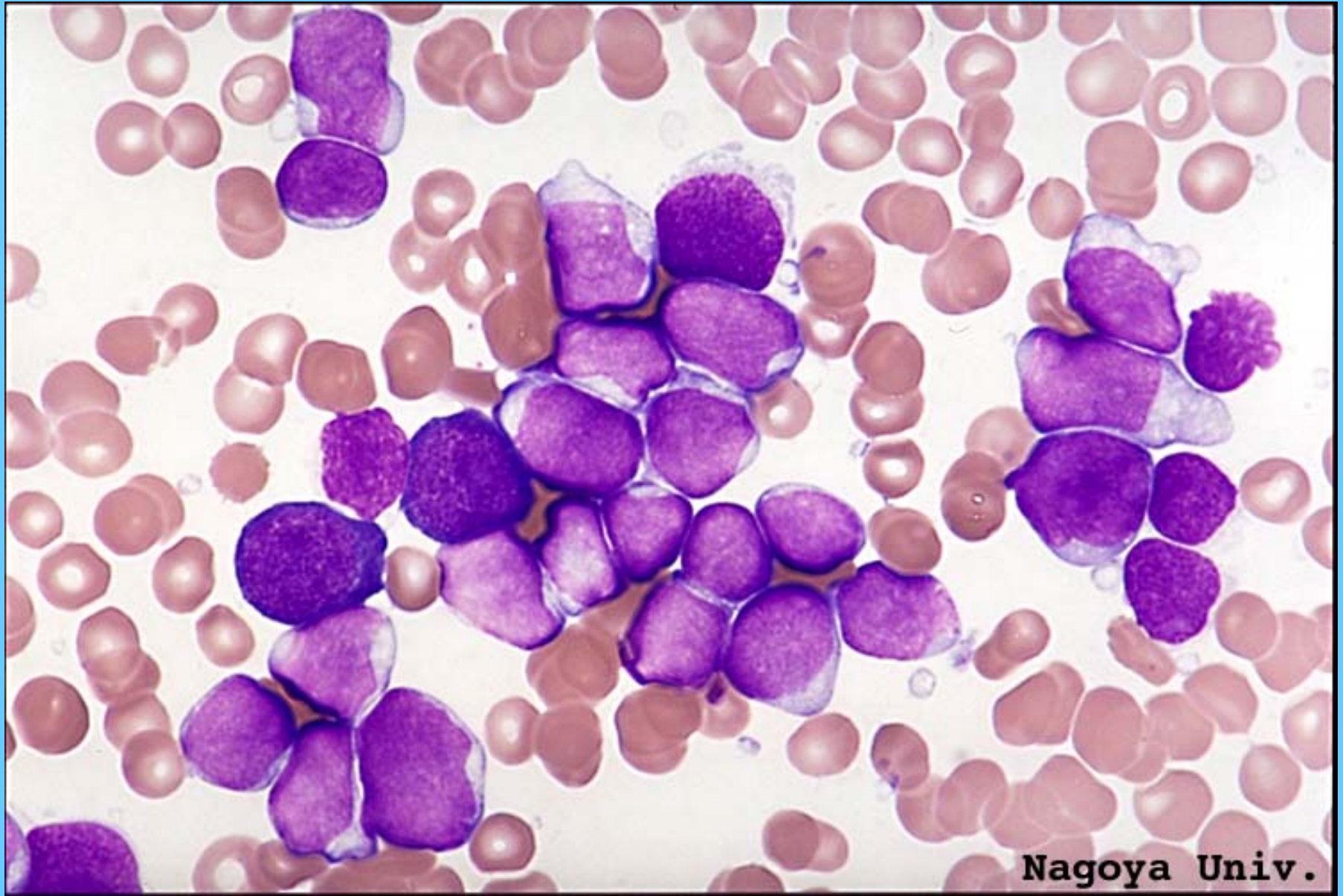
L2



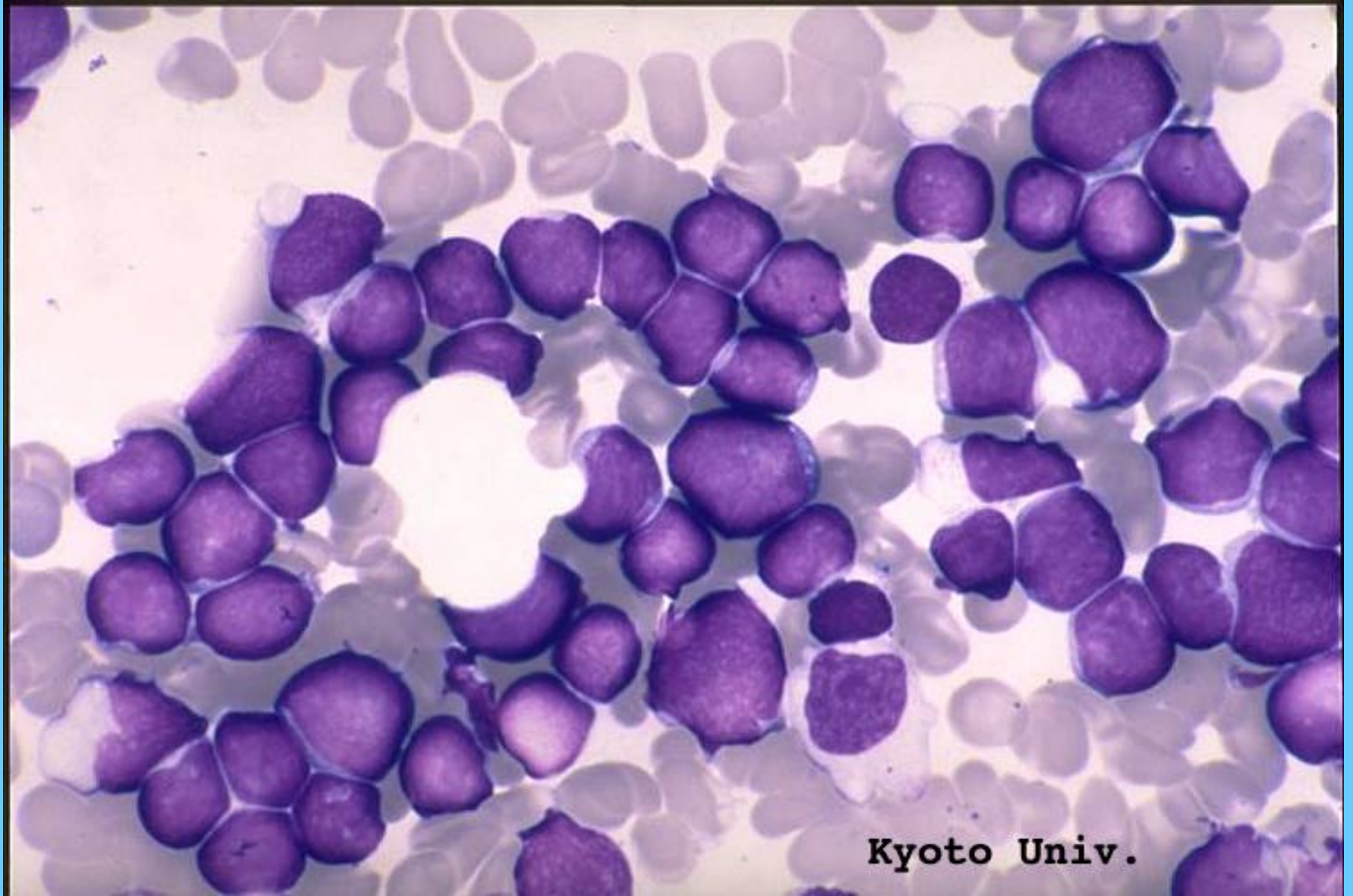
L2



L2

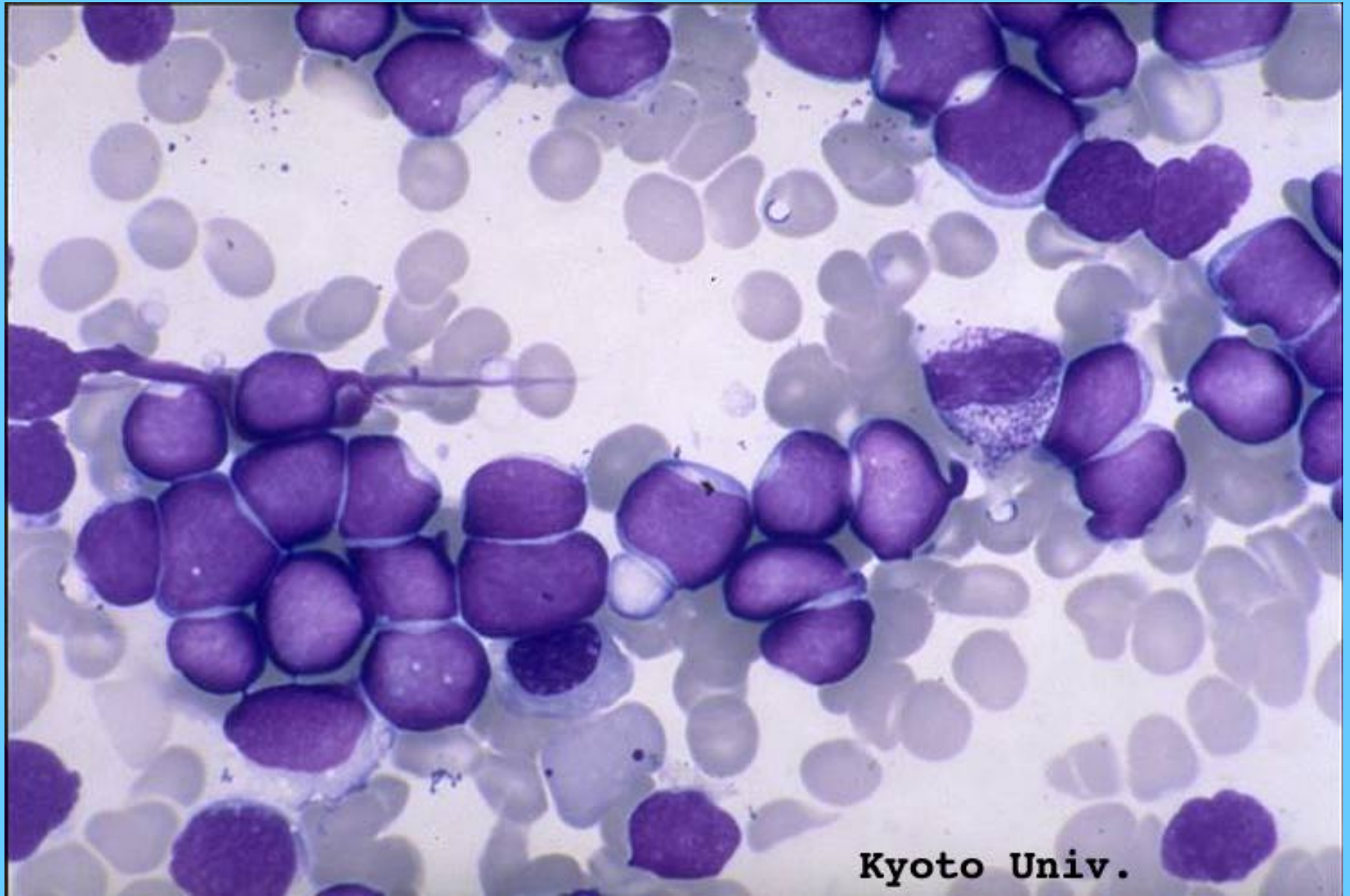


L2



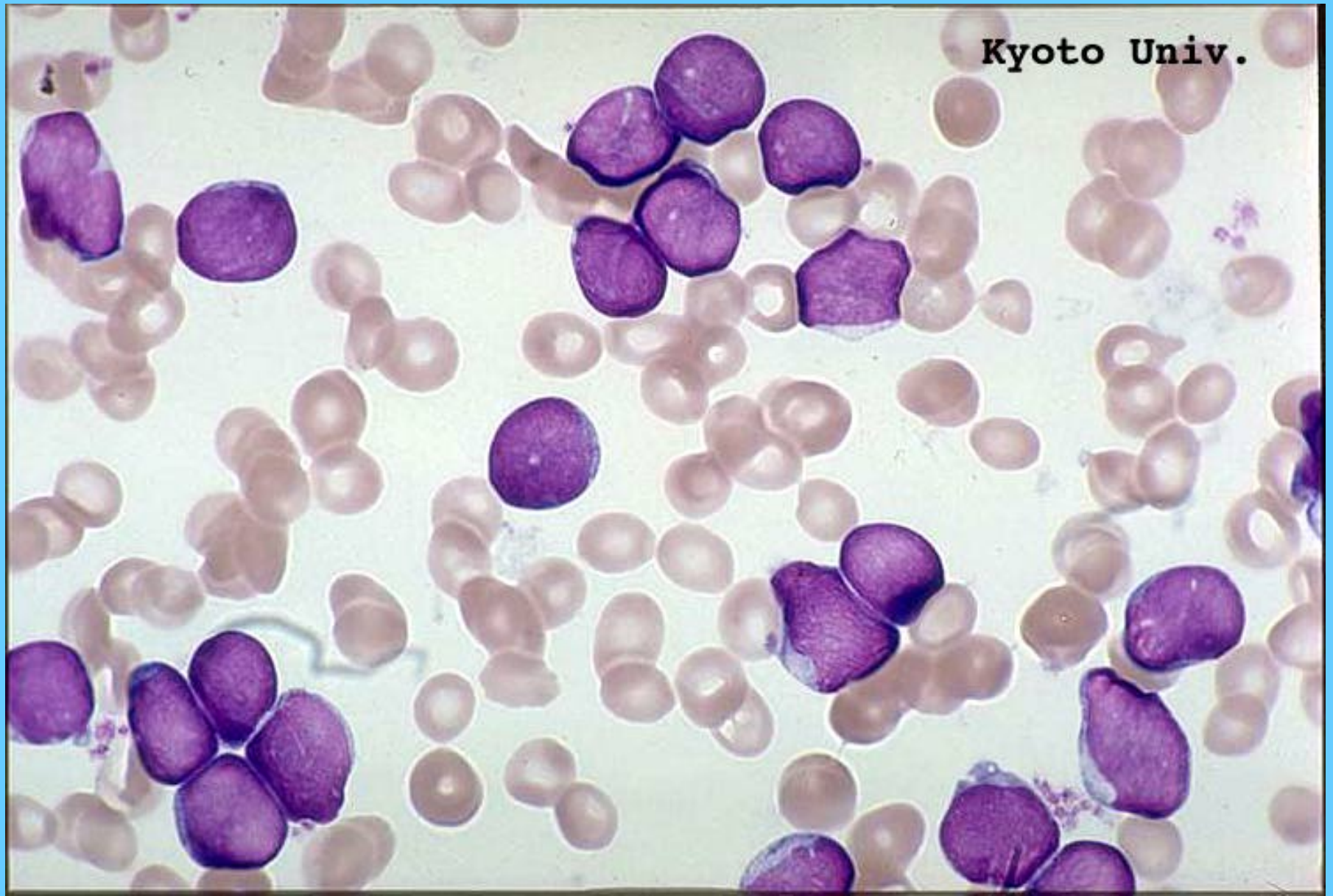
Kyoto Univ.

L2

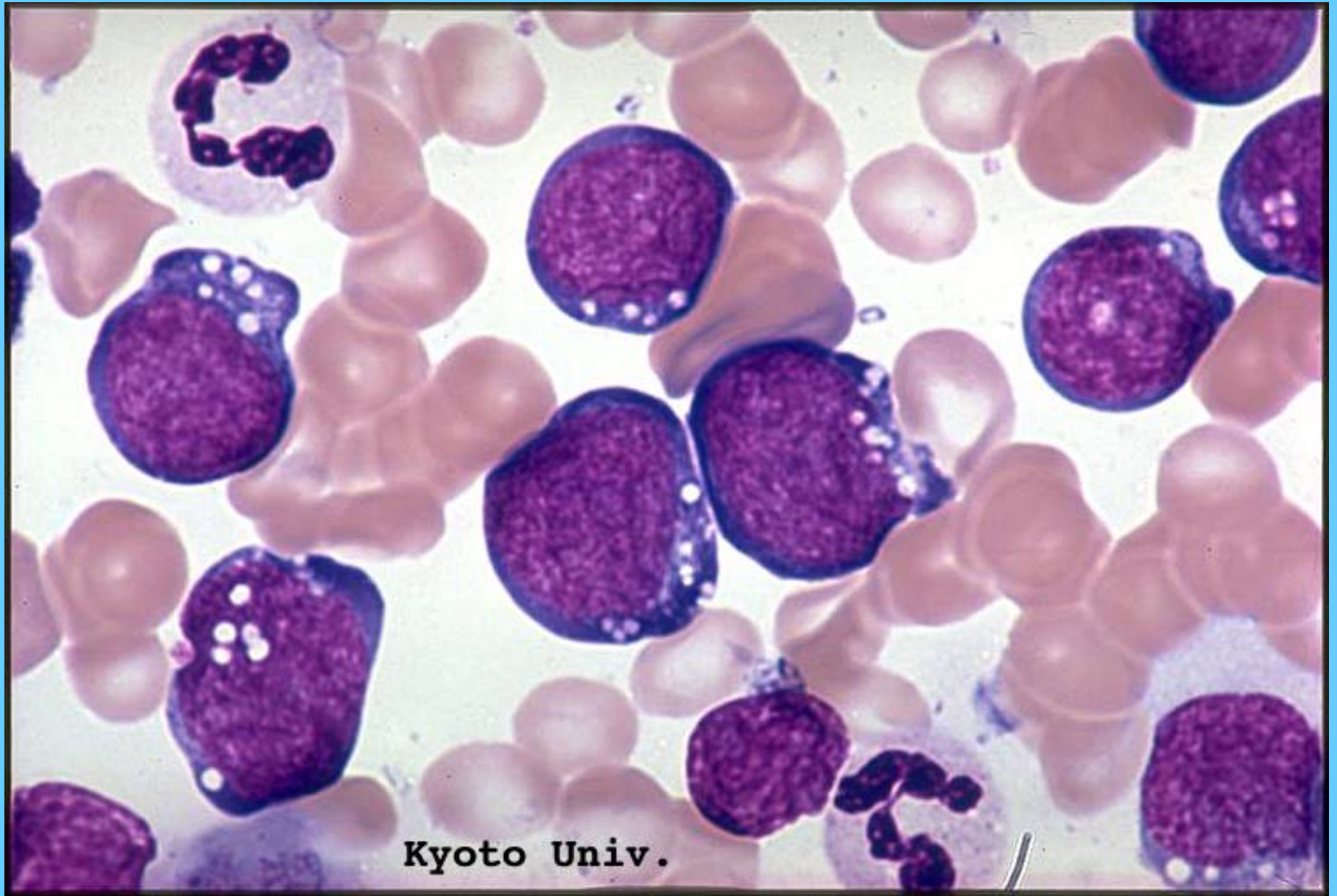


Kyoto Univ.

L2

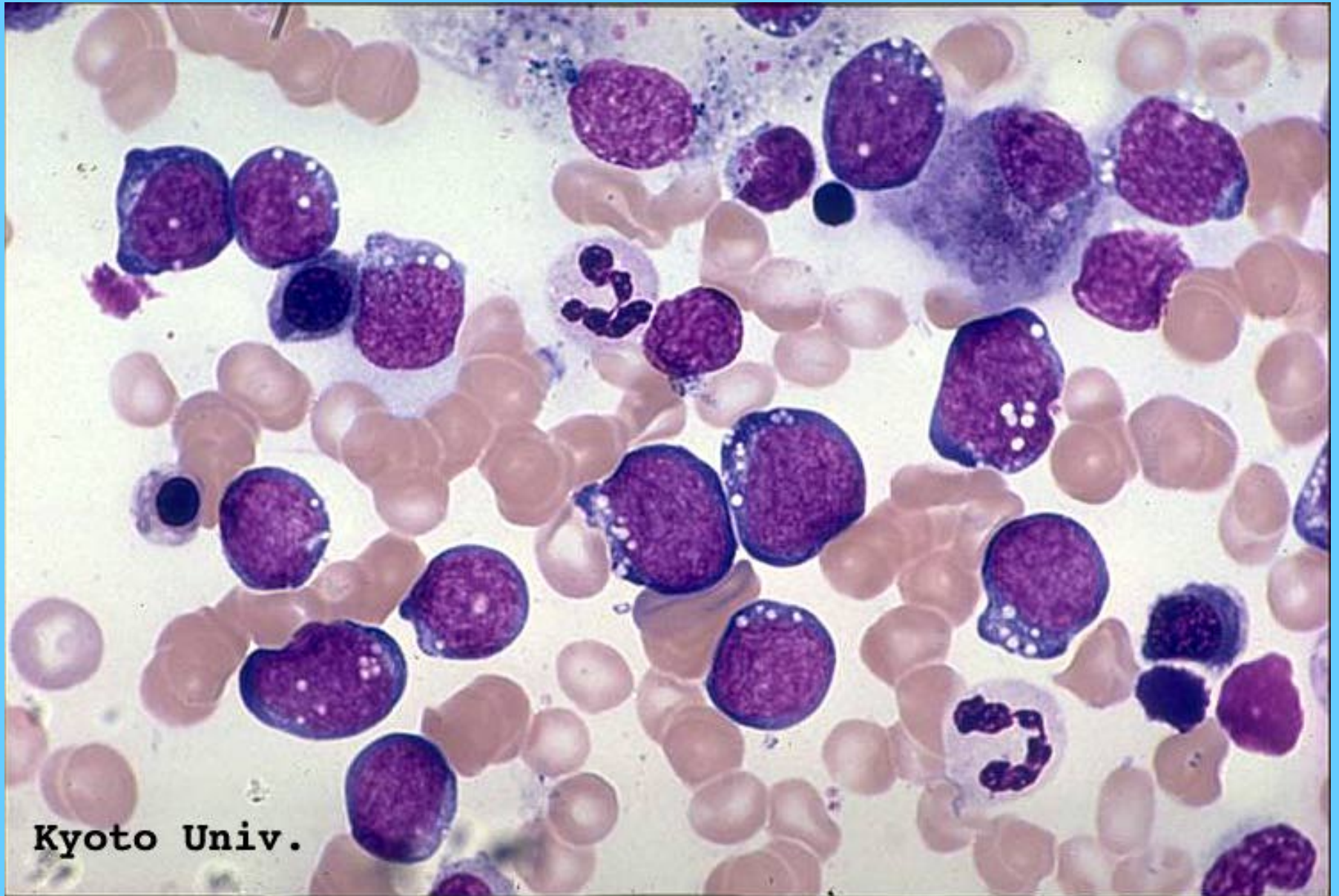


L3



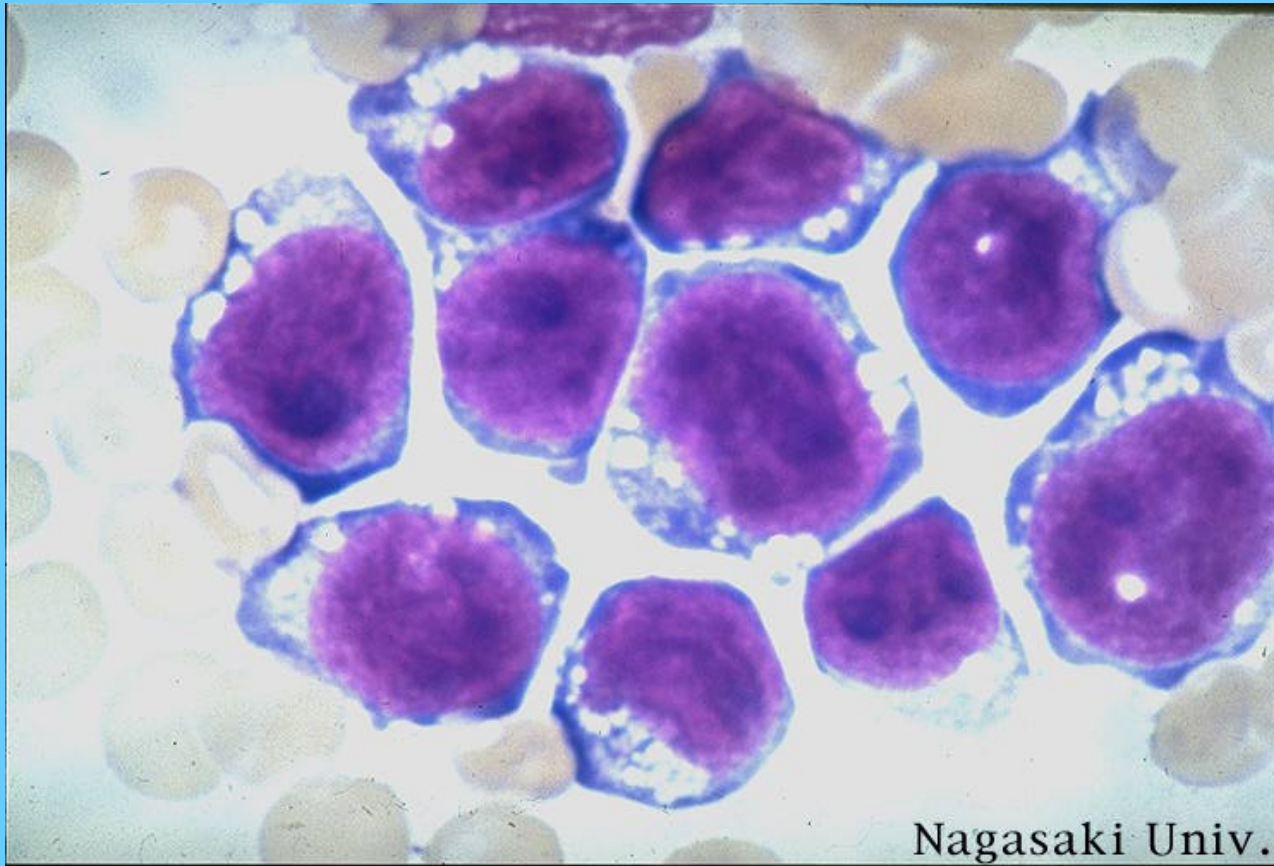
Kyoto Univ.

L3



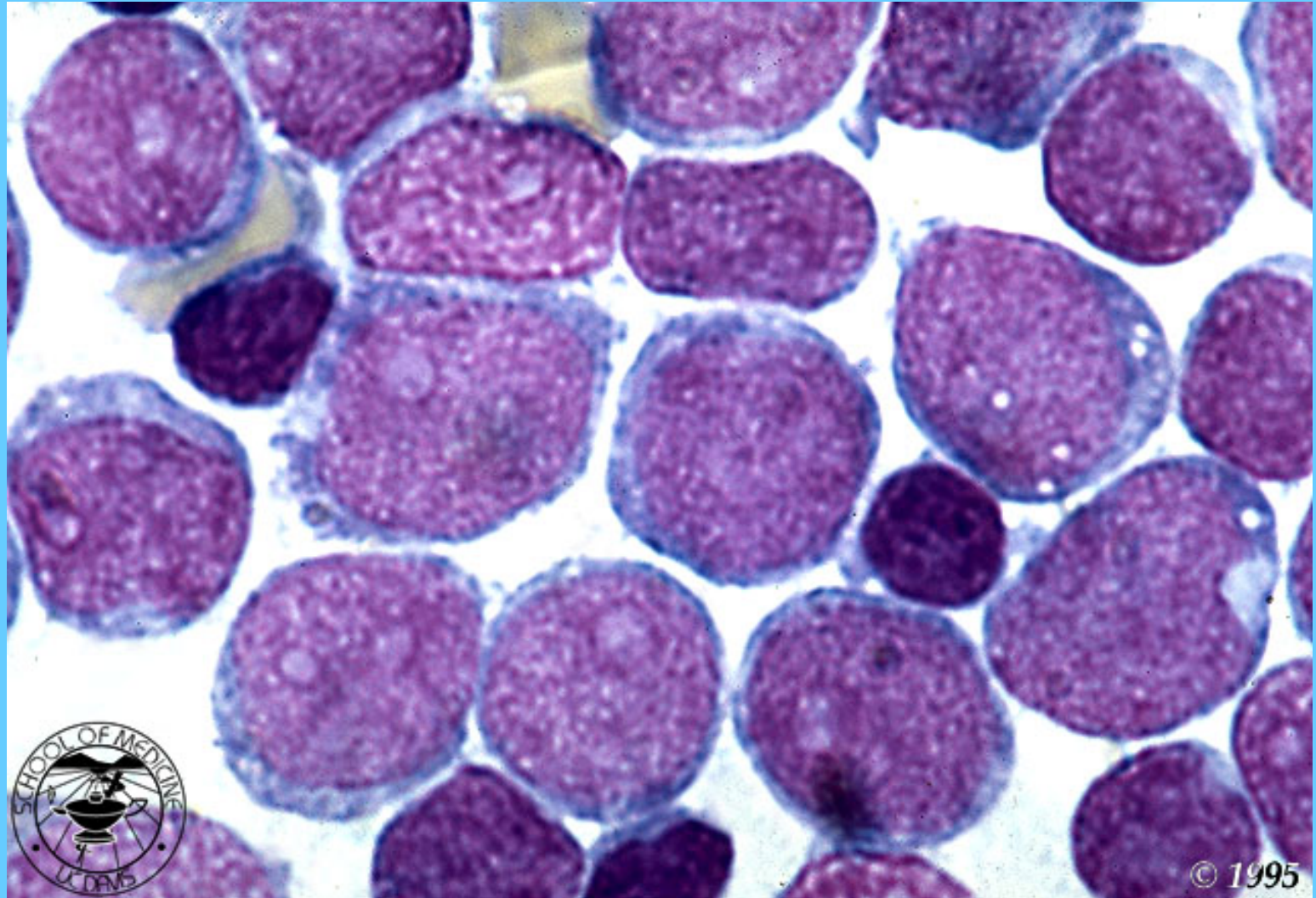
Kyoto Univ.

L3

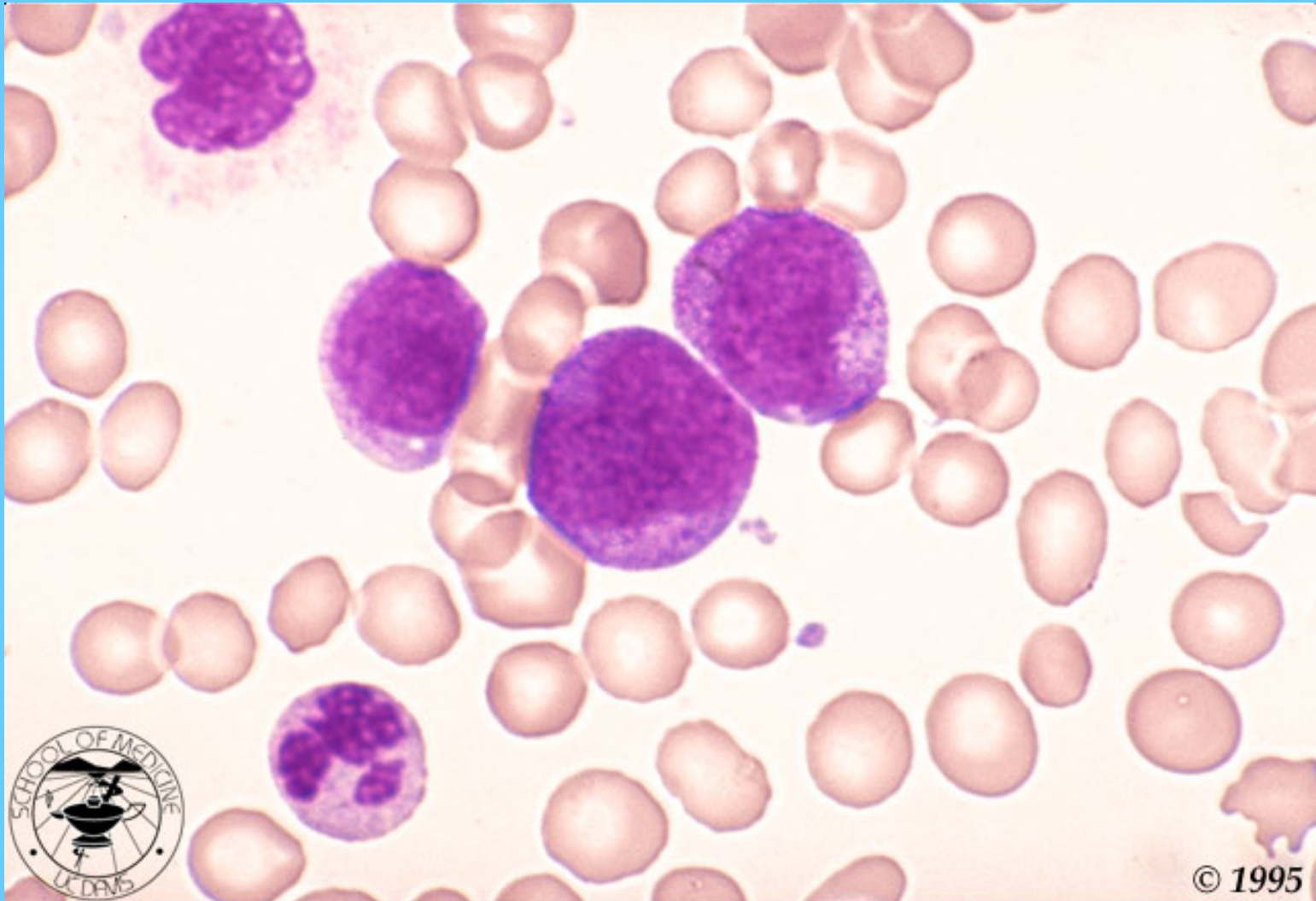


Nagasaki Univ.

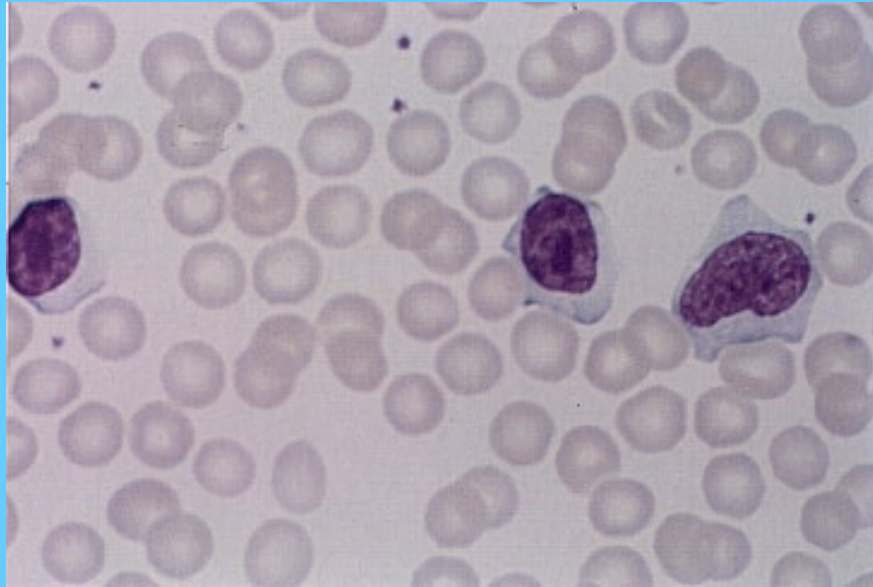M.O. HIPERCELULAR EN M1, LA MAYORIA SON MIELOBLASTOS



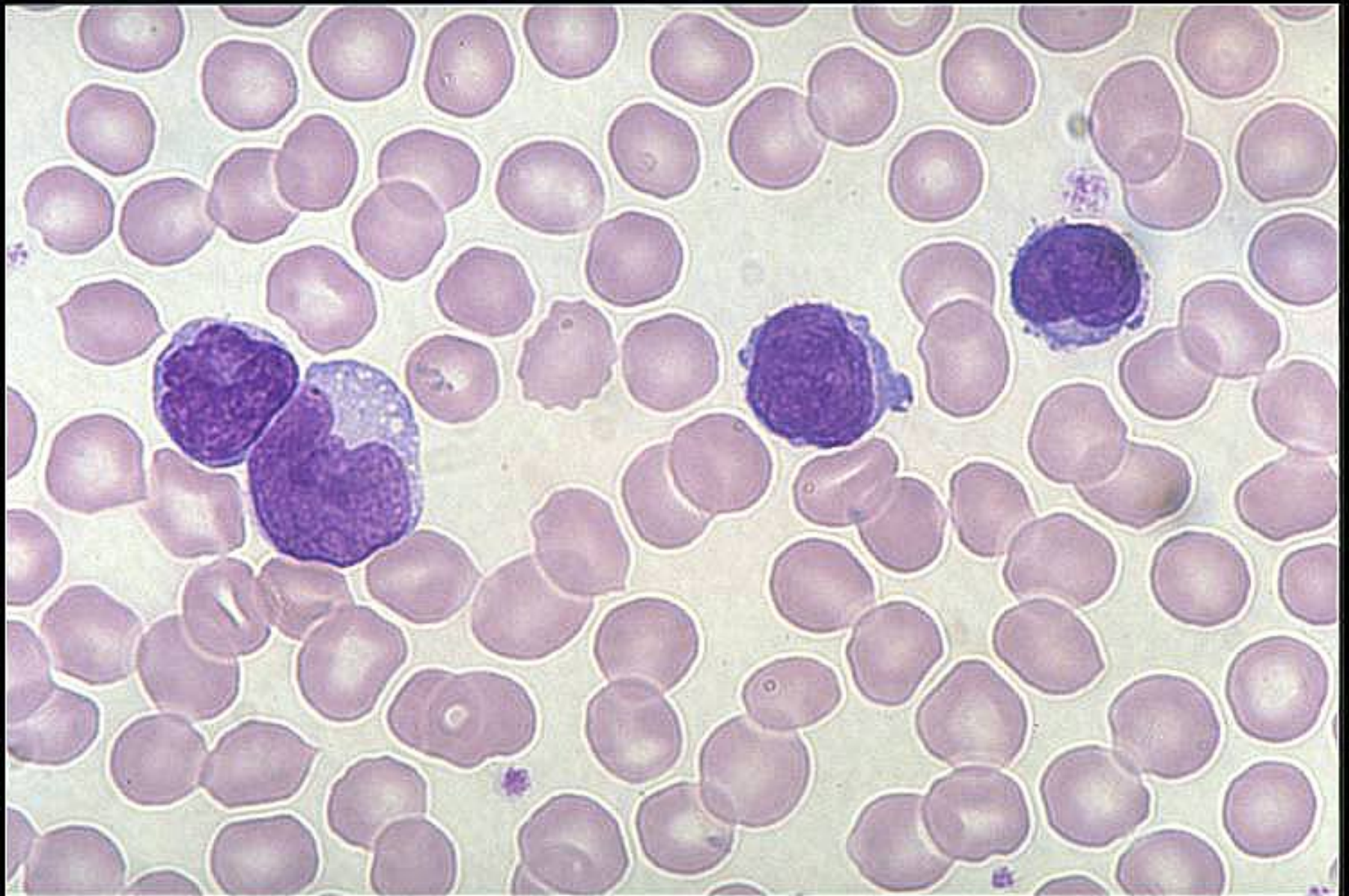PROMIELOCITOS EN M3



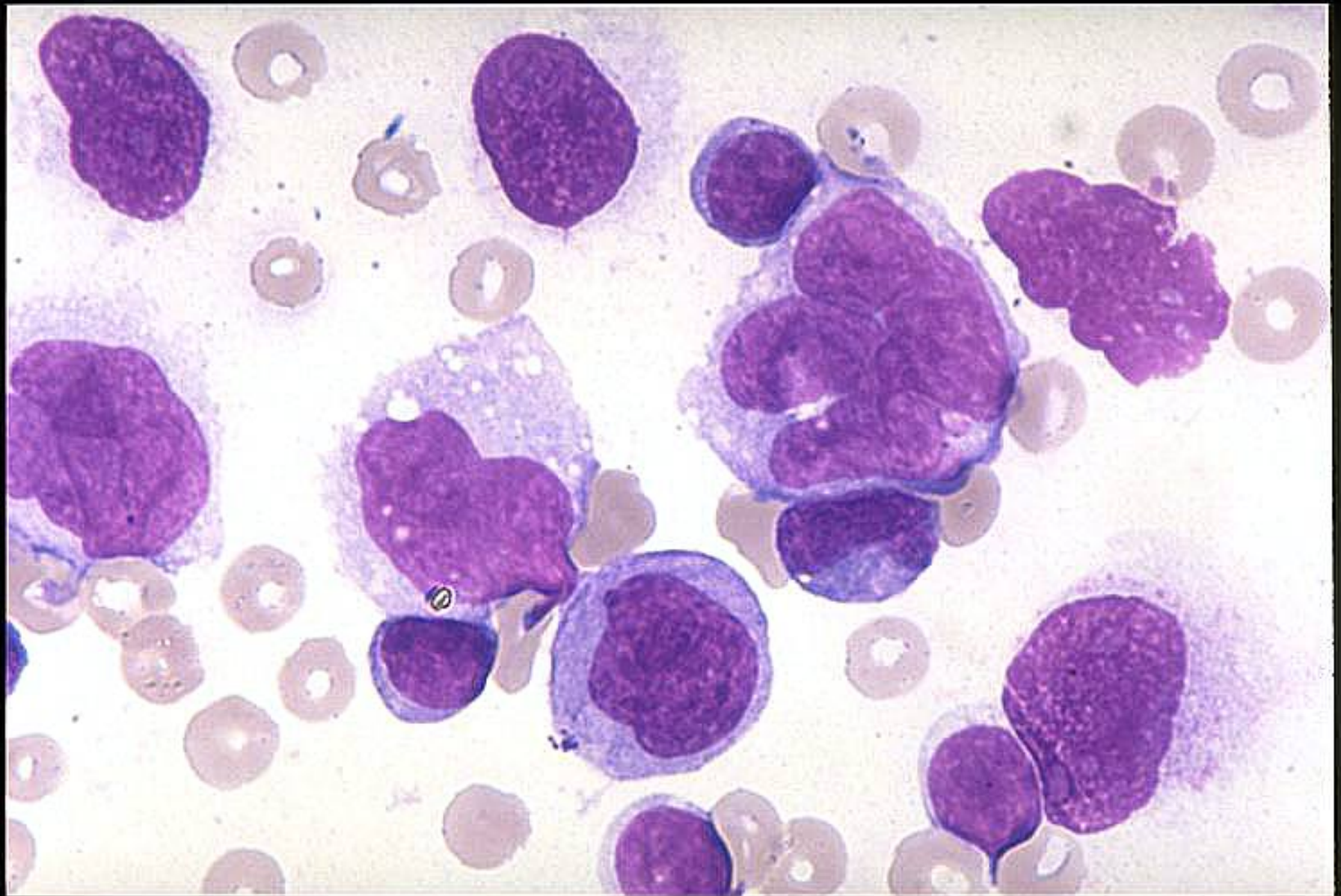
LLC



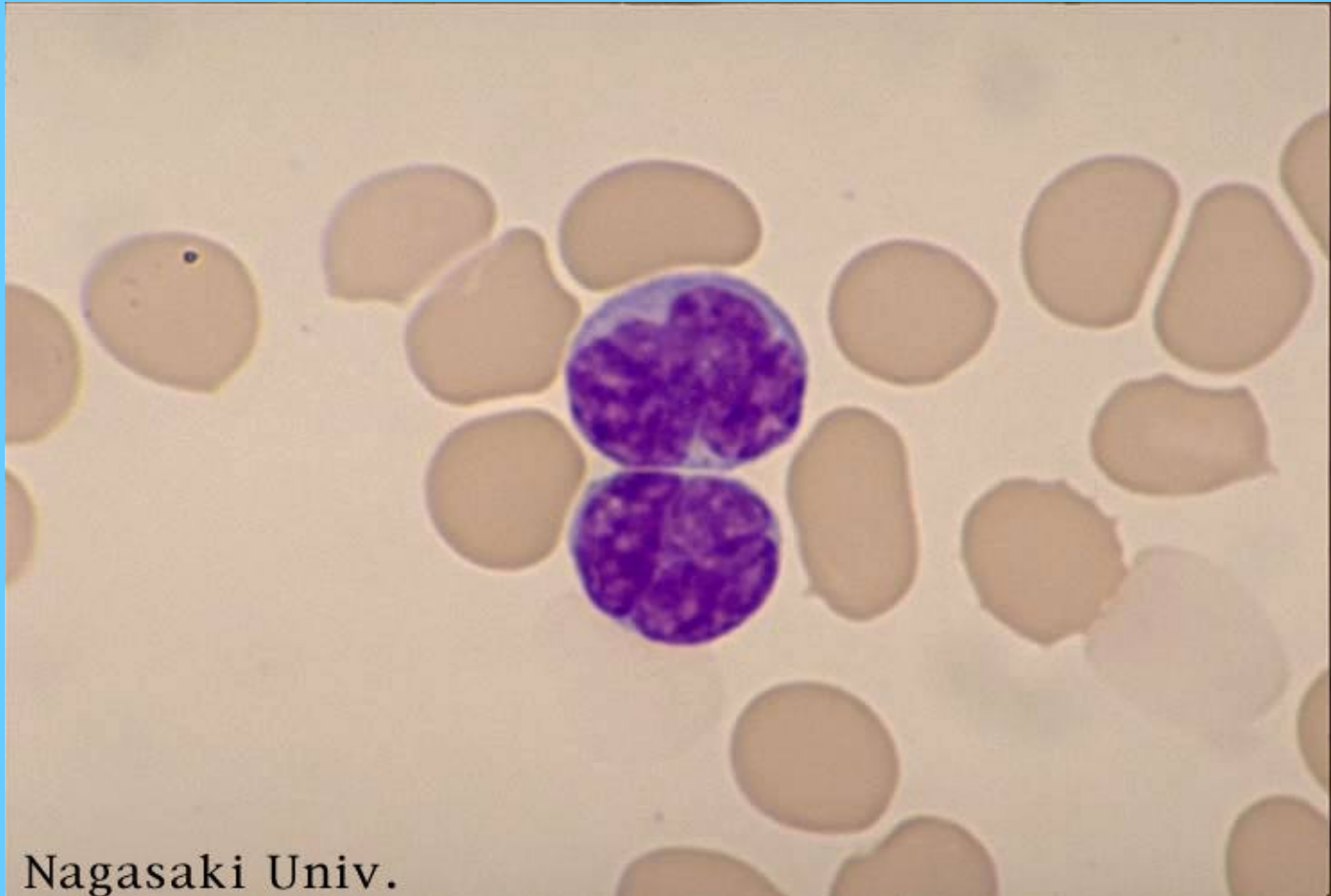
LEUCEMIA LINFOMA DE CELULAS T



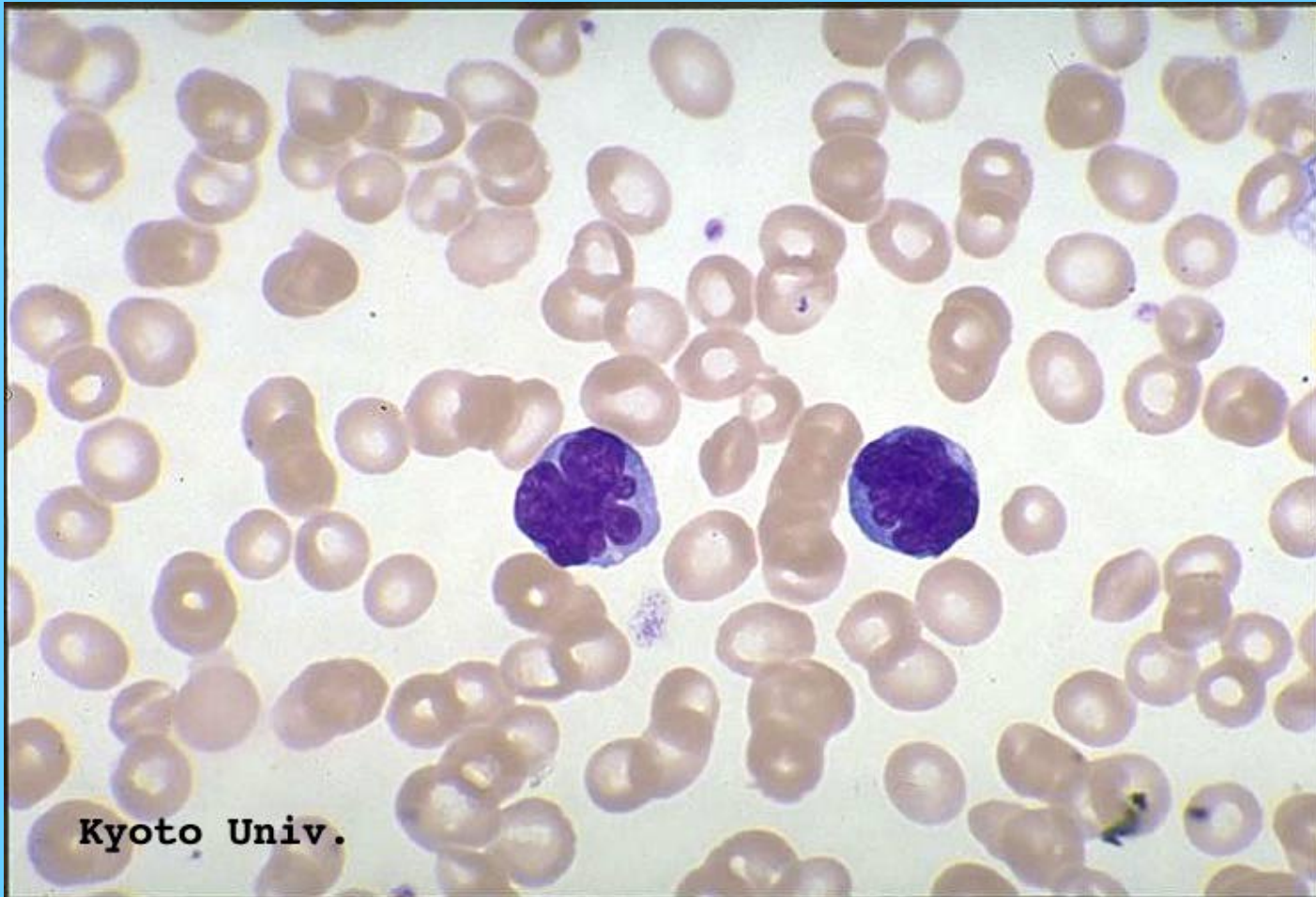
LINFOMA DE CELULAS T EN DERRAME PLEURAL



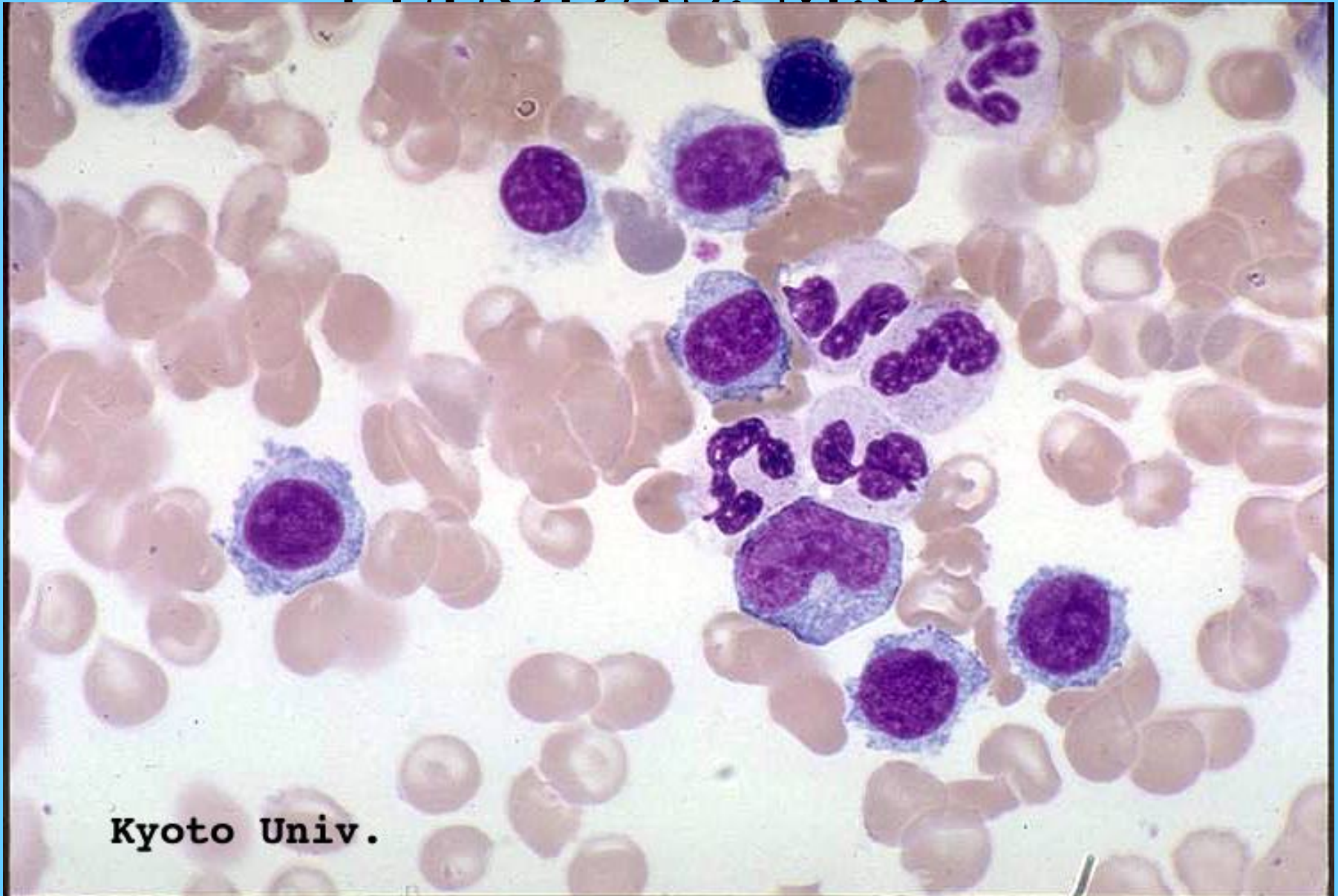
LEUCEMIA DE CÉLULAS T



LEUCEMIA DE CÉLULAS T

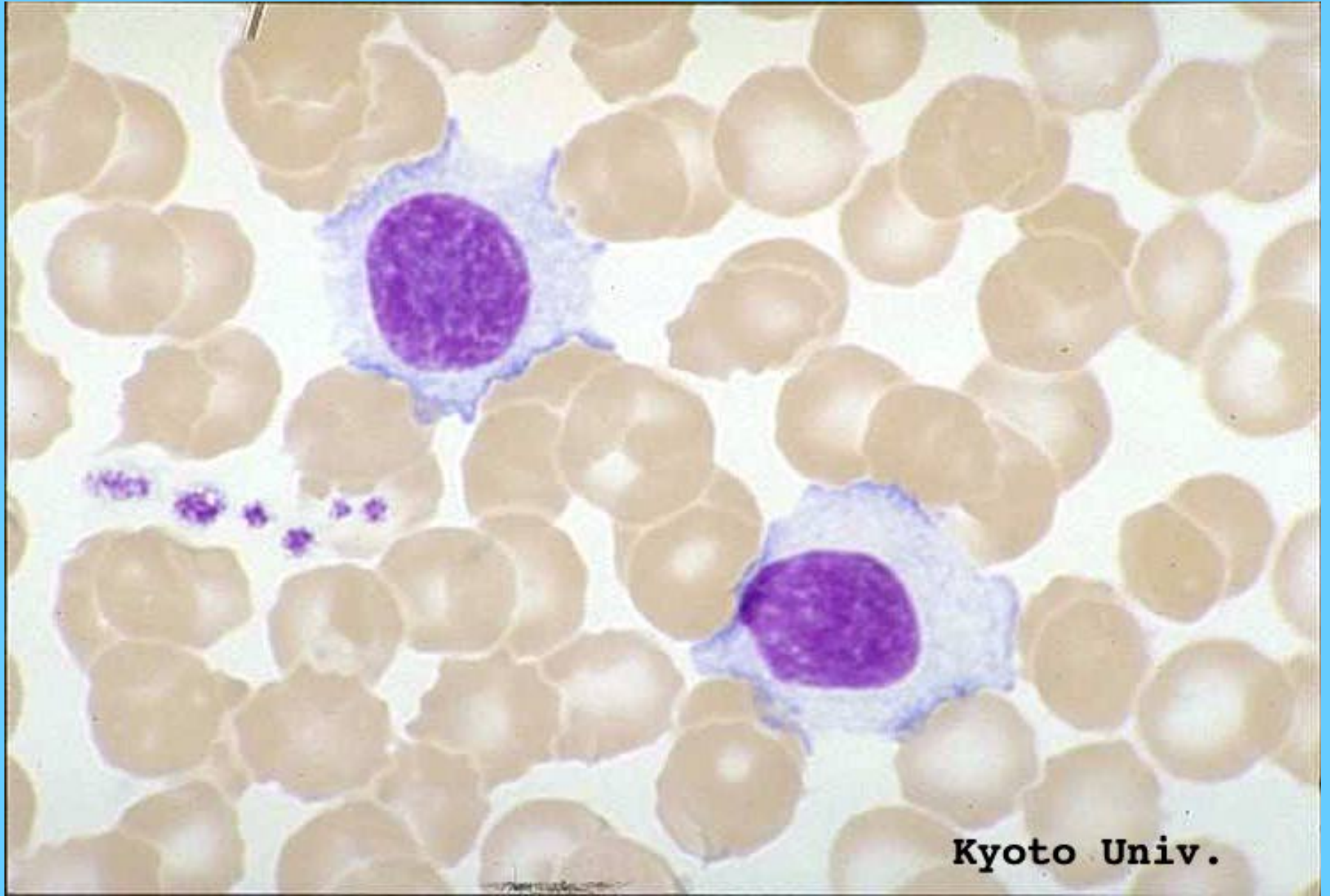


LEUCEMIA DE CÉLULAS PELUDAS. M.O.



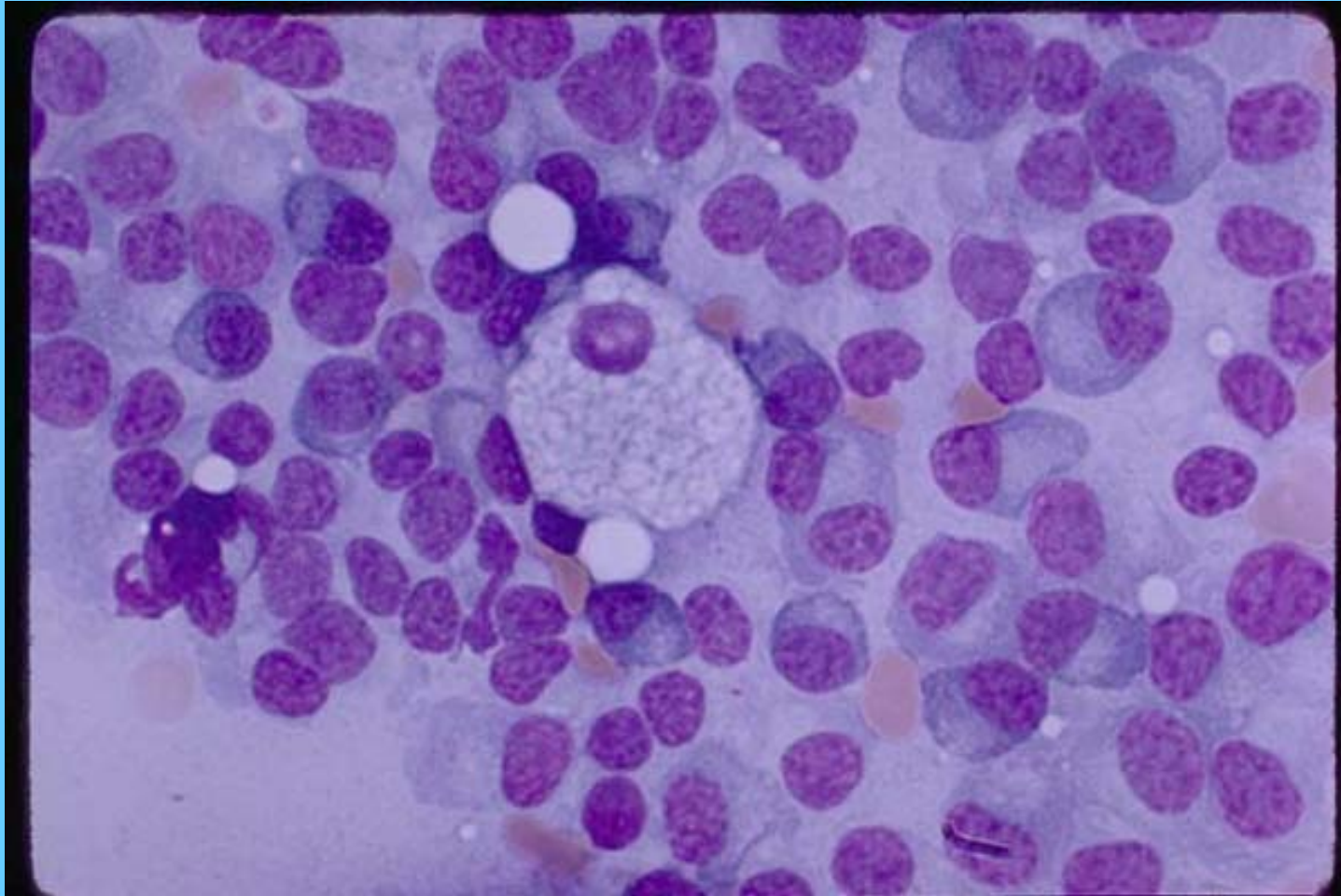
Kyoto Univ.

LEUCEMIA DE CÉLULAS PELUDAS, M.O.

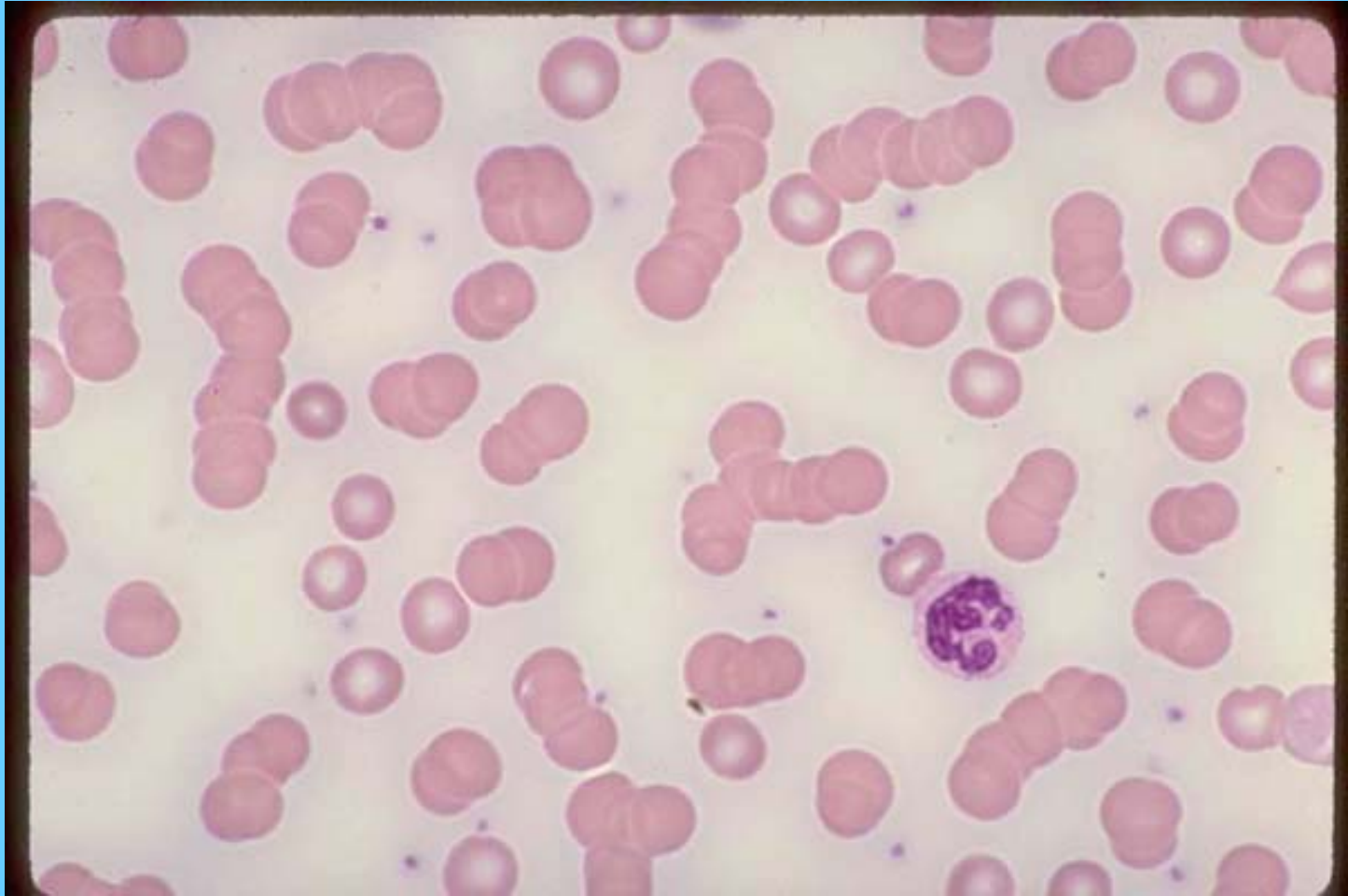


Kyoto Univ.

MIELOMA MÚLTIPLE, M.O.



ROULEAUX EN MIELOMA M



ROULEAUX Y CÉLULA PLASMÁTICA EN M.M.

