

The Female Prostate: The Newly Recognized Organ of the Female Genitourinary System

Biól. Alberto Rubio-Casillas, and Mtro. César Manuel Rodríguez-Quintero

Universidad de Guadalajara, Jalisco, México. 2009.

Abstract

The existence of the human female prostate had been a controversial topic in modern urological medicine, frequently ignored, or thought it was a vestigial organ, however, today this perception is antiquated; recent investigations recognize it as a functional gland capable of performing the same functions as the male prostate gland. In 1672, the Dutch anatomist Regnier de Graaf presented the first anatomical description of the female prostate. He was also the first to use this term. He described it as "a collection of functional glands and ducts surrounding the female urethra. Fortunately, the controversy has ended after more than 300 years, due largely to the substantial work that for over 25 years has made Dr. Milan Ziviacic. The Federative International Committee on Anatomical Terminology (FICAT) in its 2001 meeting in Orlando, Florida, USA, agreed to include the term female prostate in the next edition of Histological Terminology, prohibiting the use of terms *gland or para-urethral ducts*, and *Skene's gland* to appoint the prostate in women. In pathology, there are reported cases of female prostate cancer, which although very rare, indicate that the female prostate may also develop cancer and prostatic hyperplasia. This article tries to motivate gynecologists, urologists and uro-gynecologists to reevaluate the diagnostic criteria around diseases like the female urethral syndrome, because the evidence suggests it may actually be cases of prostatitis.

Antecedents

The existence of the human female prostate had been a controversial topic in modern urological medicine, frequently ignored, or thought it was a vestigial organ. Today this perception is antiquated, recent investigations recognize it as a functional gland capable of performing the same functions as the male prostate gland[1].

In 1672, the Dutch anatomist Regnier de Graaf presented the first anatomical description of the human female prostate and he was the first to use this term. He described it as "a collection of functional glands and ducts surrounding the female urethra. He was also the first to attempt to explain the role of the female prostate, writing " the function of the prostate is to generate a pituitouserous juice that make women more libidinous" and "the discharge by the female prostate causes as much pleasure as that obtained by the male prostate gland[2]".

The Scottish gynecologist Alexander J.C. Skene played a rather controversial role in the investigation of the female prostate. His work, published 200 years after De Graaf's work, described the female prostate as two para-urethral ducts that opened at the sides of the urethral opening, and exerted an inhibitory effect on further progress in the investigation of the female prostate [1].

"On the other hand, from the early years of our century, we can trace an opposite trend considering the female prostate referred to as Skene's para-urethral ducts and glands as an insignificant, rudimentary, vestigial female organ, which does not play any role in the life of the woman. The

vestigial concept of the female prostate has been based mainly on gross macroscopic differences between the sizes of the prostatic glands in the two genders. The difference in size, in disfavor of the female prostate, provided for many an implication that it would be unable to function or at least to function comparably to the male prostate” [1].

Influence of Sexual Hormones on the Female Prostate Morphogenesis and Physiology

During early embryological development, the basic pattern is feminine, that is to say, we are all females. This changes when the male embryo begins to produce its own hormones, around the eighth week of gestation. Only then the physical development of male and female bodies differs, though less than many assume. In order to form the male prostate, the woman must have a primary structure (urogenital sinus) from which, at the appropriate time, continue the development towards a structure such as the prostate.

Although the prostate tissue is androgen-dependent, physiology and pathology are also influenced by estrogens [3]. In addition to the critical role of androgens, it is well established that estrogen can alter prostatic growth, differentiation, and branching [4]. Although androgens are essential for initiating branching in the prostate and seminal vesicles, the suppression of androgens production after branching morphogenesis reduces the rate and extent of this process, but does not prevent the subsequent ramification [5]. Branching morphogenesis is a key feature of organogenesis for both organs. It allows for an increased epithelial surface area for seminal plasma secretion, and it provides a greater storage capacity for seminal plasma than is present in vertebrates that lack homologous glands [4].

Zaviacic’s first electron microscopic study [6] of the normal female prostate ultrastructure indicated that in the function of this gland and particularly in its secretory cells, estrogens may play an equally significant role as do androgens in the maturation and function of the male prostate. In the male prostate, immature stratified glandular epithelium differentiates during puberty into two principal cell types of the adult prostate glands; the secretory columnar epithelium and the basal cells. This differentiation process of the male prostate during puberty is obviously initiated by the beginning of testicular androgen secretion [7]. “Despite the fact that under normal conditions there is no androgenic stimulus either in puberty or throughout the life of a female, the epithelium of female prostatic glands in our material was clearly differentiated into mature secretory and basal cells. It seems to be justified to address the question whether only androgens are actually importantly involved in the process of differentiation and maturation of prostatic gland cells and whether estrogens may not be called into play in the differentiation of glandular cells of the female prostate, which is equipped with receptors for this hormone”[6]. Estrogen-receptor-associated protein (ER-D5) was found in the cytoplasm of cells lining female prostate glands [7].

Zaviacic et al [6] expressed their disagreement with the skeptical conclusions voiced in the study of Wernert et al [7] on the female prostate that, “These glands (glands of the female prostate) resemble strongly the male prostate glands before puberty glands (of the female prostate) remain immature throughout life (of the female) from the fetal period up to advanced ageNo indications can be found for a proper biological function ...” .

To the contrary, Zaviacic’s electron microscopic analysis of the normal female prostate showed that as in the male after puberty, in the adult female prostatic glands morphologically mature secretory and basal cells are formed. “There is no ground for believing that these cells would not play the same role in the pathophysiology of the female as in that of the male prostate” [6]. All these

findings allow us to understand why the female prostate does not disappear during embryological development, as previously thought. In our species, about 90% of women develop mature prostatic tissue that is active in secretory processes [8].

Structural and Functional Homology Between the Human Female Prostate and the Female Prostate of other Mammalian Species.

Together with the studies of the human female, it is recognized that well-developed prostates are present in females of at least four mammalian orders: *insectivora*, *chiroptera*, *rodentia* and *lagomorpha*, which exhibit a variable degree of development and produce prostatic secretions with unknown function [9, 10, 11, 12]. The experiments with human female prostatic tissue are very limited because the female prostate can only be obtained through necropsies of women who suffered cerebral death [6]. Hence, it is necessary to adopt experimental models that use a prostatic gland similar to the human female prostate in order to extrapolate the data to the human species [13]. Taboga et al [14] have adopted the Mongolian gerbil (*Meriones unguiculatus*) as an experimental model because the female prostate of this rodent has great homology with the human female prostate and the male gerbil ventral prostate. One example of this homology is the PSA expression in the secretory epithelium of the adult female prostate in this species (Fig.1) and in the human female prostate (Fig. 2).

The structural and functional similarity between the gerbil (*Meriones unguiculatus*) female and human female prostates suggests that this rodent is an excellent experimental model to investigate the functional aspects of the normal organ and installation of pathophysiological disorders [15, 16]. Thus, for instance, Pegorín de Campos et al [17] have observed that old male gerbils (12 months) may spontaneously develop benign prostate hyperplasia, cancer, and other prostate disorders.

Previous data have demonstrated that histological, histochemical and ultrastructural features of the adult gerbil prostate are comparable with those of the human prostate [15, 18, 19]. Although the female prostate in the gerbil remains small, it is clearly functional; the presence of a differentiated epithelium and secretory cells with high synthetic activity is a strong evidence of its maturity and functionality [15, 20, 21].

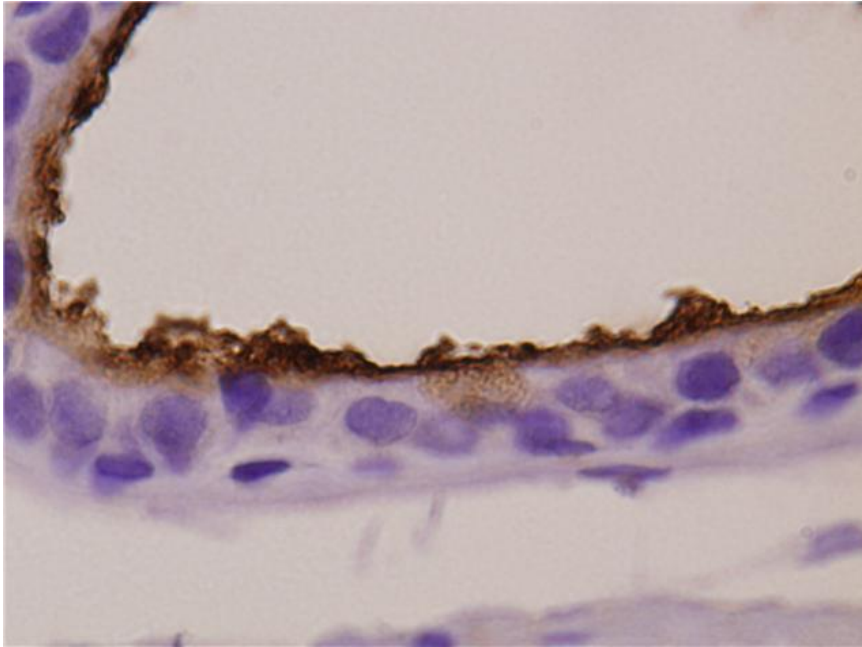


Figure 1. Prostate specific antigen (PSA) expression in apical portion of secretory epithelium in the female prostate of adult gerbil (*Meriones unguiculatus*). Courtesy of Dr. Sebastiao R.Taboga.

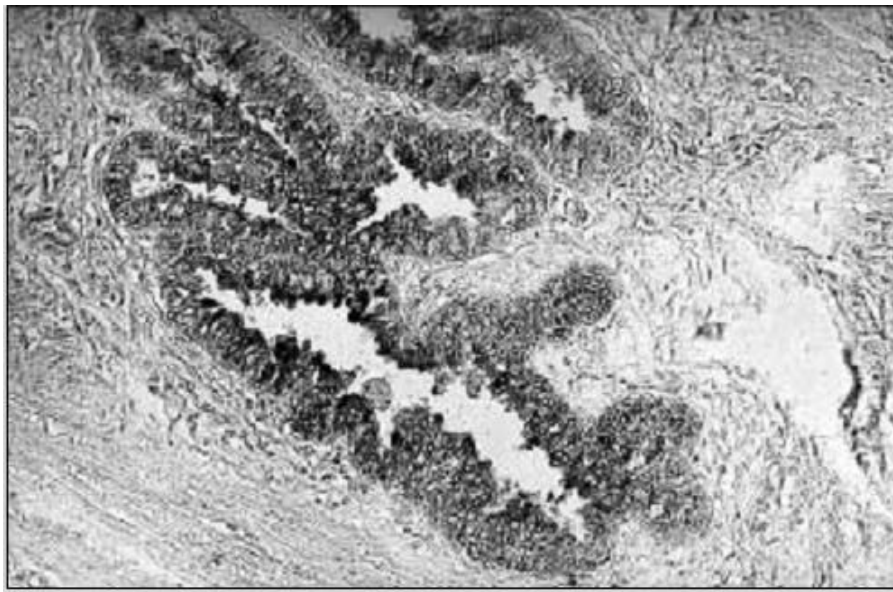


Figure 2: Expression of prostate-specific antigen (PSA) in the apical part of cytoplasm of the secretory cells and in membranes of female prostatic glands. 19 years-old female, biotin-streptavidin-peroxidase technique, x 180. From Zaviacic et al [1]

Official Recognition and International Agreements

The recognition of the existence of the human female prostate is due largely to the substantial work that for over 25 years has made Dr. Milan Zaviacic, a prominent forensic pathologist, at the Comenius Medical School, University of Bratislava, in the Slovak Republic. Based on research findings of Zaviacic and his collaborators, the Federative International Committee on Anatomical Terminology (FICAT) in its 2001 meeting in Orlando, Florida, USA, agreed to include the term female prostate in the next edition of *Histological Terminology*, prohibiting the use of terms *gland or para-urethral ducts*, and *Skene's gland* to appoint the prostate in women [1].

Thus, the latest edition (October 2008) of *Histological Terminology: International Terms for Cytology and Histology*, already includes the term female prostate (see table 1). At international level, this book provides the most current terminology for histology professionals, students, medical writers and editors, medical researchers, medical libraries, and related companies in the medical sciences.

H3.06.03.0.00009	Glandula paraurethralis; Prostata feminina ⁹²	Paraurethral gland; Female prostate
H3.06.03.0.00010	Tunica muscularis	Muscular layer; Muscular coat
H3.06.03.0.00011	M. sphincter urethrae externus	External urethral sphincter; Rhabdosphincter
H3.06.03.0.00012	(Ductus paraurethralis)	(Paraurethral duct)
H3.06.04.0.00001	Urethra masculina {vide paginam 78}	Male urethra {see page 78}

⁹² H3.06.03.0.00009 *Prostata feminina*: This term is introduced because of the morphological and immunological significance of the structure (Zaviacic M, Ablin RJ. The female prostate and prostate-specific antigen. Immunohistochemical localization, implications of this prostate marker in women and reasons for using the term *prostate* in the human female. *Histol Histopathol* 2000; 15: 131–142).

Table 1. Copy of the original document published by the FICAT on October 18, 2008, in which the term female prostate it was accepted. Courtesy of Dr. Colin Wendell-Smith, ex-secretary of the FICAT.

Location and Morphology

While the male prostate surrounds the urethra, the female prostate lies in the wall of the female urethra [8, 22, 23-25] (Fig.3). This is the main macroscopic difference between male and female prostate glands. The thickness of the wall and the length of the female urethra thus limit the size of the prostate, which for these reasons is smaller than the prostate in the male. However, despite the less space available for the female prostate, it possesses all the structural components characteristic of the male prostate [26, 27].

The female prostate possesses histologically the same structures as the prostate of the male, i.e. glands, ducts, and smooth musculature. The ducts are more numerous than the glands, and they exceed in number the ducts in the male prostate. The smooth musculature (musculofibrous tissue) is also more abundant in the female compared to the male prostate [8, 26, 27]. The prostatic (paraurethral) ducts do not open into the vulva on the sides of the meatus of the female urethra, they rather penetrate into the lumen of the urethra along its whole length [8, 22, 27], and it is

through the urethra and not through separate openings that the female prostate discharges its contents [8, 27].

The mean weight of the prostate of the adult female is 5.2 g and its size is 3.3 cm (length) x 1.9 cm (width) x 1.0 cm (height) [8] and represents roughly one quarter of the mean weight (23.7 g) of the adult male prostate [28,29,30].

Wimpissinger et al [31] studied seven women with Magnetic Resonance Imaging (MRI), and found that in these women, the female prostate volumes ranged from 2 to 4 cc.

Zaviacic [27] has established six anatomic models that are found in different sizes in all women (Table 2).

1	Anterior type (external urethral meatus)
2	Proximal type (bladder neck)
3	Glands along the whole length of the urethra
4	Rudimentary
5	Gland in the middle of the urethra
6	Dumbbell type

Table 2. Anatomic types of female prostate (adapted from Zaviacic, 1999).

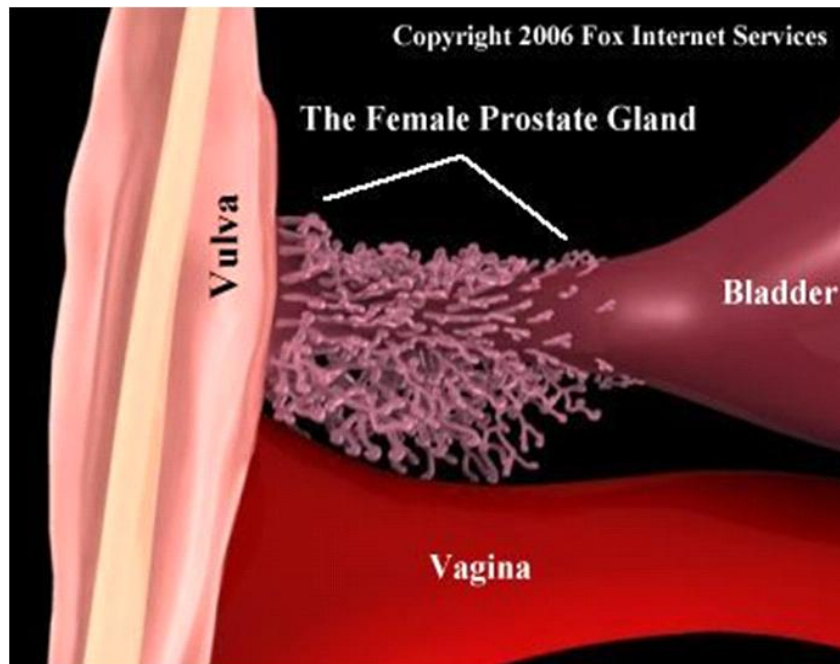


Figure 3. Location of the female prostate. This figure corresponds to the anatomic type no. 3, according with table 2 from Zaviacic, 1999. Courtesy of Mr. Brad Fox.

Despite its smaller size, the female prostate has at least two main functions [1]:

- Exocrine (production of prostate specific antigen(PSA), prostate specific acid phosphatase(PSAP), fructose, E-600 sensitive esterase and glucose-6-phosphatase)
- Neuroendocrine (serotonin production)

Ultrastructure of the Normal Adult Female Prostate

The exocrine function of the female prostate is reflected by its particular structure, including the presence of secretory (fig. 4) and basal cells with their characteristic ultrastructural appearance. Tall cylindrical secretory (luminal) cells are the predominant type both in female and male prostatic glands. Apical cytoplasm contains abundant secretory elements (secretory vacuoles and granules), rough endoplasmic reticulum, developed Golgi complexes and numerous mitochondria. These organelles characterize the active secretory configuration of female prostatic secretory cells with apocrine (apical blebs) and merocrine (secretory vacuoles and granules) types of secretion.

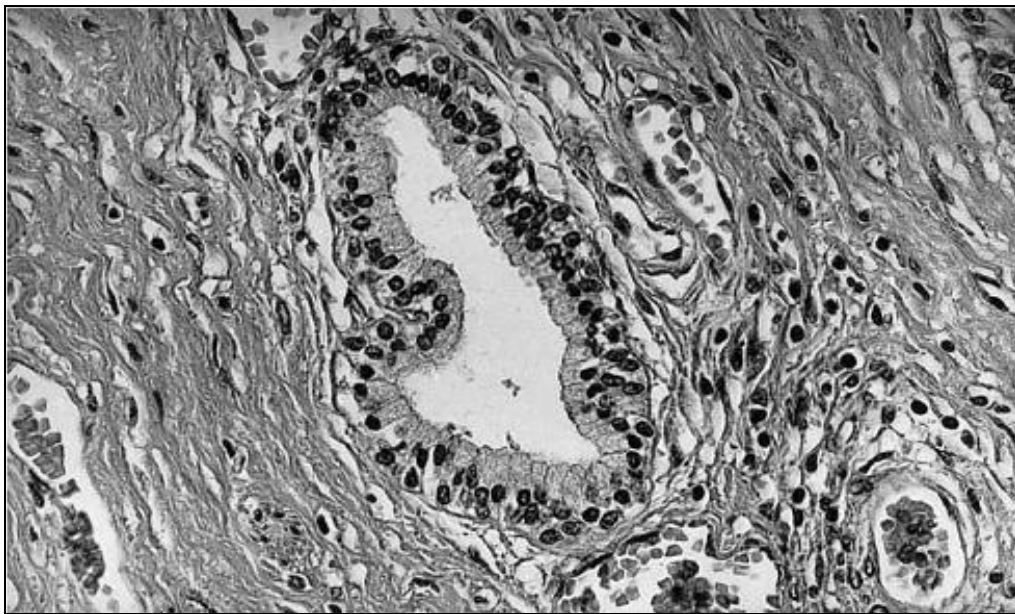


Figure 4. Solitary gland of the female prostate with luminally located secretory cells with dark nuclei. Below them basal (reserve) cells with less dark nuclei attached to the basement membrane. x360. (From Zaviacic et al [6].

Like in the male, also in the female prostate, especially in its luminally located secretory cells, lysosomal and prostatic specific acid phosphatase (PSAP) was determined histochemically using Gomori's, and Serano's methods [34].

Histochemical demonstration of E-600 sensitive esterase and glucose-6-phosphatase with further enzymes indicates secretory activity of female prostatic cells. These enzymes involved in proteosynthesis participate in the production of female prostatic fluid [34]. Concerning the spectrum of the enzymes determined, the enzyme equipment of the male and female prostate is comparable.

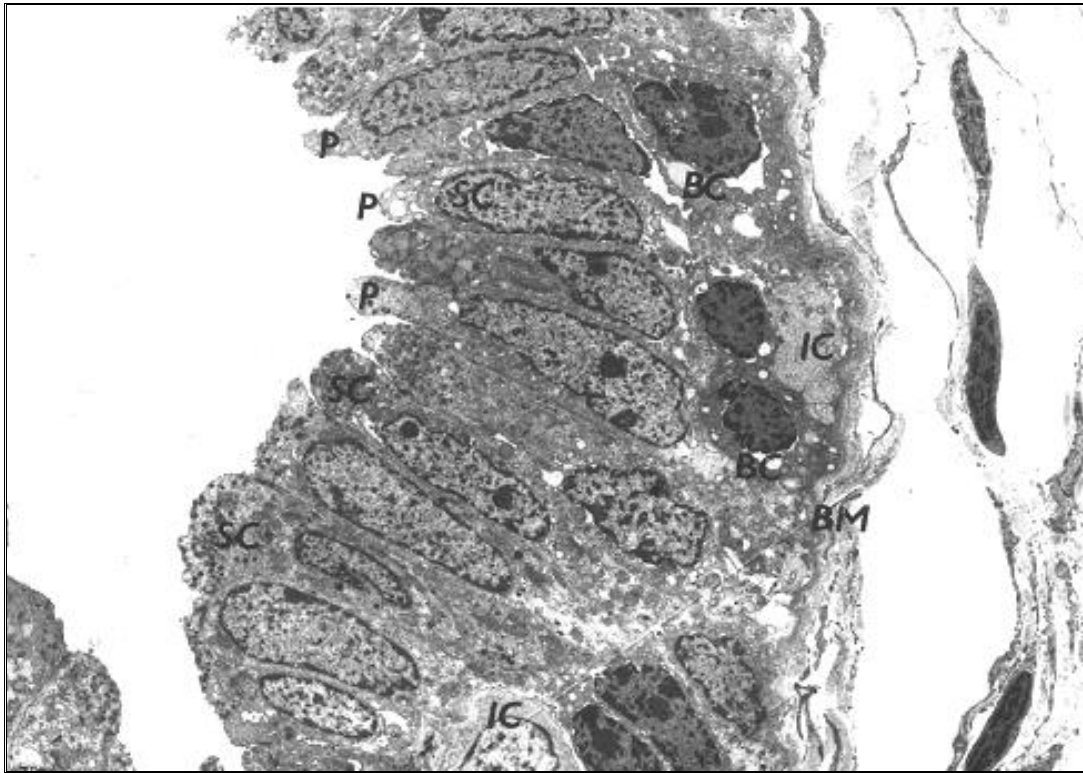


Fig. 5. Magnified overview of a normal gland of the female prostate. Basal cells (BC) rest on the basement membrane (BM). In the lower part a portion of an intermediary cell (IC). The lumen of the gland is lined with tall cylindrical secretory cells (SC) containing supranuclearly different numbers of polymorphous secretory elements (secretory vacuoles and secretory granules). Protuberances of the apical part (P) of the SC contain empty vacuoles. SC have nuclei with abundant dispersed chromatin and large nucleoli. Uranyl acetate and lead citrate (UALC), $\times 3,000$. From Zaviacic et al [6]

Prostate-specific antigen (PSA) is currently the most frequently used marker for identification of normal and pathologically altered prostatic tissue in the female [27, 35, 36, 37, 38]. Immunohistochemically, PSA is expressed in the highly specialized apically-superficial layer of female secretory cells (SC) (fig. 5) of the prostate as well as in uroepithelial cells at other sites of the female urogenital tract [27]. In clinical practice, PSA is a valuable marker in diagnosis and monitoring of diseases of the female prostate, particularly carcinoma. Besides other evidence, the non-vestigial concept of the human female prostate is at present based on the demonstration of similar antigenicity between the male prostate and the female prostate, as evidenced by PSA and prostate-specific acid phosphatase (PSAP) positivity.

Sexological Relevance

With regard to the sexological role, Zaviacic [39] states, "The organ is mainly significant in terms of sexual pleasure for women: the prostate tissue is a new erogenous zone for women. It participates in the phenomenon of female ejaculation, in which the female prostate is stimulated indirectly".

A historically broadly conceived overview on the female prostate and its function in the female ejaculation phenomenon, along with different attitudes on female ejaculation as observed in individual sex cultures, including those of ancient India and Japan, can be found in Stifter's work [40]. Since the 1920's the conventional medical establishment has dismissed "female ejaculation" as actually being a condition known as urinary stress incontinence. Women have generally considered such expulsions to be a source of personal shame or embarrassment that also frequently elicited disapproval from their sexual partners. Physicians usually attempt to correct the condition, either by the use of Kegel exercises or by surgery [41].

There are studies that have proved that pelvic muscles in female ejaculators are strong, not weak as in women with urinary incontinence [42]. The fact that the female ejaculate is not a form of orgasm-induced stress urinary incontinence or the result of increased vaginal lubrication is established among all authors involved in studying female sexual response [43,44,45,]. More recently, Cartwright et al [46] demonstrated that in women who report female ejaculation, there was no evidence of detrusor overactivity or associated lower urinary tract symptoms. Based on these evidences, Rubio-Casillas and Rodriguez-Quintero [47] have suggested that female ejaculation should be recognized as a part of women's normal sexual response, and instead of being considered a rare phenomenon, to be considered as an ignored capacity due to our cultural prejudices.

Health Relevance

The structural and functional homology between the male and female prostate has been widely demonstrated. So, it is logical to assume that the female prostate is also susceptible to the same diseases as the male prostate. The altered functioning of the female prostate could be more frequent than previously recognized. The authors suggest to gynecologists, urologists and urogynecologists to reevaluate the diagnostic criteria around diseases like the female urethral syndrome, because the evidence suggests it may actually be cases of prostatitis [48, 49].

Karram [33] pointed out that in contrast to the almost 2 million office visits annually in the United States for male prostatitis; in excess of 5 million office visits by women have been noted for the urethral syndrome, the commonest urologic complaint among female patients.

"Given the general misconception that the prostate gland is exclusively a male organ, the failure to recognize the existence of the female prostate and to investigate its pathology have resulted in the misdiagnosis and inappropriate treatment of female prostatitis." [50].

Gittes and Nakamura [48] conducted an extensive review, in which they concluded that "in most cases, it seems likely that clinicians have been overlooking specific infections of the female paraurethral gland and labeling such cases as the urethral syndrome. The most important aspect of recognizing the "female prostate" as an anatomic feature is that its infections may completely explain many cases of the urethral syndrome. It is time to alert primary care physicians to this

disorder and to eliminate the widespread practice of treating affected women with either invasive urethral dilation, or tranquilizers”.

Furthermore, there are reported cases of female prostate cancer [51, 52, 53], which although very rare, indicate that the female prostate may also develop cancer and prostatic hyperplasia [1]. Recently, Wimpissinger et al [31] presented the first magnetic resonance imaging (MRI) study of prostatic disease in seven women, thus extending our knowledge on this female gland.

Conclusion

In the last 300 hundred years, many health professionals have denied the existence of a functional prostatic gland in human females. Fortunately, with the official recognition by the FICAT in October 2008, the controversy about the existence of the female prostate has ended [54]. Dr. Milan Zaviacic has established the updated non-vestigial concept of the prostate in the female [1]. Based on multidisciplinary research, he has presented the female prostate as a functional genitourinary organ with a specific structure, function and pathology. He has shown that the female prostate parameters are similar or even identical with those of the adult male prostate. This recent concept has been based on morphological, histochemical, forensic-medical, sexological, gynecological, urological, chronobiological and pathology research.

The medical community should now focus on investigating other aspects of female prostate functions in the female sexual response, as would be the role of serotonin produced by this female gland, and the re-evaluation of the diagnostic criteria for diseases such cystitis or female urethral syndrome. It is also important to mention that pure human female prostatic fluid has not been yet isolated and it has been studied only as a component of the female ejaculate. There is also a need to characterize the normal female prostate anatomy through ultrasound, computed axial tomography and nuclear magnetic resonance imaging.

Finally, we insist on the use of the term female prostate, accepted by the FICAT. Even to date, the organ is named incorrectly by many doctors, gynecologists, and uro-gynecologists under the name of Skene's glands or para-urethral glands.

References

1. **Zaviacic, M., Zaviacic, T., Ablin, R.J., Breza, J., Holoman, J. (2001).** The human female prostate: history, functional morphology and sexology implications. *Sexologies*, Vol.XI, No.41.
2. **De Graaf, R. (1672).** De mulierum organis generationi inservientibus. Tractatus novus demonstrans tam homines et animalia caetera omnia, quae viviparadicuntur, haud minus quam vivipara ab ovo originem ducere.Leyden.
3. **García-Flórez M, Oliveira CA, Carvalho HF. 2005.** Early effects of estrogen on the rat ventral prostate. *Braz. J Med Biol. Res*, 38:487-497.
4. **Thompson, A.A., and Marker, P.C. (2006).** Branching morphogenesis in the prostate gland and seminal vesicles.
5. **Donjacour, A.A. and Cunha, G.R. (1988).** The effect of androgen deprivation on branching morphogenesis in the mouse prostate. *Dev. Biol.* 128:1–14.

6. **Zaviacic, M., Jakubovska, V., Belosovic, M., Breza, J. (2000).** Ultrastructure of the normal adult human female prostate gland (Skene's gland). *Anat. Embryol.* 201: 51-61.
7. **Wernert, N., Albrecht, M., Sesterhen, N I., Goebbels, R., Bonkhoffh. Seitz, G., Inniger, R., Remberger, K. (1992).** "The female prostate" : Location, morphology, immunohistochemical characteristics and significance. *Eur. Urol.* 22; 64-9.
8. **Zaviacic. T., Holoman, I.K., Breza. J. (2000).** Weight, size, macro- anatomy and detailed histology of the normal prostate in the adult human female: A minireview. *J. Histotechnol.* 23: 61-9.
9. **Longo, V.J., (1982).** The female prostate. *Urology* .20, 108–109.
10. **Shehata, R., (1974).** Urethral glands in the wall of the female urethra of rats, mice, and closely related rodents. *Acta Anat.* 90,381–387.
11. **Shehata, R., (1980).** Female prostate and urethral glands in the home rat, *Rattus norvegicus*. *Acta Anat.* 107, 286–288.
12. **Flamini, M.A., Barbeito, C.G., Gimeno, E.J., Portiansky, E.L., (2002).** Morphological characterization of the female prostate (Skene's gland or paraurethral gland) of *Lagostomus maximus maximus*. *Ann. Anat.* 184, 341–345.
13. **Santos, F.C.A., and Taboga, R.A.(2006).** Female prostate: a review about the biological repercussions of this gland in humans and rodents. *Anim. Reprod.*, v.3, n.1, p.3-18, Jan./Mar.
14. **Taboga, S.R., Góes, R.M., Zanetoni, C., Santos, F.C.A. (2001).** Ultrastructural characterization of the secretory cells in the prostate:a comparative study between the male and female organs.*Acta Microsc.*3(c),205–206.
15. **Santos, F.C.A, Carvalho, H.F, Goes, R.M, Taboga, S.R.(2003).**Structure,histochemistry and ultrastructure of the epithelium and stroma in the gerbil (*Meriones unguiculatus*)female prostate.*TissueCell.*35:447–457.
16. **Fochi, R. A., Ana P.S. Perez, Carlos V. Bianchi, Sabrina S. Rochel, Rejane, M, Goes, Patricia, S.L. Vilamaior, & R. Taboga, and Fernanda Santos.(2008).**Hormonal Oscillations During the Estrous Cycle Influence the Morphophysiology of the Gerbil (*Meriones unguiculatus*) Female Prostate (Skene Paraurethral Glands). *Biology of Reproduction.* 79, 000–000.
17. **Pegorin de Campos, S.P, Zanetoni, C., Góes, R.M, Taboga, S.R (2006).** Biological behavior of the gerbil ventral prostate during postnatal development.*AnatRec*288A:723–733.
18. **Custódio, A.M., Góes, R.M, and Taboga, S.R (2004).** Acid phosphatase activity in gerbil prostate: comparative study in male and female during postnatal development. *Cell Biol Int* .28:335–344.
19. **Santos, F.C.A., Luiz Roberto Falleiros-Júnio, Lara Silvia Corradi, Patricia Simone Leite Vilamaior & Sebastião Roberto Taboga. (2007).** Experimental endocrine therapies promote epithelial cytodifferentiation and ciliogenesis in the gerbil female prostate. *Cell Tissue Research (2007)*328:617–624.
20. **Santos. F.C.A, and Taboga, S.R.(2002).** Interacoes epitelio-estroma na próstata feminina: estudos experimentais em gerbilos. In:Bauer,M.E, Jeckel-Neto,E.A,editors.*Avancos em Biologia Celular d Sociedade Brasileira de Biologia Celular.* Rio Grande do Sul: Edipucrs. P.131.
21. **Santos, F.C.A, Corradi, L.S, and Taboga, S.R.(2001).** Cytochemical characterization of the stromal compartment in gerbil female prostate. *Acta Microscopica.* 3:207

22. **Huffman, J.W. (1948)** .The detailed anatomy of the paraurethral ducts in the adult human female. Amer. J. Obstet. Gynecol. 55; 86-101.
23. **Zaviacic, M., Brozman, M., Holoman, I.K., Zaviacicova, A., Oberucova, J. (1983)**.New information on the paraurethral (Skene's) ducts and glands in the female. Bratisl. Lek Listy. 79: 533-44 (in: Slovak, Summary in English).
24. **Wernert, N., Albrecht, M., Sesterhen, N I., Goebbels, R., Bonkhoffh. Seitz, G., Inniger, R., Remberger, K. (1992)**. "The female prostate": Location, morphology, immunohistochemical characteristics and significance.Eur. Urol. 22; 64-9.
25. **Wimpissinger, F., Stifter, K., Grin, W., and Stackl, W. (2007)**. The Female Prostate Revisited: Perineal Ultrasound and Biochemical Studies of Female Ejaculate. J Sex Med .4:1388–1393.
26. **Zaviacic, M. (1987)**. The female prostate: Nonvestigial organ of the female. A reappraisal. (Letter to the Editor). J. Sex Marit.Ther. 13; 148-52.
27. **Zaviacic, M. (1999)** .The Human Female Prostate. From Vestigial Skene's Paraurethral Glands and Ducts to Woman's Functional Prostate. Bratislava, SAP, 1sted. (le livre + CD).
28. **Thackray, A.C. (1978)**. The male reproductive organs. In: Symmers W.St.C. Systemic Pathology, 2nd ed. Vol. 4. Edinburgh,London, New York, Churchill Livingstone.
29. **Williams, P.L., Warwick, R. (1980)**.Gray's Anatomy. Edinburg, London, Melbourne, New York, Churchill Livingstone.
30. **Petersen, R.O. (1994)**. The urinary tract and male reproductive system. In:Rubine., Farber, J.L. Pathology, 2nd ed. Philadelphia, J.B. Lippincott.
31. **Wimpissinger, F., Tscherney, R., and Stackl, W. (2009)**. Magnetic Resonance Imaging of Female Prostate Pathology. J Sex Med 2009; 6:1704–1711.
32. **Santos, F.A.C., Rodrigo P. Leite, Ana M.G. Custodio, Karina P. Carvalho, Luiz H. Monteiro-Leal, Adriana B. Santos, Rejane M. Goes, Hernandes F.Carvalho, and Sebastiao R. Taboga.(2006)**. Testosterone Stimulates Growth and Secretory Activity of the Female Prostate in the Adult Gerbil (*Merionesunguiculatus*). Biology of reproduction 75, 370–379.
33. **Karram, M.M. (1990)**: The painful bladder: Urethral syndrome and interstitial cystitis. Curr Opin Obstet Gynecol 1990; 2:605-611.
34. **Zaviacic, M. (1984)**. Enzyme histochemistry of the adult human female prostate: acid phosphatase distribution. Cell. Molec. Biol.30; 545-61.
35. **Pollen, J.J.,and Dreilinger, A. (1984)**. Immunohistochemical identification of prostatic acid phosphatase and prostate specific antigen in female periurethral glands. Urology; 23: 303-04.
36. **Zaviacic, M., Ruzickova, M., Jakubovsky, J., Danihel, L., Babal, P., Blazekova, J. (1994)**. The meaning of prostatic markers in orthology of the female prostate.Bratisl. Lek. Listy; 95: 491-97 (in Slovak, Summary in English).
37. **Zaviacic, M., Ruzickova, M., Blazekova,J., Zaviacic, T., Itoh,Y.,Okutani, R., Kawai, T. (1997)**. Immuno-histochemical distribution of rabbit polyclonal antiurinary protein 1 antibody in the female (Skene's gland) and male prostate: new marker for neuroendocrine cells? Acta Histochem. 99: 267-75.

38. **Zaviacic, M., and Ablin, R.J. (2000).** The female prostate and prostate-specific antigen. Immunohistochemical localization, implications of this prostate marker in women and reasons for using the term "prostate" in the human female. Invited Review. *Histol. Histopathol.* 15:131-42.
39. **Zaviacic, M. (2001).** The human female prostate and its role in woman's life: sexology implications. *Scand. J. Sexol.* 4: 199-211.
40. **Stifter, K.F.(1988).** Die dritte Dimension der Lust. Das Geheimnis der weiblichen Ejakulation. Frankfurt am Main, Berlin: Ullstein; 224–8.
41. **Schubach G. (2002).** Urethral expulsions during sensual arousal and bladder catheterization in seven human females. *E J Hum Sex [online journal]*.
42. **Perry, J.D. and Whipple, B. (1981).** Pelvic muscle strength of female ejaculators: Evidence in support of a new theory of orgasm. *The journal of sex research.* Vol. 17, No.1, pp.22-39.
43. **Sevely, J.L, Bennett, J.W. (1978).** Concerning female ejaculation and the female prostate. *Journal of Sex Research.* Vol.14:1–20.
44. **Belzer, E.G. (1981).** Orgasmic expulsions of women: A review and heuristic inquiry. *Journal of Sex Research.*17:1–12.
45. **Addiego, F., Belzer, E.G., Commoli, J., Moger, W., Perry, J.D., Whipple, B. (1981).** Female ejaculation: A case study. *Journal of Sex Research.*1981; 17:13–21.
46. **Cartwright, R., Elvy, S., and Cardozo, L. (2007).** Do women with female ejaculation have detrusor overactivity? *Journal of Sexual Medicine.* 4:1655–1658.
47. **Rubio-Casillas, A., and Rodríguez-Quintero, C.M. (2009).** The female ejaculation: a new paradigm of the female sexual response? *News bulletin No.28, International Society for Sexual Medicine.*
48. **Gittes RF, Nakamura RM. (1996).** Female urethral syndrome-A female prostatitis? *West J Med;* 164:435-438).
49. **Gittes, R.F. (2002).** Female prostatitis. *Urologic Clinics of North America.* August, Vol. 29, Issue 3, pages 613-616.
50. **Zaviacic, M., and Ablin, R. (1999).** The female prostate, prostatitis, and recurrent urinary tract infection. *International Prostatitis Collaborative Network Meeting.*
51. **Ebisuno, S., Miyai, M., Nagareda, T., (1995).** Clear cell adenocarcinoma of the female urethra showing positive staining with antibodies to prostatic-specific antigen and prostatic acid phosphatase. *Urology.*Vol. 45, 682–685.
52. **Zaviacic, M., Ablin, R.J., Zaviacic, T., Kopani, M., Stvrtina, S., Holoman, K., and Breza, J. (2002).** Signet Ring Cell Carcinoma of Skene's Gland ("the Female Prostate*"): Histological and Electron microscopic Analysis of a Biopsy Case. *UroOncology,* Vol. 2(4), pp.199-204.
53. **Oliveira-Reis, A. Billis, F.T. Ferreira, L.Y. Ikari, R. F. Stellini, Ubirajara Ferreira. (2009).** Female urethral carcinoma: Evidences to origin from Skene's glands. *Urologic Oncology: Seminars and Original Investigations.*DOI.DOI10.1016/j.urolonc.2009.03.019
54. **Rubio-Casillas, A., and Rodríguez-Quintero, C.M. (2009).** The female prostate: the end of the controversy. *News bulletin No.30, International Society for Sexual Medicine.*

